

Percutaneous repair of acute ruptures tendon calcaneus by the Dresden technique: preliminary results

Reparo percutâneo das rupturas agudas do tendão calcâneo pela técnica de Dresden: resultados preliminares

Fernando Delmonte Moreira¹, Jorge Eduardo de Schoucair Jambeiro¹, Antero Tavares Cordeiro Neto¹, Valter Pereira Neto¹

ABSTRACT

Objective: To evaluate patients diagnosed with acute rupture of the Achilles tendon and who underwent surgery for percutaneous repair using the Dresden technique. **Methods:** This exploratory study included eight patients diagnosed with acute rupture of the Achilles tendon and who underwent surgery for percutaneous repair using the Dresden technique. All surgeries were performed by the same surgeon. We evaluated complication rates, return to daily activities, and functional results using a post-operative questionnaire. **Results:** The mean follow-up was 14.6 months. The mean American Orthopaedic Foot and Ankle Society (AOFAS) score observed after the surgery was 94. We did not observe sural nerve injury or re-rupture. One patient had a superficial wound infection. **Conclusion:** Repair of acute Achilles tendon ruptures using the Dresden technique showed low rates of complications and promoted excellent functional results in the evaluated group of patients. This approach constitutes a option for treatment of acute Achilles tendon injuries.

Keywords:

Achilles tendon; Minimally invasive surgical procedures

RESUMO

Objetivo: Avaliar pacientes com diagnóstico de ruptura aguda do tendão calcâneo submetidos ao procedimento cirúrgico de reparo percutâneo pela técnica de Dresden. **Métodos:** Pesquisa exploratória na qual foram avaliados oito pacientes com diagnóstico de ruptura aguda do tendão calcâneo submetidos ao procedimento cirúrgico de reparo percutâneo pela técnica de Dresden realizado sempre pelo mesmo cirurgião. Foram verificadas taxa de complicações, retorno a atividades habituais e resultados funcionais, por meio de questionários de avaliação pós-operatória. **Resultados:** O tempo médio de seguimento foi de 14,6 meses. A pontuação média da *American Orthopaedic Foot and Ankle Society* (AOFAS) no pós-operatório foi de 94 pontos. Não foram identificados casos de lesão do nervo sural ou rerruptura. Um paciente apresentou infecção superficial de ferida operatória. **Conclusão:** O reparo das rupturas agudas do tendão calcâneo com o uso do instrumento de Dresden apresentou baixas taxas de complicações e promoveu excelentes resultados funcionais no grupo avaliado, constituindo opção terapêutica para o tratamento das lesões agudas do tendão calcâneo.

Descritores:

Tendão calcâneo; Procedimentos cirúrgicos minimamente invasivos

¹ Hospital Santa Izabel, Salvador, BA, Brazil.

Correspondence to:
Fernando Delmonte Moreira
Hospital Santa Izabel
Praça Conselheiro Almeida Couto, 500, Nazaré
Zip Code: 40050-410 – Salvador, BA, Brazil
E-mail: fernandodelmonte@yahoo.com.br

Conflict of interest:
none reported.

Funding:
none reported.

Received on:
September 15, 2016

Accepted on:
November 3, 2016

INTRODUCTION

The Achilles (or calcaneal) tendon, formed by soleus and gastrocnemius muscle fibers, is the strongest and longest tendon in the human body. Acute tendon ruptures occur more frequently in men in their thirties and forties, and in individuals who engage in recreational sports activities, at incidence rates ranging from 1.7:1 to 30:1 in comparison to women.⁽¹⁾ It is the most commonly injured tendon of the lower extremity, with an average occurrence of 18 cases per 100,000 inhabitants.^(1,2)

The mechanisms of injury involved in are impulsion with the anterior part of the foot, sudden and unexpected ankle dorsiflexion, severe dorsiflexion of the foot in plantar flexion and direct blows to the contracted tendon or injury due to a laceration.⁽³⁾

There is no consensus in the literature on the best method of treatment for acute Achilles tendon injuries, whether conservative or surgical, and even on how to conduct each type of treatment. Several conservative treatment protocols and different surgical techniques have been described and are part of clinical practice.^(4,5)

Open surgical techniques, with exposure and direct repair of the tendon, have been shown to produce low re-rupture rates over time, but with important skin complications. This is related to open surgery in an area with scant subcutaneous cellular tissue and susceptible to higher suture dehiscence rates, infections and longer healing time. Therefore, minimally invasive percutaneous techniques have been developed and have gained space in the therapeutic arsenal of ankle and foot surgeons, as they attempt to mitigate the typical problems already faced in the postoperative follow-up of open surgery.^(6,7)

In 2006, the results of a technique developed to favor greater suture stability were published. This technique consisted of an anatomical apposition of the ends of the tendon and served to avoid damage to the sural nerve, because the suture threads were kept below the peritendon, and the incidence of tears was diminished. All these complications were frequently associated with other minimally invasive techniques.⁽⁷⁾ Subsequently, experiments with bovine tendons confirmed that suturing using the percutaneous technique was more resistant than traditional techniques.⁽⁸⁾

Percutaneous repair of acute injuries of the Achilles tendon is a surgical technique still rarely used in our field. This study aims to evaluate the preliminary results of patients after at least 6 months of postoperative follow-up, using post-surgical evaluation criteria that are firmly established

in the scientific field, and to identify possible complications related to the surgical method, such as neurological damage, re-ruptures and surgical site infection. Finally, it establishes a database that is useful to justify the use of the technique and its advantages over more invasive treatments already firmly established among foot and ankle surgeons.

OBJECTIVE

To assess patients diagnosed with an acute rupture of the Achilles tendon who have undergone a surgical procedure for percutaneous repair with the Dresden technique.

METHODS

This is an exploratory study, which used data collected from a group of patients operated by the same surgeon, a member of a Foot and Ankle Surgery Group of Hospital Izabel, Salvador, Bahia. They had sustained an acute Achilles tendon injury diagnosed through their medical history and a physical examination, and had undergone the percutaneous repair using the Dresden technique, between June 7, 2014 and August 22, 2015.

Patients of both sexes with acute tendon ruptures occurring less than 10 days previously underwent surgery. Injury diagnosis was clinical and performed through medical history and physical examination, without the use of additional tests. All patients underwent the same surgical treatment. The exclusion criteria were re-ruptures and open injuries of the Achilles tendon.

Patients operated on during the period and who met the proposed criteria were informed of the purpose of the study and, after signing the Informed Consent Form, were included in the analysis. A research instrument was used with demographic and surgical data, as well as information on complications related to the percutaneous techniques: sural nerve injury, re-rupture and surgical site infection, assessed by outpatient follow-up. The clinical evaluation was carried out in February 2016 through a medical evaluation, physical examination, and use of the Ankle Hindfoot Scale of the American Orthopaedic Foot and Ankle Society (AOFAS), translated into and validated for the Portuguese language,⁽⁹⁾ anthropometric measures of calf diameter, articular range of motion and strength. The data were organized in descriptive and frequency distribution tables.

This study was approved by the Institutional Review Board of Hospital Santa Izabel da Santa Casa de Misericórdia da Bahia (Opinion 1,373,742).

Surgical technique

The patient was positioned in ventral decubitus under locoregional or local anesthesia without tourniquet. The two limbs were supposed to be under the surgical drapes, to allow comparative adjustment with the normal contralateral side of the suture tension. An incision approximately 2cm long was made medial to the posterior midline of the leg and 3cm from the proximal stump of the tendon (Figures 1 and 2). A virtual space was created, by means of

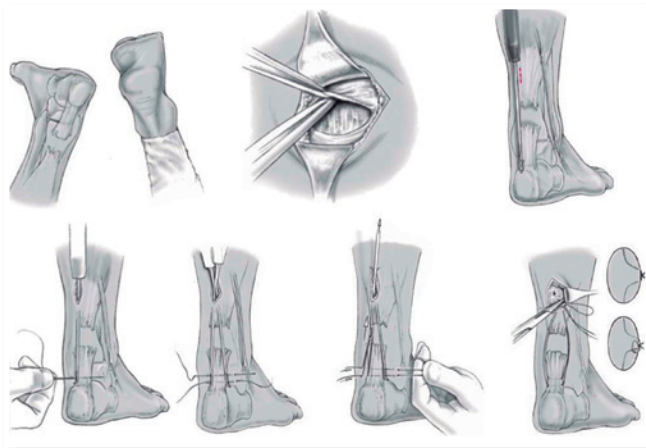


Figure 1 | Surgical technique for percutaneous repair of the Achilles tendon with the Dresden technique. Source: illustration adapted and kindly provided by Dr. Michael Amlang.

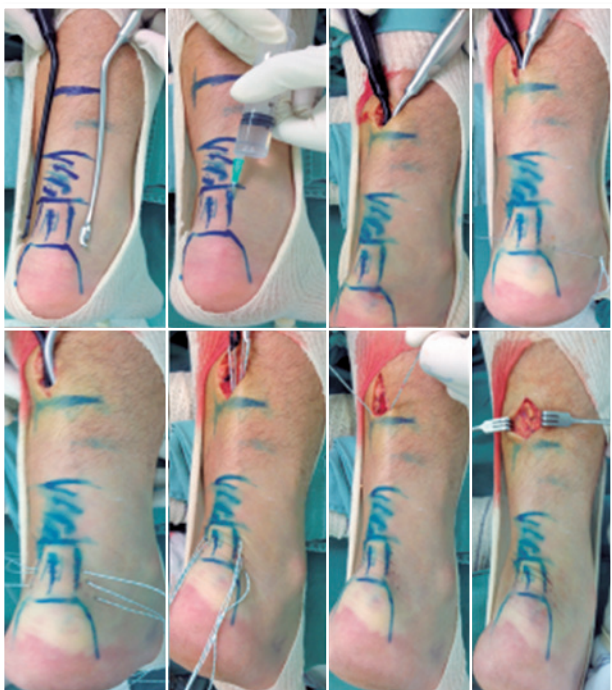

Figure 2 | Surgical technique for percutaneous repair of the Achilles tendon with the Dresden technique.

dissection, between the posterior superficial fascia and the paratendon, ensuring that the sutures to be made would remain within the sheath and would not cause damage to the sural nerve, which is subcutaneous. The Dresden instrument (Figure 3) was introduced tangentially to the Achilles tendon along its medial border up to 1cm from the calcaneal tuberosity.

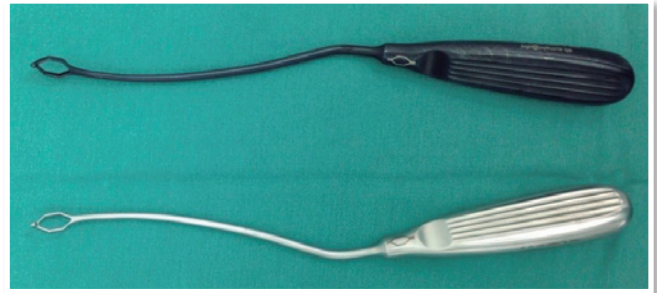


Figure 3 | Dresden Instrument.

A straight needle with ultra-high molecular weight polyethylene suture thread was inserted 1cm proximal to the posterior calcaneal tuberosity, traversing the skin, the subcutaneous tissue and the orifice of the Dresden instrument and partially traversing the Achilles tendon (Figures 1 and 2). A second Dresden instrument was introduced tangent to the lateral border of the tendon and brought to the same level as the first. The needle then traversed the calcaneal tendon and passed through the orifice of the second instrument and skin.

A second straight needle was inserted 1cm proximal to the first, using the same technique described above. With the surgeon holding the suture threads firmly on one side, the contralateral instrument was removed. The externalized threads were then secured, and the second instrument was removed, allowing the threads to be completely exposed through the surgical incision.

To confirm that the threads were correctly positioned and firm, they were pulled separately until total plantar flexion was achieved; if they were not completely firm and correctly positioned, they were repositioned. The proximal stump was sutured using a curved needle in the proximal musculature. The foot was to be kept in the physiological plantarflexed position for suturing. Tension was checked for adequacy by comparing it with the contralateral side.

In cases of distal injuries, the instrument was moved forward up to the calcaneus, and the sutures were through the calcaneus after drilling with a 2.5mm bit.

The modified Dresden technique (Figure 3), using a third 1cm suture thread proximal to the second suture, was

used in all the cases operated on in this study as it has shown a higher level of tension and resistance in studies with bovine tendons.⁽⁸⁾

In the postoperative protocol, the patient was fitted with a removable brace with 20° plantar flexion, equivalent to a 3cm elevation of the heel, for 6 weeks, with immediate full weight bearing and early physiotherapy. From the sixth to the eighth week, the heel elevation was 1cm; from the eighth week, the patients started to use a normal shoe with the same elevation.

Non-impact sports activities, such as cycling, swimming and bodybuilding, were allowed from the eighth week; running was allowed on the twelfth week; and resumption of full activity commenced 6 months after the procedure.

RESULTS

Eight patients aged between 29 and 71 years with an average age of 48 years were operated on in the period (Table 1). In the sample group, 75% were male and the most frequently affected side was the right side (six cases) (Table 2). Mean time between injury and surgery was 5.7 days and the AOFAS score assessed in the postoperative

period ranged from 72 to 100 points with an average of 94 points. Mean time between surgery and the postoperative evaluation (ΔT) in February 2016 was 14.6 months (Table 1). All patients underwent the same postoperative rehabilitation protocol: immediate full weight bearing and gradual return to activities within 2 weeks.

The difference between the circumferences of the legs was compared between the operated and healthy sides with standardized measurements taken 15cm below the knee, and values ranging from 0 to 1cm, with an average of 0.54cm.

Regarding range of motion, none of the patients had a reduction greater than 5° within the range of motion (plantar flexion and dorsiflexion).

Among the clinical complications evaluated, only one patient presented with superficial surgical wound infection, which was treated with first-generation oral cephalosporin, with no need for further surgery. This patient was the only one with a confirmed diagnosis of diabetes. There were no cases of sural nerve damage or re-rupture.

DISCUSSION

Despite several published studies, there is no consensus on the best surgical strategy to be adopted for the repair of Achilles tendon injuries. Since the publication of the study by Ma and Griffith,⁽¹⁰⁾ percutaneous techniques have gained impetus, mainly due to the lower rates of skin complications with equivalent functional results.^(11,12) However, some authors have started to report a greater risk of sural nerve damage, which prompted the development of new techniques and even the recommendation of nerve exploration during tendon repair.^(13,14)

In this study, the time elapsed between the injury and the date of surgery was on average less than 10 days, i.e., it is an ideal period, which justifies the use of the technique employed and allows favorable surgical results. This would not be possible within a longer period, due to tendon degeneration, further shortening, and thus retraction of the tendon stumps.

Regarding the evaluation using the AOFAS criteria, most patients were within the standard deviation of the mean of 94 points; hence, it can also be considered a favorable outcome. The only case outside the standard deviation of the established mean was a 49-year-old female patient with the influence of a previous history of tendinopathy of the fibular tendons. This fact leads us to reflect on whether a previous history of degenerative or inflammatory pathologies of the ankle may have a negative bias in the surgical

Table 1 | General characteristics of patients undergoing percutaneous repair of the Achilles tendon using the Dresden technique

Patient	Age	Sex	Side	ΔT injury/ surgery (days)	AOFAS	ΔT surgery/ postoperative evaluation (months)
1	30	M	D	3	90	20
2	58	M	D	10	100	20
3	51	F	E	3	98	19
4	36	M	D	5	100	17
5	62	M	E	8	98	17
6	49	F	D	10	72	7
7	29	M	D	2	100	6
8	71	M	D	5	100	11

ΔT injury/surgery: average time between injury and surgery; AOFAS: American Orthopaedic Foot and Ankle Society; ΔT surgery/postoperative evaluation: average time between surgery and postoperative evaluation; M: male; R: right side; F: female; L: left side.

Table 2 | Sex and laterality of patients undergoing percutaneous repair of the Achilles tendon using the Dresden technique

Characteristics	n (%)
Sex	
Male	6 (75.0)
Female	2 (25.0)
Laterality	
Right	6 (75.0)
Left	2 (25.0)

results of the technique and, therefore, become an exclusion factor.

Among athletes who have undergone surgical repair of the Achilles tendon, there is a higher risk of re-rupture among youths (under 30 years of age), especially between the seventh and tenth postoperative weeks.⁽¹⁵⁾ None of the patients in the sample evaluated were professional athletes, but engaged in recreational physical activities, and all patients resumed physical activities. There were no cases of re-rupture or of deficits in muscle strength in the period evaluated.

There was no reduction in the range of motion greater than 5° in any of the operated patients, who represented a small sample, with results superior to the traditional technique.

Since the first publication of the Dresden technique,⁽⁷⁾ results have shown absence of sural nerve injury and low rates of skin complications with excellent functional results. In our series, the results showed that the procedure is highly reproducible and has a short learning curve, since the results are similar to those presented by the team that developed the technique.

CONCLUSION

The repair of acute ruptures of the Achilles tendon using the Dresden instrument in the group of patients evaluated in this study had low rates of complications and promoted excellent functional results, thus representing a therapeutic option for the treatment of acute injuries of the Achilles tendon.

REFERENCES

- Hattrup SJ, Johnson KA. A review of ruptures of the Achilles tendon. *Foot Ankle*. 1985;6(1):34-8.
- Pedowitz D, Kirwan G. Achilles tendon rupture. *Curr Rev Musculoskelet Med*. 2013;6(4):285-93.
- Maffulli N. Current concepts review - rupture of the achilles tendo. *J Bone Joint Surg Am*. 1999;81(3):1019-36.
- Barfod KW, Bencke J, Lauridsen HB, Ban I, Ebskov L, Troelsen A. Nonoperative dynamic treatment of acute achilles tendon rupture: the influence of earlyweight-bearing on clinical outcome a blinded, randomized controlled trial. *J Bone Joint Surg Am*. 2014;96(18):1497-503.
- Cetti R, Christensen SE, Ejsted R, Jensen NM, Jorgensen U. Operative versus nonoperative treatment of Achilles tendon rupture. A prospective randomized study and review of the literature. *Am J Sports Med*. 1993;21(6):791-9.
- Willits K, Amendola A, Bryant D, Mohtadi NG, Giffin JR, Fowler P, et al. Operative versus nonoperative treatment of acute Achilles tendon ruptures: a multicenter randomized trial using accelerated functional rehabilitation. *J Bone Joint Surg Am*. 2010;92(17):2767-75.
- Amlang MH, Christiani P, Heinz B, Zwipp H. The percutaneous suture of the Achilles tendon with the dresden instrument. *Oper Orthop Traumatol*. 2006;18(4):287-99.
- Ortiz C, Wagner E, Mocoçain P, Labarca G, Keller A, Del Buono A, et al. Biomechanical comparison of four methods of repair of the Achilles tendon. *J Bone Joint Surg Br*. 2012;94(5):663-7.
- Rodrigues RC, Masiero D, Mizusaki JM, Imoto AM, Peccin MS, Cohen M. Translation, cultural adaptation and validity of the American Orthopaedic Foot and Ankle Society (AOFAS) Ankle-Hindfoot Scale. *Acta Ortop Bras*. 2008;16(2):107-11.
- Ma GW, Griffith TG. Percutaneous repair of acute closed ruptured Achilles tendon : a new technique. *Clin Orthop Relat Res*. 1977;(128):247-55.
- Lim JI, Dalal R, Waseem M. Percutaneous vs. open repair of the ruptured Achilles tendo a prospective randomized controlled study. *Foot Ankle Int*. 2001;22(7):559-68.
- Khan RJK, Fick D, Keogh A, Crawford J, Brammar T, Parker M. Treatment of acute achilles tendon ruptures: a meta-analysis of randomized, controlled trials. *J Bone Joint Surg Am*. 2005;87(10):2202-10.
- Majewski M, Rohrbach M, Czaja S, Ochsner P. Avoiding sural nerve injuries during percutaneous Achilles tendon repair. *Sports Med*. 2006;34(5):793-8.
- Haje DP, Haje SA, Porto AO, Silva CFV. Sutura Percutânea do tendão calcâneo pela técnica de Ma e Griffith modificada: avaliação dos resultados. *Rev Bras Ortop*. 2005;40(4):162-74
- Rettig ACI, Liotta FJ, Klootwyk TE, Porter DA, Mielsing P. Potential risk of rerupture in primary achilles tendon repair in athletes younger than 30 years of age. *Am J Sports Med*. 2005;33(1):119-23.