

Chronic compartment syndrome of the legs: case report

Síndrome compartimental crônica nas pernas: relato de caso

Otaviano de Oliveira Jr.¹, Fabrício Melo Bertolini¹, Rodrigo Pace Lasmar², Rodrigo Barreiros Vieira²,
Philippe Melgaço Mendes¹, Mateus Martins Marcatti¹

ABSTRACT

Chronic exertional compartment syndrome (CECS) results from increased intracompartmental pressure in addition to osteofascial boundaries of these compartment. We included three patients diagnosed with chronic exertional compartment syndrome and exclusion by imaging test. Patients were underwent fasciotomy of the anterior and lateral compartment of legs. The patients returned to physical daily activity with improvement of the pain symptoms. The CECS has limitations as the main diagnostic method. There is the need of further studies that standardize the technique and the diagnostic criteria of blood-pressure measurement, and also actions to spread knowledge among medical specialties.

Keywords:

Compartment syndromes; Athletes; Leg; Pain/etiology; Pain/diagnosis; Fascia/surgery; Case reports

INTRODUCTION

Described by Mavor in 1956, chronic compartment syndrome (CCS) results from an increase in intracompartmental muscle pressure beyond the osteofascial limits of that compartment.⁽¹⁾

The exact prevalence is unknown, but may be the cause of 27% to 34% of cases of exercise-induced leg pain.⁽²⁾ The

RESUMO

A síndrome compartimental crônica resulta de um aumento da pressão intracompartmental muscular além dos limites osteofasciais daquele compartimento. Foram incluídos três pacientes diagnosticados com síndrome compartimental crônica nas pernas por diagnóstico clínico e exclusão por meio de exames de imagem. Tratados cirurgicamente com fasciotomia dos compartimentos anterior e lateral das pernas, os pacientes retornaram à prática de atividade física com melhora dos sintomas algícos. A síndrome compartimental crônica ainda apresenta limitações quanto ao principal método diagnóstico. É importante que sejam realizados estudos que padronizem a técnica e os critérios diagnósticos de medida das pressões, além de difundir o conhecimento entre especialidades médicas.

Descritores:

Síndromes compartimentais; Atletas; Pernas; Dor/etilogia; Dor/diagnóstico; Fásia/cirurgia; Relatos de casos

most commonly affected compartments are the anterior and lateral compartments, accounting for up to 95% of all CCS cases. It occurs equally in men and women. It mainly affects young athletes or the physically active, and is bilateral in more than 60% of cases.⁽³⁾

The physiopathology has not been fully clarified, but is believed to be multifactorial. The factors that contribute

¹ Grupo de Cirurgia do Pé e Tornozelo, Medicina Esportiva, Hospital Universitário Ciências Médicas, Belo Horizonte, MG, Brazil.

² Grupo de Medicina Esportiva, Faculdade de Ciências Médicas de Minas Gerais, Belo Horizonte, MG, Brazil.

Correspondence to:
Otaviano de Oliveira Jr.
Rua Curitiba, 2.258/1.002 – Lourdes
Zip Code: 30170-122 – Belo Horizonte, MG, Brazil
E-mail: ooliveirajr@hotmail.com

Conflict of interest:
none reported.

Funding:
none reported.

Received on:
September 19, 2016

Accepted on:
November 07, 2016

to CCS are: muscle hypertrophy, fascia thickness or rigidity, stimulation of fascial stretch receptors, diminished venous return, microtrauma injuries of the muscles and myopathies.⁽⁴⁾

Diagnosis is based on clinical history and the gold standard requires invasive and direct measures of pressure in the affected muscle compartment. The criteria currently used most often to diagnose CCS in the literature were proposed by Pedowitz et al.^(2,5,6) According to these criteria, CCS in the leg is present if one or more of the following intracompartmental pressure measurement criteria are found: pre-exercise pressure ≥ 15 mmHg; pressure after 1 minute of exercise ≥ 30 mmHg, and pressure after 5 minutes of exercise ≥ 20 mmHg.

The differential diagnosis should be made with intermittent claudication caused by popliteal artery entrapment, atherosclerosis or arteritis, myositis, tendonitis, periostitis, stress fractures of the tibia and fibula and tumors.⁽⁷⁾

Treatment should be focused on controlling symptoms and on the patient's return to physical activity.⁽⁵⁾ Conservative measures may be attempted, but fasciotomy is the procedure of choice for definitive treatment. Studies have shown lower rates of complications and early return to sports associated with surgical treatment using bilateral fasciotomy.⁽³⁾

There are not yet any standard kits on sale in Brazil to measure intracompartmental pressure. There are adaptations that may help to obtain the diagnosis.

The aim of this study is to describe clinical cases and diagnosis, and to demonstrate the results obtained from patients with CCS.

CLINICAL CASES

Case 1

A 20-year-old male patient, an amateur soccer player with no underlying diseases, referred for specialized evaluation of chronic pain in the legs, more intense on the right, which started approximately 3 years ago and has progressively worsened. The patient reports pain while playing sports (running), discomfort and swelling, and denies paresthesia. Hypertrophic and hypertonic lower limb muscles, preserved peripheral pulse and perfusion, referred pain in anterolateral compartments of the legs (worse on the right), presence of muscle hernia in the posterior region of the leg, and neutral/supinated footfall were found during physical examination. Diagnostic hypothesis of chronic exertional compartment syndrome (CECS) of the lower limbs.

Magnetic resonance imaging (MRI) of the legs was requested, with images collected at rest and after 5 minutes of physical exercise (climbing and descending stairs). Signs of exertional compression were observed in the anterior and lateral compartments of the right leg. Arterial and venous Doppler ultrasound of lower limbs showing signs of extrinsic compression of the popliteal artery by the gastrocnemius muscle during bilateral maximum plantar flexion maneuver. An assessment was requested from the vascular surgery team, which reported that the compression detected during the test did not characterize the patient-reported pain (previously referred) in the anterolateral region of the leg, and was a finding without clinical significance. The patient underwent videoendoscopy-assisted fasciotomy of the anterior and lateral compartments of the legs. He was discharged with partial weight bearing on the second postoperative day (POD). He returned 15 days later for removal of stitches and was referred for physiotherapy rehabilitation without complaints of pain. He was cleared to play sports on the 35th POD. He started participating in soccer competitions again 90 days after the surgical procedure.

Case 2

A 20-year-old male patient, a professional soccer player, victim of low-intensity injury to the lateral surface of the right leg during a training session. He continued to experience pain 1 week later and underwent radiography, which showed a non-displaced fibular shaft fracture. The patient received conservative treatment with load removal, with training progressively increased following radiographic bone healing at approximately 8 weeks (Figure 1). He continued to complain of pain, fatigue and a burning sensation in the anterolateral region of the right leg, with worsening of symptoms related to increased weight bearing during training sessions and games, associated with a decline in performance. An MRI scan of the leg showed a healed fibula fracture and a posteromedial tibial cortex stress fracture while bone scintigraphy showed a grade III/IV tibial shaft stress fracture. Conservative treatment was provided for 10 weeks (physical therapy), but the patient continued to complain of burning pain in the right leg after attempting to return to sports. Surgical treatment of the tibial stress fracture with interlocking intramedullary nail fixation was indicated. The athlete requested a second orthopedic opinion. Upon physical examination, he presented with pain and paresthesia in the distal and mid-third of the anterolateral surface of the right leg (Figure 2), worse after a few minutes of running stimulus, but without pain on palpation of the tibial shaft and with complete improve-

ment of symptoms after discontinuing exercise. He appeared incapable of high output while playing. In view of the CCS hypothesis, a reassessment with radiographic tests was requested and showed a bone callus in a previous fracture of the fibular shaft. The patient also underwent MRI at rest and after exertion, which no longer showed abnor-

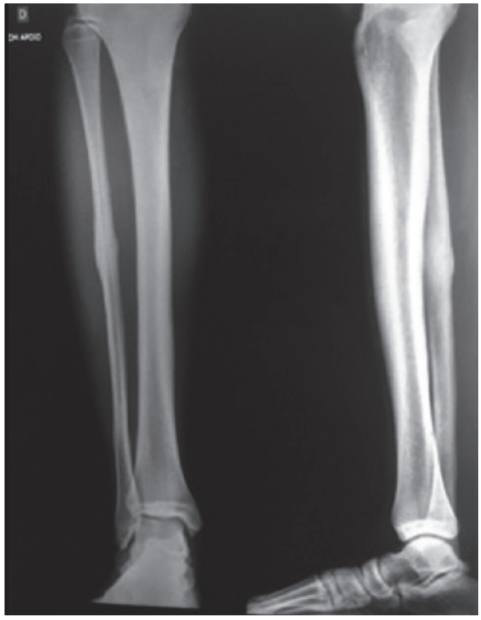

Figure 1 | Radiograph with healing of the fibula bone.

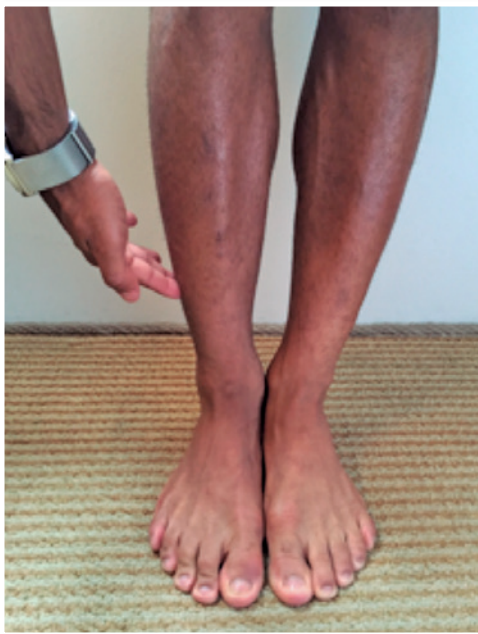

Figure 2 | Pain on the anterolateral surface of the leg.

malities of the tibial shaft, so the possibility of stress fracture suggested by the previous MRI was ruled out. Arterial and venous Doppler tests of the lower limbs and clinical evaluation by the vascular surgery team showed no abnormalities. Electroneuromyography (ENMG) compatible with posttraumatic inflammation of the superficial fibular nerve, without motor neuron lesion. Diagnosis of CCS of the right leg secondary to increased content of the anterior and lateral compartments of the leg due to the post-fibular fracture bone callus, associated with posttraumatic inflammation of the superficial fibular nerve. The decision was made to undertake a videoendoscopy-assisted fasciotomy of the anterior and lateral compartments of the legs in addition to open neurolysis of the superficial fibular nerve (Figure 3). Partial weight bearing was authorized on the second POD (Figure 4). The patient started functional physiotherapy

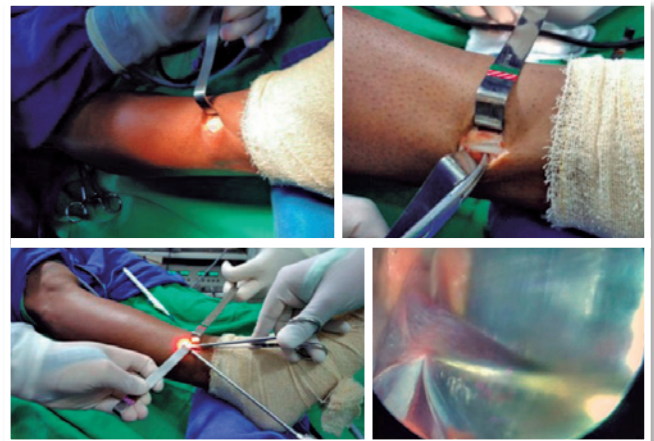


Figure 3 | Distal approach; superficial fibular nerve; videoendoscopy-assisted fasciotomy of the anterolateral compartment; visualization of the fasciotomy on the visual display.

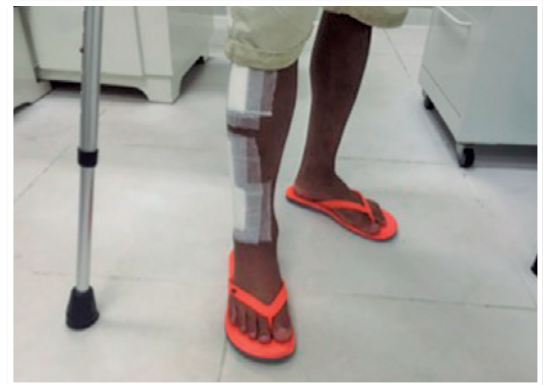

Figure 4 | Second postoperative day. Partial weight bearing with crutches.

with no complaints of pain on the 15th POD. He returned to professional sports activity on the 30th POD (Figure 5), and was able to participate at high level in a professional soccer competition 60 days after surgery.



Figure 5 | 30th postoperative day. Treadmill training.

Case 3

A 35-year-old male patient, amateur soccer player and runner, plays sports regularly (three times a week), with chronic pain (worse in the last 5 years) in the anterolateral region of the legs caused by physical exercise. No diagnosis at the time of the first orthopedic assessments of CCS, despite treatment provided by orthopedic and sports medicine professionals. Patient had a history of acute lesion in the left lower limb (LLL) after direct trauma (contusion) during a recreational soccer game, having been attended at the time in another department. The patient had an MRI as part of the emergency department treatment that detected a muscle contusion with hemorrhagic area and an increase in the contents of the left leg compartment due to edema and post-traumatic hematoma. The team that treated the patient at that time opted for conservative treatment, but the patient evolved with progressive worsening of pain symptoms, and the diagnosis of acute compartment syndrome in the leg was not performed at that time. The patient progressed to a strength deficit for ipsilateral foot extension. A late medical reassessment with our team detected neurological lesion of the fibular nerve resulting from the contusion, grade M3 hallux dorsiflexion and M4 dorsiflexion strength of the left foot, as well as exertional pain and discomfort in anterolateral region of the right leg. Physical examination did not provide any evidence of limited range of motion (ROM), loss of strength and/or sensory abnormalities in the right leg. MRI showed significant atrophy with fatty replacement involving the muscles of the anterior compartment of the left leg and absence of abnormalities in the right lower limb (RLL) at rest, but

with edema and increased volume in anterolateral compartment of the leg after undergoing the test under physical exertion (symptoms compatible with CCS). Doppler showing a positive result for extrinsic compression of the popliteal artery by the gastrocnemius muscle. Evaluated by the vascular surgery team, which affirmed that this finding was devoid of clinical significance, based on the patient's symptoms. Diagnostic review compatible with bilateral CCS, with post-contusion exacerbation and worsening of the compression on the left side, besides sequela of inadequately treated lesion. The decision was made to perform the fasciotomy of the anterior and lateral compartments of the legs (Figure 6-9) even on the sequela side. After 45 days, the patient was cleared to return to sports, reporting

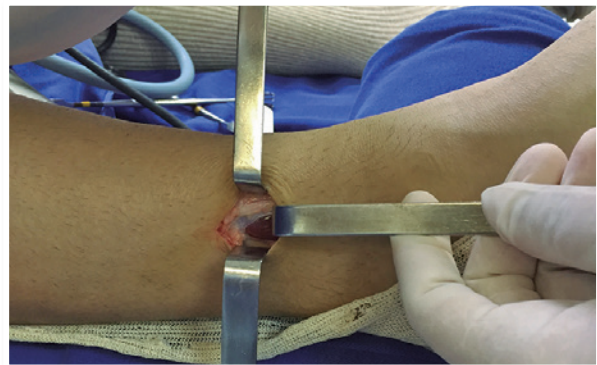


Figure 6 | Distal approach. Fasciotomy of the anterolateral compartments.

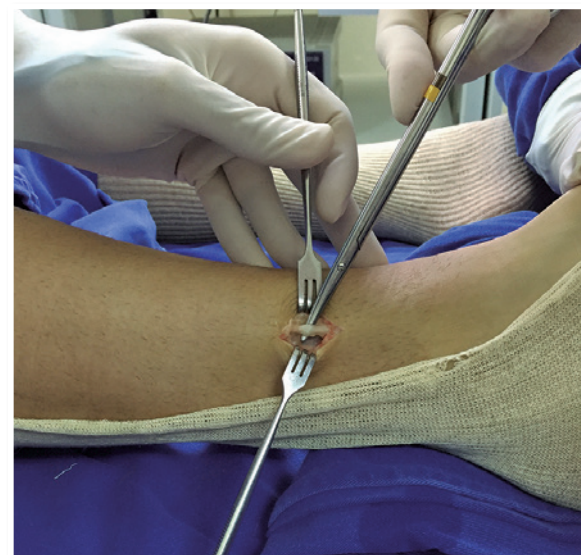


Figure 7 | Distal approach. Superficial fibular nerve.

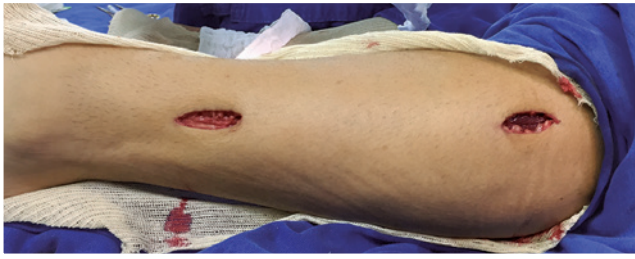

Figure 8 | Post-fasciotomy proximal and distal approaches.

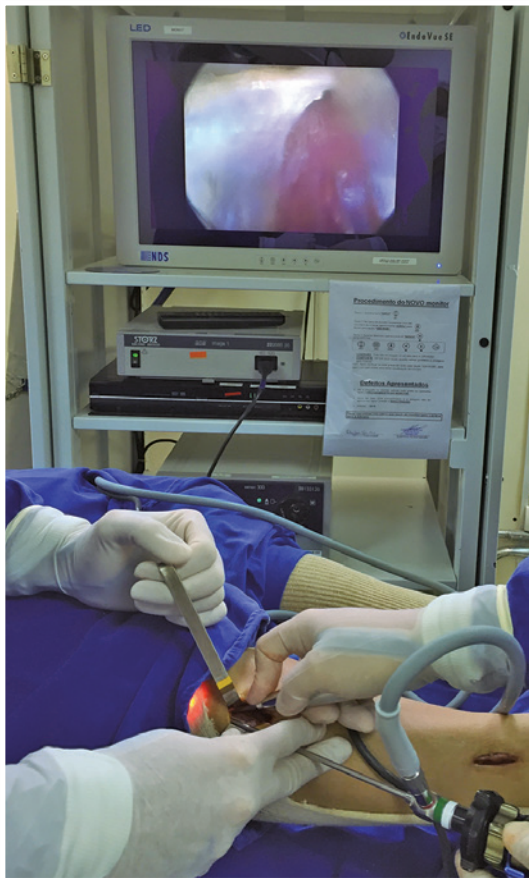

Figure 9 | Videoendoscopy-assisted fasciotomy of the anterolateral compartments.

improvement of the pain induced by exertion of the right leg, but without improvement in sequela motor deficits previously presented in the left leg.

TECHNIQUES USED AND DIAGNOSIS

Techniques including lower limb at rest/exertional MRI and lower limb Doppler ultrasound were requested in order to exclude possible differential diagnoses and because we did not have a standard kit for measuring intracompartmental

pressure (gold standard for the diagnosis of CCS) in our department.

The lower limb MRI was performed at rest and after 5 minutes of exertion (climbing and descending stairs). Bone scintigraphy was used only on suspicion of stress fracture or stress reaction. Doppler ultrasound was used to rule out possible vascular compressions and ENMG when there was the possibility of sensory and/or motor nerve involvement.

The vascular surgery department was asked to make an assessment in order to rule out possible differential diagnoses, such as extrinsic compression syndrome of the popliteal arteries, an entity characterized by the compression of these arteries, presenting in the anatomical or congenital and acquired or functional forms. Clinical symptoms usually appear upon physical exertion. In the anatomical or congenital form, fetal development disorders produce anomalies in the path of the popliteal artery or of adjacent structures that cause compression. In the acquired or functional form, hypertrophy of the adjacent muscles is identified as the only possible cause.

TREATMENT AND SURGICAL TECHNIQUE

The three patients were treated with the same surgical technique: fasciotomy of the anterior and lateral compartments of the leg, assisted by bilateral videoendoscopy, in cases 1 and 3, and unilateral videoendoscopy in the post-traumatic case (case 2), who also underwent neurolysis of the superficial fibular nerve. They were instructed to arrange physiotherapy rehabilitation as early as possible and were cleared for physical activity with progressive weight bearing.

Considering the clinical diagnosis of CCS of the legs, the surgical procedure was chosen because the patients did not show any improvement with the conservative treatment and wished to return to their usual sports activities. The surgical approach was created by making two longitudinal incisions measuring approximately 3cm in the anterolateral region of each leg. The first (distal) incision was made about 11cm from the distal tip of the fibula (Figure 1), a region where the superficial fibular nerve emerges from the lateral to the subcutaneous compartment (Figure 2), and the second (proximal), 3cm lateral to the tibial crest and 3cm below the tibial tuberosity, extending distally (Figure 3). In case 2, the only one with superficial fibular nerve inflammation, we opted for a third approach, approximately 3cm between the proximal and distal approaches, to better visualize the nerve. Neurolysis of the superficial fibular nerve was performed through the first incision, and

the videoendoscopy-assisted fasciotomy of the anterior and lateral compartments was performed through the proximal and distal incisions (Figure 3). Subcutaneous tissue and skin were then closed with separate sutures.

POSTOPERATIVE PROGRESS

The patients were discharged the day after the surgical procedure in good general condition, with partial weight bearing on crutches authorized on the second POD (Figure 4). The stitches were removed 2 weeks after the procedures. The surgical wounds were dry and there were no signs of inflammation. Full weight bearing was allowed and physical therapy rehabilitation exercises were intensified. The patients continued to be regularly monitored by our team.

RESULTS

We evaluated three clinical cases of male patients, two aged 20 years and one aged 35, all participating in some form of physical activity (professional and amateur). They were evaluated by orthopedists specializing in foot and ankle surgery and sports medicine, with complaints of pain in the legs upon exertion and with progressive worsening of symptoms. They were diagnosed with CCS after exclusion of other possible etiologies. They were treated surgically with the same technique. Just four weeks after surgery, physical exercise was allowed at the same intensity that triggered the symptoms, and all three patients reported good progress. The patient in the third clinical case continued with motor abnormalities with onset prior to the surgical procedure performed on the left leg. They currently perform their usual physical activities. They were questioned about their return to sports activities and their satisfaction with the result of the treatment. They reported a return within 45 postoperative days and appeared satisfied with the results achieved (Table 1).

DISCUSSION

Most of the published studies of CCS describe the diagnosis in athletes, mainly runners, with high-output training regimens.⁽²⁾ Patients assigned to this study stated that they

performed regular physical activity and were experiencing pain on exertion, with improvement at rest. They also reported progressive worsening of symptoms in recent months. It is known that the clinical symptoms of CCS can be described as progressive pain, usually in the lower part of the leg, during physical exertion. The pain usually begins a few minutes after starting physical activity, and the individual may often be able to describe the time or distance required to recognize the symptoms. Pain usually disappears with rest, although not immediately after discontinuation of exercise.⁽⁸⁾

Diagnosis is a challenge, since no non-invasive measurement technique has been accepted as an alternative equivalent to direct intracompartmental pressure measurement. Imaging tests should be considered as a means of excluding other diagnoses. Bone scintigraphy and MRI can be used to investigate stress fractures, stress reactions, or periostitis. Doppler ultrasound is used to rule out possible vascular compressions by means of significant occlusion or stenosis of the artery in active hyperextension and dorsiflexion maneuvers of the feet, and ENMG to rule out the possibility of sensory and/or motor nerve involvement.

Although some researchers are of the opinion that medical history and physical examination are sufficient to make the diagnosis, most believe that compartment pressure measurement is necessary.⁽⁶⁾

There is scant evidence of quality based on invasive compartment pressure measures.⁽⁵⁾ Measurement techniques, measurement time versus exercise, and criteria used for diagnosis may vary among examiners. Therefore, it is essential to have compartmental pressures measured by physicians experienced in applying the technique and in using standardized equipment to perform the measurements.

The criteria used most often to diagnose CCS in the literature were proposed by Pedowitz et al.^(2,5,9) Since there is no standardized kit available for measuring intracompartmental pressure in Brazil, we consider it important to take a detailed medical history and carry out a thorough physical examination associated with imaging tests to exclude possible differential diagnoses.

We believe that the absence of this standard kit in Brazil makes it difficult to diagnose CCS in our setting. As des-

Table 1 | Characteristics of the patients, treatment and results obtained

Patient	Age	Sex	Side affected	Treatment	Return to sports (days)	Patient satisfaction (30 th postoperative day)
1	20	Male	Bilateral	Bilateral fasciotomy	35 days	Yes
2	20	Male	Right	Unilateral fasciotomy	30 days	Yes
3	35	Male	Bilateral	Bilateral fasciotomy	45 days	Yes

cribed in case 3, even if treated by experienced professionals, the diagnosis was given late and with complications resulting from this failure. On websites such as PubMed and SciELO, we found studies in the international literature with more robust samples, such as the publication by Waterman et al., which includes 611 patients. In the national literature, on the other hand, we come across case report studies such as the one by Yoshida et al.⁽¹⁰⁾ This shows that the limitation of diagnostic methods in Brazil, among other factors, results in underdiagnosis of CCS.

Conservative measures may be attempted until the clinical diagnosis is confirmed or the intracompartmental pressure is recorded. These include running on flat surfaces, use of orthoses such as insoles and suitable athletic shoes, reduction of training volume, and strength and flexibility workouts through physical therapy. Discontinuation of symptom-inducing activities resolves most problems. However, this measure is not accepted by most patients, who want to maintain their lifestyle and quality of life. These patients should be referred for orthopedic surgical treatment. To date, no alternative non-surgical approach has proven successful in the treatment of refractory symptoms.^(2,6)

According to several observational studies, surgical treatment via fasciotomy, whether conventional or videoendoscopy-assisted, has produced good results in the majority of cases.^(2,9) CCS is an infrequently diagnosed condition, but with increasing prevalence. Nowadays it still has limitations in terms of the main diagnostic method, particularly in our field. It is important to carry out studies

that standardize the technique, the diagnostic criteria for measuring pressure, and the diffusion of this knowledge between medical specialties.

REFERENCES

1. Barnes M. Diagnosis and management of chronic compartment syndromes: a review of the literature. *Br J Sports Med.* 1997;31(1):21-7.
2. Pedowitz RA, Hargens AR, Mubarak SJ, Gershuni DH. Modified criteria for the objective diagnosis of chronic compartment syndrome of the leg. *Am J Sports Med.* 1990;18(1):35-40.
3. Raikin S, Venkat R, Vitanzo P. Bilateral simultaneous fasciotomy for chronic exertional compartment syndrome. *Foot Ankle Int.* 2005; 26(12):1007-11.
4. Lecocq J, Isner-Horobeti ME, Dupeyron A, Helmlinger JL, Vautravers P. [Exertional compartment syndrome.] *Ann Readapt Med Phys.* 2004;47(6):334-45. French.
5. Aweid O, Del Buono A, Malliaras P, Iqbal H, Morrissey D, Maffulli N, et al. Systematic review and recommendations for intracompartmental pressure monitoring in diagnosing chronic exertional compartment syndrome of the leg. *Clin J Sport Med.* 2012;22(4):356-70.
6. Shah SN, Miller BS, Kuhn JE. Chronic exertional compartment syndrome. *Am J Orthop (Belle Mead NJ).* 2004;33(7):335-41.
7. Blackman PG. A review of chronic exertional compartment syndrome in the lower leg. *Med Sci Sports Exrc.* 2000;32(3 Suppl):S4-10.
8. Bong MR, Polatsch DB, Jazrawi LM, Rokito AS. Chronic exertional compartment syndrome: diagnosis and management. *Bull Hosp Jt Dis.* 2005;62(3-4):77-84
9. Schepsis AA, Martini D, Corbett M. Surgical management of exertional compartment syndrome of the lower leg. Long-term followup. *Am J Sports Med.* 1993;21(6):811-7; discussion 817.
10. Yoshida WB, Brandão GM, Lastória S, Almeida MJ, Maffei FH. Síndrome compartimental crônica dos membros inferiores. *J Vasc Bras.* 2004;3(2):155-66.