

# Arthroscopic surgical treatment of Tillaux fracture

## Tratamento cirúrgico de fratura de Tillaux por artroscopia

Wagner Fonseca<sup>1</sup>, Gilberto Coelho Byrro Oliveira<sup>2</sup>, Rogério Andrade Gomes<sup>3</sup>,  
Luís Felipe Lyon Moura<sup>4</sup>, Carlos Filipe Teixeira Barros<sup>5</sup>

### ABSTRACT

To report efficacy of arthroscopic technique as an alternative to the opening technique. We report a case of arthroscopic osteosynthesis for Tillaux fracture. This was a 14-year-old adolescent diagnosed with Tillaux fracture on the left side. The arthroscopic assisted reduction and fixation were carried out using two double threaded compressive screws. After 2 years of follow-up the patient did not have complications and failures, and she had complete recovery of joint mobility, and reported high satisfaction with the result. Although the described technique has a longer learning curve, we showed the possibility of performing the entire procedure without opening the fracture site. The outstanding result and lack of complications might be related to the arthroscopic approach that is less aggressive to the soft tissue, and preserve the periosteum. Although a longer follow-up is needed, this technique allowed a more physiological recovery to our patient.

### Keywords:

Tibia fractures/diagnosis; Tibia fractures/surgery; Child; Arthroscopy/methods; Case reports

### INTRODUCTION

Tillaux fracture is an avulsion injury in the ankle that occurs mainly at the end of adolescence. The mechanism is ankle sprain, especially in external rotation, which may

### RESUMO

Relatar a eficácia da técnica artroscópica como alternativa à técnica aberta. A técnica cirúrgica para osteossíntese de fratura de Tillaux por artroscopia é apresentada neste trabalho. Relatamos um caso realizado em nosso grupo com um adolescente de 14 anos com diagnóstico de fratura de Tillaux do lado esquerdo. Foram realizadas a redução e a fixação por via artroscópica com o uso de dois parafusos de dupla rosca compressiva. Com aproximadamente 2 anos de acompanhamento, o paciente não apresentava complicações ou falhas, e teve retorno completo da mobilidade articular, com alto índice de satisfação. Embora a técnica descrita exija do cirurgião uma curva de aprendizado maior, demonstramos ser possível realizar todo o procedimento sem a abertura do foco de fratura. O excelente resultado e a ausência de complicações podem estar relacionados à técnica artroscópica descrita, a qual descreve menor agressividade às partes moles, preservando o periósteo. Embora seja necessário seguimento mais longo, essa técnica permitiu ao paciente uma recuperação mais fisiológica do quadro clínico.

### Descritores:

Fraturas da tíbia/diagnóstico; Fraturas da tíbia/cirurgia; Criança; Artroscopia/métodos; Relatos de casos

lead to avulsion by the distal tibiofibular ligament in its anterior portion. The fracture occurs in avulsion, characterized as a slipped capital femoral epiphysis Salter Harris type III fracture. Tillaux fracture is seen among individuals aged

<sup>1</sup> Sector of Medicine and Foot Surgery, Hospital das Clínicas, Universidade Federal de Minas Gerais, Belo Horizonte, MG, Brazil; Sector of Medicine and Foot Surgery, Hospital BIOCOR, Belo Horizonte, MG, Brazil.

<sup>2</sup> Hospital BIOCOR, Belo Horizonte, MG, Brazil.

<sup>3</sup> Department of Orthopedics and Traumatology, Hospital das Clínicas, Universidade Federal de Minas Gerais, Belo Horizonte, MG, Brazil.

<sup>4</sup> Department of Orthopedics and Trauma, Hospital das Clínicas, Universidade Federal de Minas Gerais, Belo Horizonte, MG, Brazil; Sector of Medicine and Foot Surgery at Hospital Santa Rita, Belo Horizonte, MG, Brazil.

<sup>5</sup> Sector of Medicine and Ankle and Foot Surgery, Department of Orthopedics and Trauma at Hospital das Clínicas, Universidade Federal de Minas Gerais, Belo Horizonte, MG, Brazil.

**Correspondence to:**  
Carlos Filipe Teixeira Barros  
Hospital São Domingos  
Avenida Jerônimo de Albuquerque, 540 – Bequimão  
CEP: 65060-645 – São Luís, MA, Brazil  
E-mail: cftbarros@gmail.com

**Conflict of interests:**  
none reported.

**Funding:**  
none reported.

**Received on:**  
October 16, 2015

**Accepted on:**  
April 14, 2016

12 to 15 years; in this age range, it occurs at the beginning of the distal tibia physal cartilage. The medial cartilage of the distal tibia closes, and the lateral remains opened when receiving the rotation stress, thereby suffering an avulsion fracture.<sup>(1-6)</sup>

The Brazilian national literature contains only one report on Tillaux fracture. For that case, an arthroscopic method was used for treatment; however, some authors have reported that it is impossible to fix the fracture by using arthroscopy and thus opened the focus of the fracture.<sup>(7)</sup> They concluded that arthroscopy should be used as an adjuvant method to reduce Tillaux fracture but should not be the exclusive and self-sufficient method for treatment of this of injury.<sup>(8)</sup>

The world literature reports few cases of the use of arthroscopy to reduce and fix ankle fractures in childhood and adolescence. In adults, the tendency toward this stype of surgery even greater in order to reduce commitment of soft parts in the ankle, improve accuracy of reduction of intra-articular fractures, and improve inspection of associated injuries, such as chondral injuries.<sup>(9)</sup>

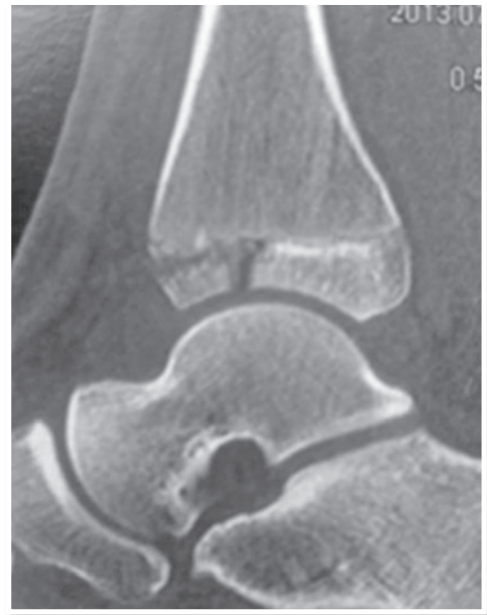We present an arthroscopic reduction and fixation technique for Tillaux fracture in the left ankle of an adolescent who was an amateur basketball player.

## CASE REPORT

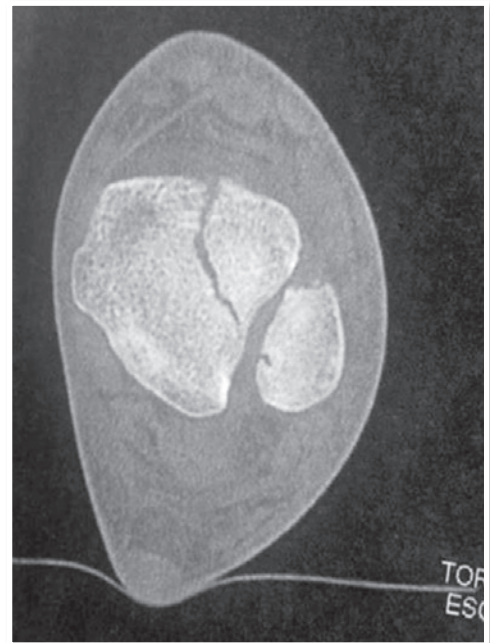A Tillaux avulsion fracture occurred in the left ankle of a 14-year-old adolescent (Figures 1 to 3). The fracture was treated with arthroscopy via a classical anteromedial and anterolateral portal for the ankle using an optic of 4.8 mm and 30° (used regularly in arthroscopy of the ankle).

Reduction and fixation were carried out by an anterolateral portal under visualization by an anteromedial portal. Initially, we identified the fracture trait, performed intra-articular trait cleaning of the shaver of soft parts, identified the presence of synovitis and fracture hematoma, and removed interposition of the periosteum in the focus of the fracture (Figures 4 and 5). We analyzed the quality and integrity of deltoid ligament and syndesmosis.

By using a blunt instrument (posterior part of the head of a delicate curette), we carried out reduction of the fragment by using direct visualization by arthroscopy (Figure 6). We temporarily fixed the fragment with screws, guided by cannulated screws (Figure 7). Again, a good-quality reduction was achieved by using the arthroscopic optic, and after that the fragment was fixed with screws (Figure 8). We carried out the fixation with two screws with a double compressive screw cap. At the end of the procedure,

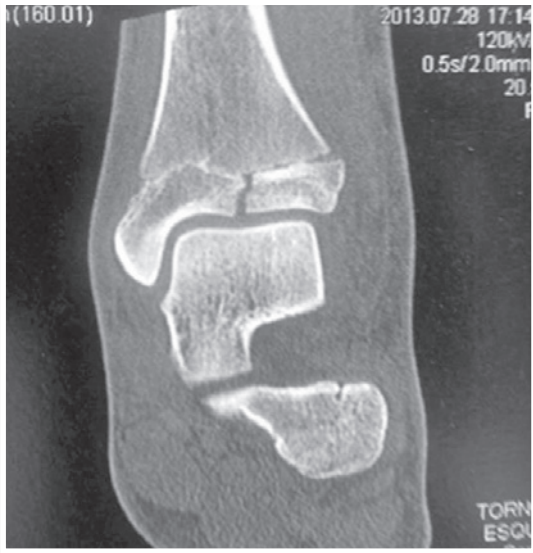

**Figure 1** | Computed tomography, sagittal slice.

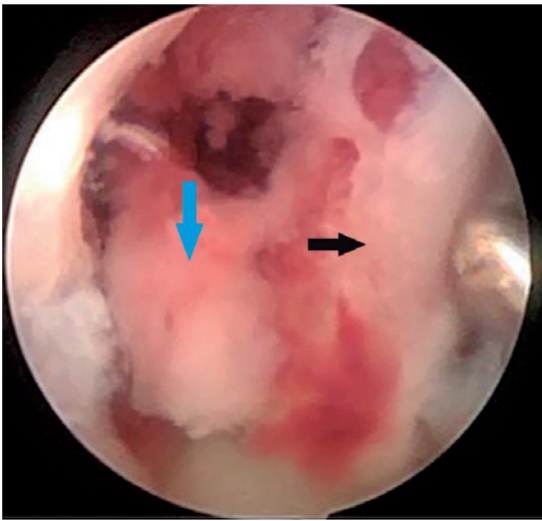


**Figure 2** | Computed tomography, axial slice.

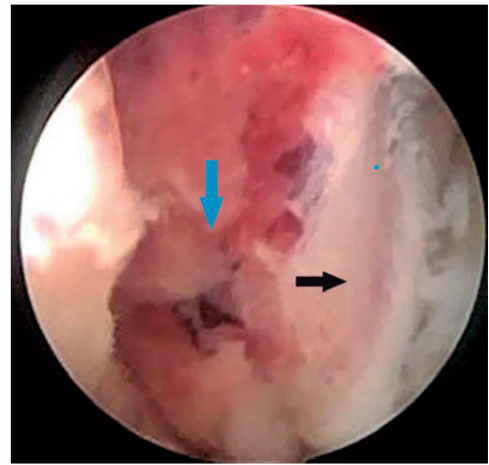
control of reduction was achieved by direct viewing by arthroscopy (Figure 9) and by intensification of images in order to ensure that reduction occurred in all planes and to verify the size of screws (Figures 10 and 11). Because this was an acute fracture, we took caution by not using an infusion pump but adjusted inflow by severity because of



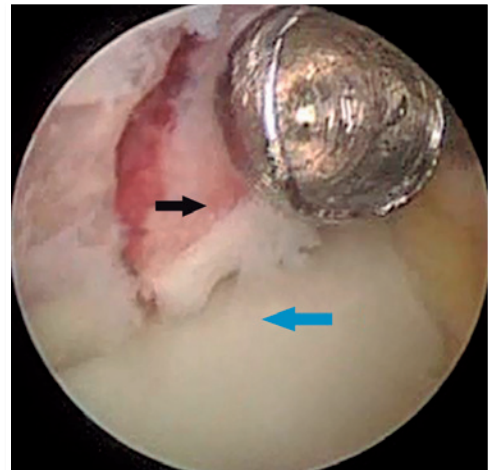
**Figure 3** | Computed tomography, coronal slice.



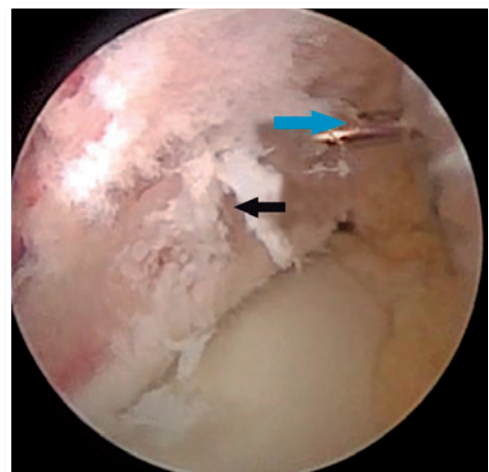
**Figure 4** | Arthroscopic view of the fracture, with hematoma and periosteum mediating the reduction (blue arrow). Tillaux fragment is shown by black arrow.



**Figure 5** | Viewing after cleaning of focus of fracture (blue arrow). Tillaux fragment is shown by black arrow.



**Figure 6** | Reduction of Tillaux fragment (black arrow) with blunt instrument. Talus is shown by blue arrow.



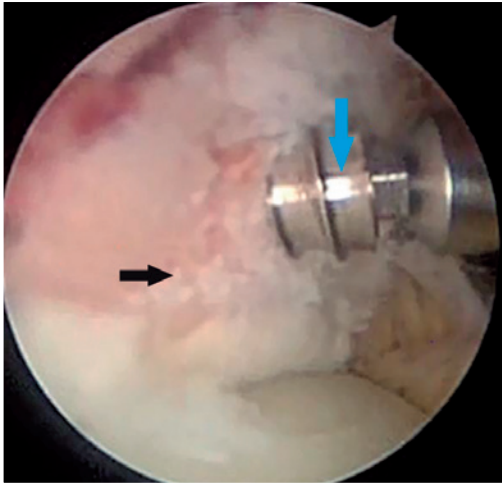
**Figure 7** | Fixation of fragment (black arrow) with cannulated screw with guide wire (blue arrow).

the risk of excessive edema of soft parts, mainly if there is an associated capsule. If the surgeon decides to use an infusion pump, the literature recommends maintaining high flow associated with low pressure, which avoids infiltration of fluid in soft parts.

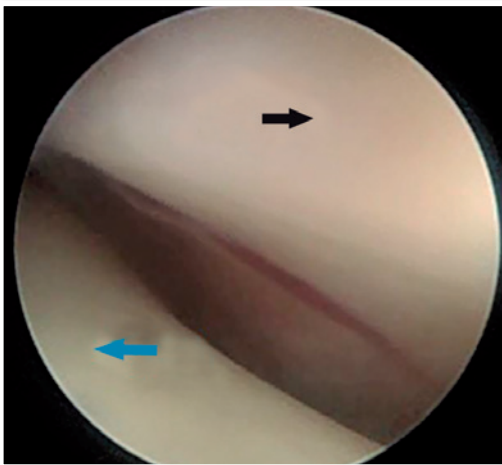
We did not use any type of distraction of the ankle.

## RESULTS

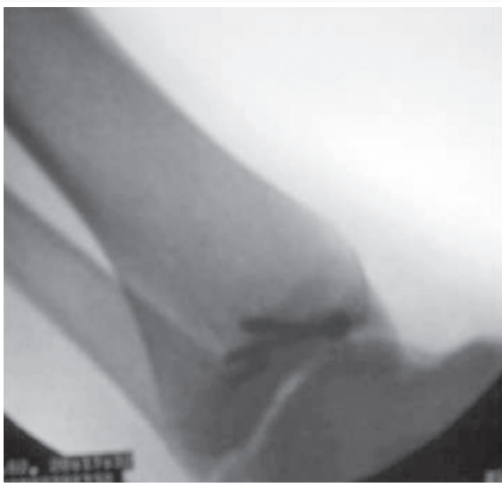Reduction and fixation were performed arthroscopically, and there was no need to open the focus of the



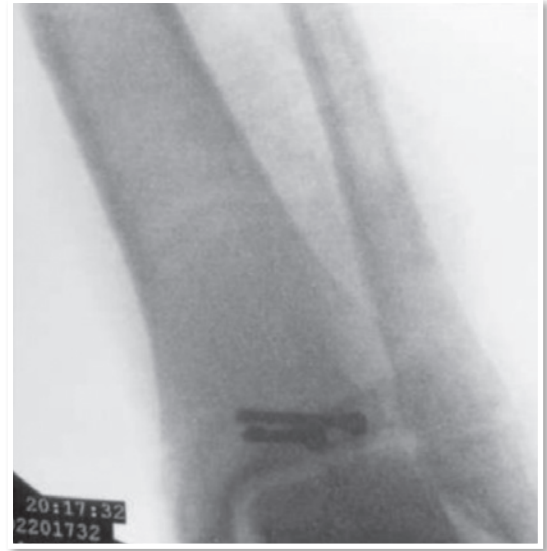**Figure 8** | Fixation with cannulated screw (blue arrow). Tillaux fragment is shown by black arrow.



**Figure 9** | Intraarticular view after fixation. Tibia is shown by black arrow and talus by blue arrow.



**Figure 10** | Perioperative radiograph.



**Figure 11** | Perioperative radiograph.

fracture. The patient was initially evaluated after 1, 3 and 6 weeks and, after that, 3, 6, 10, 18 and 24 months (current data). We started moving the joint 7 days after the surgery. The patient returned to his sports competitions within 4 months, without report of any complication. There is no loss of joint mobility compared with the contralateral side. After 4 weeks, the patient presented symmetry in joint movement compared with the contralateral side. We obtained an American Orthopaedic Foot and Ankle Society (AOFAS) score of 100 for the hindfoot.

## DISCUSSION

Van Dijk<sup>(8)</sup> and Amendola et al.<sup>(1)</sup> confirmed the possibility of performing the entire procedure by a closed technique, without the need to open procedure at the focus of the fracture. This minimized joint aggression and risk of involving the soft parts, and it must be higher in relation to an open technique. Although arthroscopy enables direct visualization of the lines of fracture, the procedure still presents high technical demand for reduction of fragments by limited incisions and to obtain rigid fixation.

Because this is a case report, there was no control group with which to evaluate the superiority of this technique. However, the result was good and suggests that the technique is promising for continued use. The ideal would be a larger sample such as reported in the reports by Rubin,<sup>(7)</sup> Guhl et al.<sup>(5)</sup> and Amendola et al.<sup>(1)</sup> In this way, evidence would be created in the Brazilian national literature and confirm that this is the ideal technique for treatment of this type of fracture.

## CONCLUSION

An arthroscopic technique is an efficient method to reduce intra-articular fractures in children and adolescents, mainly in cases of Tillaux fracture. Because this is a case report, it is important to emphasize again that, although arthroscopic reduction should provide better results than an open procedure, affirmation requires further studies to compare these two techniques and studies that include large case series.

## REFERENCES

1. Amendola A, Stone JW. *Advanced arthroscopy: the foot and ankle*. Philadelphia: Saunders-Elsevier; 2010.
2. Bucholz RW, Court-Brown CM, Heckman JD, Tornetta III P, editors. *Rockwood and Green's fractures in adults*. 7th ed. New York: Lippincott Williams & Wilkins; 2010.
3. Coughlin MJ, Saltzman CL, Anderson RB. *Surgery of the foot and ankle*. 9th ed. Philadelphia: Elsevier Saunders; 2014.
4. Flynn JM, Skaggs DJ, Waters PM, editors. *Rockwood and Wilkins fractures in children*. 8th ed. Philadelphia: Kluver; 2015.
5. Guhl JF, Parisien JS, Boynton MD. *Foot and ankle arthroscopy*. 3rd ed. New York: Springer; 2003.
6. Nery CA, Carneiro Filho M, Barroco RS. Artroscopia do tornozelo como método auxiliar no tratamento da fratura juvenil de Tillaux. *Rev Bras Ortop*. 1997;32(4):272-4 .
7. Rubin LG. Arthroscopy of the ankle and foot. *Clin Podiatr Med Surg*. 2011;28(3):xv-xvi.
8. Van Dijk CN. *Ankle arthroscopy*. New York: Springer; 2014.
9. Wenger DR, Pring ME. *Rang's children's fractures*. 3rd ed. Philadelphia: Lippincott Williams & Wilkins; 2006.