

Postoperative evaluation of patients submitted to ankle arthroscopy using the Karlsson score

Avaliação pós-operatória dos pacientes submetidos à artroscopia do tornozelo pelo escore de Karlsson

Marcus Vinicius Mota Garcia Moreno¹, Janice de Souza Guimarães², Marilton Jorge Torres Gomes², Túlio Eduardo Marçal Vieira², Vitor Souza Jalil², Gabriela Silveira Nonato³, Francisco Honório Júnior³, Laércio Cardoso de Andrade²

ABSTRACT

Objective: The objective of this study was to evaluate the clinical response of patients treated by ankle arthroscopy, using the Karlsson score, by comparing pre- and postoperative values obtained through the analysis of certain parameters. **Methods:** Twenty-four patients were studied in the period September 2013 to January 2015. The main diagnoses treated were: synovitis, anterolateral impingement, osteochondral fracture, intra-articular loose bodies, complications of ankle fractures, and osteoarthritis. **Results:** All patients evolved with clinical and functional improvement of the ankle, as demonstrated by the Karlsson score. **Conclusion:** We conclude that the arthroscopic technique is effective for treatment for the abovementioned pathologies, as demonstrated by the progress in the values obtained.

Keywords:

Arthroscopy; Clinical diagnosis; Karlsson score

INTRODUCTION

The ankle joint has always been approached by open visualization, using arthrotomy and, often, malleolar osteotomy.⁽¹⁾ Ankle arthroscopy has enabled us to obtain a direct view of the entire joint and its intra-articular structures, increasing the diagnostic capacity and simplifying the sur-

RESUMO

Objetivo: O objetivo deste estudo consiste em avaliar a resposta clínica dos pacientes tratados pela artroscopia do tornozelo pelo uso do escore de Karlsson, através da comparação de valores pré e pós-operatórios obtidos pela análise de determinados parâmetros. **Métodos:** Foram estudados 24 pacientes no período compreendido entre setembro de 2013 e janeiro de 2015. Os principais diagnósticos tratados foram: sinovite, pinçamento anterolateral, fratura osteocondral, corpos livres intra-articulares, sequelas de fraturas do tornozelo e osteoartrose. **Resultados:** Todos os pacientes evoluíram com melhora clínica e funcional do tornozelo, comprovada através do escore de Karlsson. **Conclusão:** Concluímos que existe eficácia da técnica artroscópica de tratamento para as patologias citadas, haja vista o progresso dos valores obtidos.

Descritores:

Artroscopia; Diagnóstico clínico; Escore de Karlsson

gical procedure⁽¹⁾. Indications for ankle arthroscopy have evolved due to the increase in the number of imaging techniques that have made the diagnosis of chronic ankle pain more precise.^(2,3) The most common indications are represented by evaluation of symptoms in a posttraumatic ankle without an accurate diagnosis, bone lesions, osteochondral

Correspondence to:

Marcus Vinicius Mota Garcia Moreno
Rua João das Botas, 28 – Canela
Zip Code: 40110-160 – Salvador, BA, Bahia
E-mail: marcusviniciusmoreno@gmail.com

Conflict of interest:

none reported.

Funding:

none reported.

Received on:

February 16, 2017

Accepted on:

May 15, 2017

¹ Responsible for the Foot and Ankle Surgery Sector of the Trauma and Orthopedic Clinic – COT.

² Member of the Foot and Ankle Surgery Sector of the Trauma and Orthopedic Clinic – COT.

³ Intern of the Foot and Ankle Surgery Sector of the Trauma and Orthopedic Clinic – COT.

lesions of the talar dome, anterior tibiotalar osteophytes, intra-articular loose bodies, fracture sequelae,^(4,5) anterior talofibular ligament injury, chronic painful synovitis, tibio-tarsal arthrosis, resection of meniscal lesions, of fibrous synovial adhesions that cause impingement in the tibio-talar joint, in the medial or fibular malleolar regions of the talus and in syndesmosis, arthrofibrosis and scar tissue adhesions^(1,2,6-9).

The aim of this study was to evaluate the patients' clinical response using the Karlsson score^(2,10), comparing pre and postoperative values.

METHODS

Between September 2013 and January 2015, 24 ankle arthroscopies were performed by our department (Table 2). In these 24 surgeries, 19 cases of synovitis, two cases of anterolateral impingement, 11 cases of osteochondral fracture, six cases of intra-articular loose bodies, and two cases of patients with fracture sequelae or arthrosis were treated. In eight cases, it was necessary to combine the arthroscopic technique with an open procedure, since these patients had an associated ligament injury.

Table 1 | Karlsson scoring scale (100 points)

| Criteria | Scores |
|---------------------------------|--|
| Instability | No instability = 25 1 or 2 sprains per year = 20 Instability on uneven ground = 10 Instability on even ground = 5 Constant instability = 0 |
| Pain | No pain = 20 During exercise = 15 Pain on uneven ground = 10 Pain on even ground = 5 Constant pain = 0 |
| Swelling | No swelling = 10 After exercise = 5 Constant = 0 |
| Stiffness | No stiffness = 5 Moderate = 2 Constant = 0 |
| Sports, daily living activities | No post-injury changes = 15 Less sports = 10 Lighter work and less sports = 5 Severely impaired = 0 |
| Stair climbing | No problems = 10 Impaired = 5 Impossible = 0 |
| Running | No problems = 10 Impaired = 5 Impossible = 0 |
| Support | None = 5 Support during exercise = 2 Support during daily activities = 0 |

Source: Karlsson et al., 1995.

The fact-finding and all the work was approved by the Institutional Review Board of the Hospital.

Arthroscopies were performed with therapeutic objectives in all cases after a precise clinical and imaging-based diagnosis through magnetic resonance imaging (MRI). Our analysis of results is based on 15 male patients (62.5%) and nine female patients (37.5%). The right ankle was involved in 13 cases (54.16%) and the left ankle in 11 cases (45.84%). The mean age was 38 years and 5 months, ranging from 17 to 62 years.

Distraction was performed with a traction system for better visualization of the joint.

Standard arthroscope optics of 2.7mm and 30-degree angle of inclination were used in all cases.

The anterolateral and anteromedial portals were used as they were considered the safest in our arthroscopies.

The Karlsson scoring system was used for analysis. In this system, scores are assigned to certain parameters (Table 1) that involve limitations and capacities for activities performed by the patient.

Pre and postoperative values were compared^(2,10). Values above 90 points correspond to excellent results while values between 81 and 90 points are equivalent to good results. Fair results correspond to a score between 61 and 80 points. Poor results are found at values below 60 points^(2,10).

RESULTS

The 24 patients who were analyzed had a general average of 50.45 points in the preoperative period on the Karlsson scale^(2,10). They progressed postoperatively to an average of 85.41 points (Figure 1). We obtained excellent results in patients treated for osteochondral fractures (91.2 points) and loose bodies (94.5 points). Good results were observed in anterolateral impingement (85 points) and synovitis (87 points). Fracture sequelae had a fair result (70.5 points), as shown in graph 1.

In our analysis of results, the diagnosis of osteochondral lesions of the talus found was 54% with stage III lesions, 36% in stage IV, and only 10% in stage II.

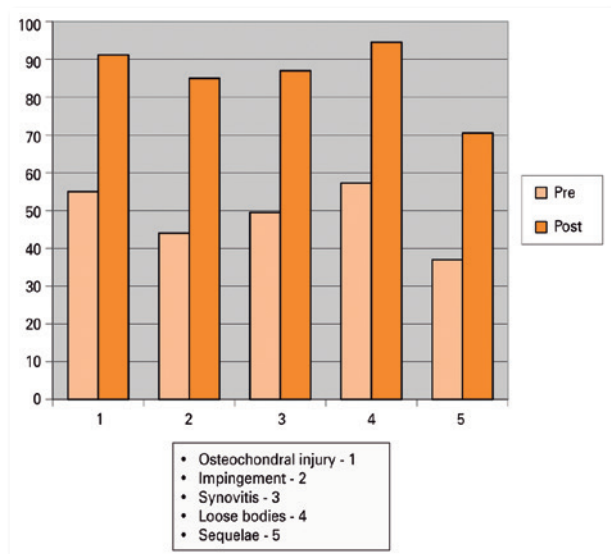
DISCUSSION

Osteochondral fracture of the talus

This consists of an injury to the articular area of the talus produced by a force transmitted by the articular surface of the contiguous bone through the joint and the articu-

Table 2 | Data of the patients

| Patient | Diagnosis | Sex | Age | Side | Pre | Post |
|---------|---|--------|-----|-------|-----|------|
| 1-JRRS | Ligament injury Synovitis Impingement | Male | 41 | Left | 44 | 85 |
| 2-GPVC | Synovitis Ligament injury | Female | 26 | Right | 17 | 77 |
| 3-PRSJ | Loose body Osteochondral fracture (Stage IV) Ligament injury | Male | 24 | Left | 39 | 95 |
| 4-DRR | Loose body Ligament injury Osteochondral fracture (Stage IV) | Male | 17 | Left | 39 | 95 |
| 5-WJMD | Fracture sequelae Loose body Synovitis | Male | 25 | Right | 52 | 87 |
| 6-MMSF | Synovitis Ligament injury | Male | 20 | Left | 34 | 95 |
| 7-ARBM | Osteochondral fracture (Stage IV) Synovitis Ligament injury | Female | 42 | Right | 22 | 54 |
| 8-DPM | Osteochondral fracture (Stage IV) Synovitis | Female | 52 | Right | 39 | 90 |
| 9-FASF | Osteochondral fracture (Stage IV) Synovitis | Male | 36 | Left | 64 | 100 |
| 10-MJSR | Synovitis Impingement | Female | 38 | Left | 44 | 85 |
| 11-MOS | Synovitis Loose body Osteochondral fracture (Stage III) | Male | 29 | Right | 64 | 95 |
| 12-APD | Osteochondral fracture (Stage III) Synovitis | Female | 47 | Right | 55 | 90 |
| 13-MAG | Ligament injury synovitis | Male | 36 | Right | 67 | 95 |
| 14-PSA | Osteochondral fracture (Stage III) loose body synovitis | Male | 38 | Left | 70 | 95 |
| 15-GASO | Loose body synovitis | Female | 42 | Right | 80 | 100 |
| 16-JDP | Synovitis ligament injury | Male | 57 | Right | 39 | 85 |
| 17-JWMS | Synovitis osteoarthritis | Male | 37 | Left | 22 | 54 |
| 18-MCAA | Synovitis | Female | 34 | Right | 55 | 96 |
| 19-MSPO | Synovitis | Male | 43 | Left | 64 | 100 |
| 20-OJD | Osteochondral fracture (Stage III) | Male | 54 | Right | 64 | 95 |
| 21-MVSA | Synovitis ligament injury | Male | 62 | Left | 52 | 87 |
| 22-VLAS | Synovitis ligament injury | Female | 46 | Right | 55 | 85 |
| 23-EMRG | Osteochondral fracture (Stage II) | Male | 29 | Right | 80 | 95 |
| 24-GFS | Osteochondral fracture (Stage II) | Female | 47 | Left | 70 | 100 |



Graph 1 | Comparison of pre- and postoperative values – ankle arthroscopy.

lar cartilage to the subchondral trabecular structure of the fractured bone⁽¹³⁾. This condition has been described using a variety of names, including osteochondritis dissecans and transchondral talar dome fracture⁽⁴⁾. Berndt and Harty developed a four-stage classification of osteochondral injury through anatomical studies in cadavers, showing the etiological mechanism of chondral talar dome lesions^(1,4,13,14).

The main cause of this injury is traumatic etiology, but there are cases of patients who have developed osteonecrosis without a history of trauma or bilaterally, with favorable accounts of idiopathic causes in some cases.

Due to the high rates of postoperative complications with open procedures (such as joint stiffness, atrophy and malleolar pseudarthrosis), arthroscopy has proven superior in the treatment of these injuries as it eliminates many of these complications and enables easy debridement of talus lesions, removal of loose bodies and small intra-articular fragments^(1,4,15). In our study, we had 11 cases of osteochondral fracture.

Stage III patients had a mean score of 64.5 points in the preoperative period and 95.8 points in the postoperative period. Patients in stage IV had 34.75 points in the preoperative period and 83.5 in the postoperative period, averaging 55 points in the preoperative period and 91.2 points in the postoperative period for all stages. Based on the Karlsson scale, this is considered an excellent result^(2,10).

Anterolateral impingement

This term refers to contact between the anterior part of the tibia and the dorsal part of the talus that occurs during foot dorsiflexion⁽¹⁶⁾. The process begins when an accentuated inversion displaces fibers from the anterior talofibular ligament and anterior inferior tibiofibular ligament, occasionally accompanied by fibers from the calcaneofibular ligament. Repetitive movements can cause inflammation in the ligament trajectory areas, resulting in synovitis and formation of scar tissue, which, when enlarged, produce impingement of the mass of tissue between the talus, tibia and fibula, which may cause pain and irritation.

Radiological studies have shown no efficiency in diagnosing impingement, although they may be useful for diagnosing other causes of chronic ankle pain. If instability is suspected, stress radiographs should be taken. In some cases, an MRI may aid in diagnosis; however, it is also related to false negative results⁽¹⁷⁾.

In our study, we had two cases of anterolateral impingement with a mean score of 44 points in the preoperative period and 85 points in the postoperative period. This is considered a good result^(2,10) according to the Karlsson scale, although it is slightly below the mean of the analyzed results, since 54% achieved excellent results (more than 90 points), and 46% good results (81 to 90 points)⁽¹⁾.

Synovitis

Patients who suffer persistent and long-term posttraumatic ankle pain despite the use of conservative methods of treatment (such as immobilization, non-hormonal anti-inflammatory drugs, rest and physical therapy) may present with ankle synovitis. These patients benefit from arthroscopy for synovium diagnosis and resection⁽⁴⁾. People with symptoms of rheumatoid arthritis can also be helped with this procedure. Other less common types of nontraumatic synovitis include congenital constriction band syndrome, villonodular synovitis, gouty arthritis, infection, and arthrofibrosis^(1,4,7).

Here we had 19 cases of posttraumatic synovitis with a mean score of 49.5 points in the preoperative period and 87 points in the postoperative period on the Karlsson scale.⁽²⁾

Bone lesions

This group includes intra-articular loose bodies, cystic lesions and ossicles at the tip of the malleolus⁽⁴⁾. The most common cause are loose bodies and these can occur as a result of trauma or osteochondromatosis. Treatment is performed by resecting the loose bodies, which can be very

numerous^(1,18). In our study, we had six cases of intra-articular loose bodies with a mean score of 57.3 points in the preoperative period and 94.5 points in the postoperative period, which is considered an excellent result based on the Karlsson parameters^(2,10), and is consistent with the article by Bonnim et al. (2008)⁽³⁾.

Fracture sequelae

Major destruction of the cartilaginous joint surface is observed after a severe ankle fracture. In cases in which the patient presents with intense pain, arthrodesis of the joint is indicated and can be performed by arthroscopy⁽³⁾. All the cartilage is debrided with a motorized instrument after which an autologous graft is inserted⁽⁴⁾. In our study, we had two cases of fracture sequelae and arthrosis with a mean score of 37 points in the preoperative period and 70.5 points in the postoperative period, based on the Karlsson scoring system^(2,10). The score is a fair result in the arthroscopic treatment of these lesions, which coincides with data from the literature.

CONCLUSION

Ankle arthroscopy is a safe, minimally invasive and effective method to treat the pathologies addressed here, besides allowing postoperative recovery and early functional rehabilitation.

In this study, the use of the Karlsson score proved effective as an evaluation method, demonstrating the patient's clinical and functional progress after the surgical procedure.

The results were excellent in the treatment of osteochondral fractures and intra-articular loose bodies, good in cases of synovitis and joint impingement, and fair in patients with fracture sequelae and arthrosis.

REFERENCES

1. Souza, J. M. G.: Cirurgia artroscópica do tornozelo. *Rev Bras Ortop.* 1997; 32(4):283-8.
2. Bonnin M, Bouysset M. Arthroscopy of the ankle: analysis of results and indications on a series of 75 cases. *Foot Ankle Int.* 1999;20(11): 744-51.
3. Bonnim M. Ankle sprain sequelae. In: Bouysset M (editor). *Bone and joint disorders of the foot and ankle: a rheumatological approach.* Paris: Springer; 1998, p. 287-302.
4. Ferkel RD, Scranton PE Jr. Arthroscopy of the ankle and foot. *J Bone Joint Surg Am.* 1993;75(8):1233-42.
5. Parisien JS, Vangness T, Feldman R. Diagnostic and operative arthroscopy of the ankle. An experimental approach. *Clin Orthop Relat Res.* 1987;(224):228-36.
6. Stetson WB, Ferkel RD. Ankle Arthroscopy: II. Indications and Results. *J Am Acad Orthop Surg.* 1996;4(1):24-34.
7. Ferkel RD. Soft tissue pathology of ankle. In: McGinty JB (editor). *Operative arthroscopy.* New York: Raven Press; 1991. p. 713-25.
8. Myerson MS, Quill G. Ankle arthrodesis. A comparison of an arthroscopic and an open method of treatment. *Clin Orthop Relat Res.* 1991;(268):84-95.
9. Ogilvie-Harris DJ, Mahomed N, Demazière A. Anterior impingement of the ankle treated by arthroscopic removal of bony spurs. *J Bone Joint Surg Br.* 1993;75(3):437-40.
10. Karlsson J, Peterson L. Evaluation of ankle joint function: the use of a scoring scale. *Foot.* 1991; 1(1):15-9.
11. Takao M, Ochi M, Shu N, Naito K, Matsusaki M, Tobita M, Kawasaki K. Bandage distraction technique for ankle arthroscopy. *Foot Ankle Int.* 1999;20(6):389-91.
12. Watanabe M. *Selfoc-Arthroscope (Watanabe no. 24 Arthroscope).* Monograph. Tokyo: Teishin Hospital; 1972.
13. Berndt AL, Harty M. Transchondral fractures (osteochondritis dissecans) of the talus. *J Bone Joint Surg Am.* 1959;41(7):988-1020.
14. Taranow WS, Bisignani GA, Towers JD, Conti SF. Retrograde drilling of osteochondral lesions of the medial talar dome. *Foot Ankle Int.* 1999;20(8):474-80.
15. Van Buecken K, Barrack RL, Alexander AH, Ertl JP. Arthroscopic treatment of transchondral talar dome fractures. *Am J Sports Med.* 1989;17(3):350-5.
16. Nery CA, Filardi M, Filho MC, Cohen M, Abdalla RJ. Abordagem artroscópica do pinçamento tíbio talar anterior. *Rev Bras Ortop.* 1994;29:570-72.
17. Ferkel RD, Karzel RP, Del Pizzo W, Friedman MJ, Fischer SP. Arthroscopic treatment of anterolateral impingement of the ankle. *Am J Sports Med.* 1991;19(5):440-6.
18. Ferkel RD. Differential diagnosis of chronic ankle sprain in the athlete. *Sports Med Arthrosc Rev.* 1994; 2: 274-83.