

Use of peripheral nerve block in ankle surgery as postoperative analgesia

O uso do bloqueio periférico do tornozelo como analgesia pós-operatória

Kelly Cristina Stéfani¹, Miguel Viana Pereira Filho², Gabriel Ferraz Ferreira³

ABSTRACT

Objective: To evaluate the use of the peripheral nerve block of the foot and ankle as a method of postoperative analgesia. **Methods:** A case series study of patients submitted to peripheral nerve block after surgery with spinal anesthesia. The inclusion criteria were patients submitted to foot and ankle surgery at our institution. The patients filled out a postoperative questionnaire, assigning a score for pain intensity, according to the Visual Analog Scale (VAS), and time of onset of the pain. **Result:** The patients reported a mean time of 14.50 hours for the onset of pain after the surgical procedure. The mean pain intensity score on the Visual Analog Scale was 2.94 immediately after surgery, 3.81 on day one after surgery, and 3.00 on day two after surgery. **Conclusion:** The study demonstrated that peripheral nerve block in the foot and ankle region maintained prolonged analgesia with low pain intensity, particularly immediately after surgery, enabling postoperative physiotherapy to the maximized.

Keywords:

Anesthesia and Analgesia; Nerve block; Peripheral nerves; Foot; Ankle

RESUMO

Objetivo: Avaliar a utilização do bloqueio periférico do pé e tornozelo como método de analgesia pós-operatória. **Métodos:** Estudo de série de caso dos pacientes submetidos ao bloqueio anestésico periférico após a cirurgia com raquianestesia. O critério de inclusão foram os pacientes submetidos à cirurgia de pé e tornozelo na nossa instituição. Os pacientes responderam ao questionário no pós-operatório, com a aferição da intensidade da dor pela Escala Visual Analógica (EVA) e do tempo do início da dor. **Resultado:** Os pacientes referiram um tempo médio de 14,50 horas para o início da dor após o procedimento cirúrgico. A média da Escala Visual Analógica da dor foi de 2,94 no pós-operatório imediato, 3,81 no primeiro dia de pós-operatório, e no segundo-dia de pós-operatório apresentou média de 3,00. **Conclusão:** O estudo demonstrou que o bloqueio de nervo periférico na região do pé e tornozelo manteve uma analgesia prolongada com baixa intensidade da dor, principalmente no pós-operatório imediato, permitindo maximizar a fisioterapia pós-operatória.

Descritores:

Anestesia e analgesia; Bloqueio nervoso; Nervos Periféricos; Pé; Tornozelo

¹ Master degree in Orthopedics and Traumatology, Foot and Ankle Surgery Group, Department of Orthopedics and Traumatology, Hospital do Servidor Público Estadual de São Paulo, São Paulo, SP, Brazil.

² Orthopedist, Foot and Ankle Surgery Group, Department of Orthopedics and Traumatology, Hospital do Servidor Público Estadual de São Paulo, São Paulo, SP, Brazil.

³ Orthopedist and Pursuing Foot and Ankle Specialization with the Foot and Ankle Surgery Group, Department of Orthopedics and Traumatology, Hospital do Servidor Público Estadual de São Paulo, São Paulo, SP, Brazil.

Correspondence to:

Kelly Cristina Stéfani
Rua Mato Grosso, 306 – cj 1.315 – Higienópolis
Zip Code: 01239-040 – São Paulo, SP, Brazil
E-mail: kstefani@institutokellystefani.com.br

Conflict of interest:
none reported.

Funding:
none reported.

Received on:
May 8, 2017

Accepted on:
June 6, 2017

INTRODUCTION

Peripheral nerve block in the foot and ankle is generally used for anesthesia in forefoot and midfoot surgeries⁽¹⁾. However, since the postoperative analgesia obtained is prolonged, we can expand its use, not as a main anesthesia, but as an adjunct after the end of the surgery with spinal or general anesthesia⁽²⁾.

There are several advantages described in relation to peripheral nerve block: postoperative pain reduction⁽³⁾, increase in analgesia time⁽⁴⁾, reduction of hospital costs and length of hospital stay⁽⁵⁻⁷⁾.

The expansion of the use of peripheral nerve blocks has made this type of anesthesia increasingly safer and more reliable, with fewer complications⁽⁸⁾.

The aim of this study was to evaluate the use of the peripheral nerve block of the foot and ankle as a method of postoperative analgesia in a case series.

METHODS

Patients who underwent surgery performed by the foot and ankle group of our institution between June 2016 and January 2017 were recruited to participate in this prospective study once the informed consent form had been signed and the approval of the Plataforma Brasil database obtained.

The inclusion criterion was patients undergoing foot and ankle surgery at our institution. Exclusion criteria were patients with coagulopathy, surgery of local infection, partial or total amputations, and peripheral neuropathy.

The study participants completed the initial preoperative questionnaire answering questions about: habits, sex and work situation (active or retired). We supplemented the questionnaire with the surgical data: laterality and region of the procedure (forefoot, midfoot, hindfoot, or ankle).

All the participants were given spinal anesthesia by the same team of anesthetists. We performed the peripheral nerve block of the foot and ankle after the end of the surgical procedure.

The local anesthetic peripheral nerve block was performed using 20mL of ropivacaine at a strength of 7.5mg/mL (0.75%). All the nerve blocks were performed by the same orthopedic team.

We performed the anesthetic block following the anatomical technique of the five ankle nerves:

Tibial nerve: We infiltrated 10mL of anesthetic, flexing the knee around 90 degrees, at a point located two fingers

proximal to the medial malleolus and perpendicular to the long axis of the tibia, tangent to the medial border of the Achilles tendon (Figure 1).

Deep peroneal nerve: We inserted the needle in the space between the first and second ray, between the extensor hallucis longus and the extensor digitorum longus, lateral to the dorsalis pedis artery, with 2mL of the anesthetic (Figure 2).

Superficial peroneal nerve: fan-shaped subcutaneous infiltration at the height of the ankle, from medial to lateral, with 6mL of anesthetic for the superficial peroneal nerve (Figure 3).

Saphenous nerve: located around 2cm anterior to the medial malleolus, subcutaneous application of 2mL for the nerve block (Figure 4).

Sural nerve: located from 1.0 to 1.5cm distal to the tip of the fibula, with indication for 2mL subcutaneous infiltration (Figure 5).

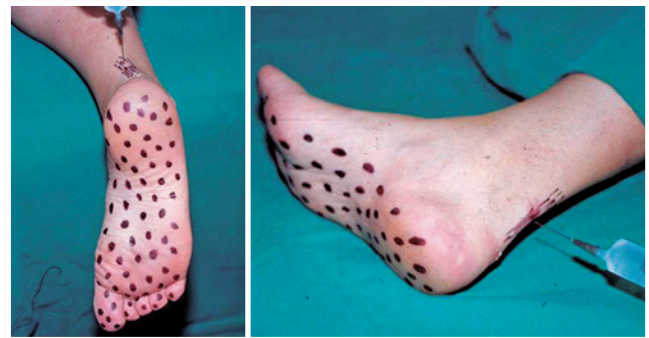


Figure 1 | Sensitive area of the tibial nerve (Source: Author's personal archive).

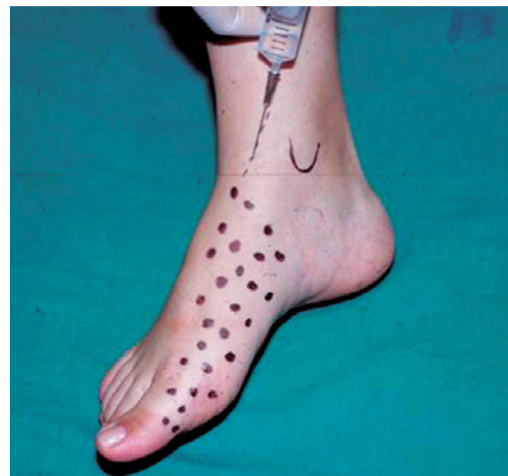

Figure 2 | Sensitive area of the saphenous nerve (Source: Author's personal archive).

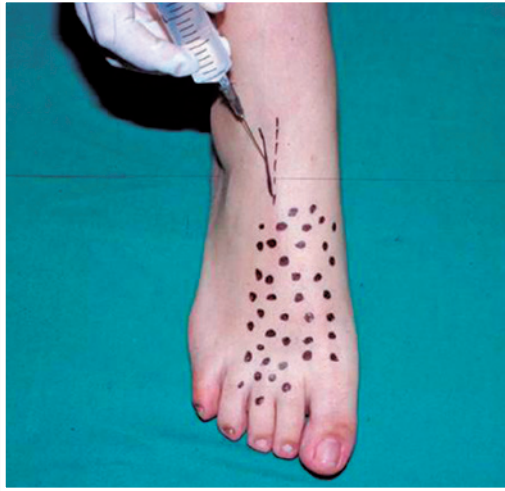


Figure 3 | Sensitive area of the superficial peroneal nerve (Source: Author's personal archive).

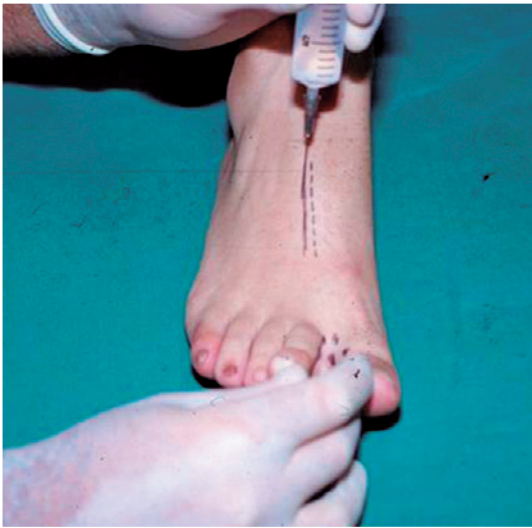

Figure 4 | Sensitive area of the deep peroneal nerve (Source: Author's personal archive).

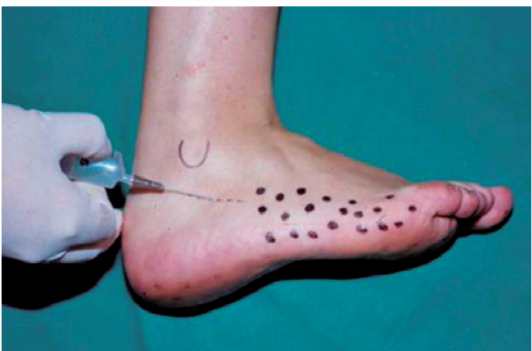

Figure 5 | Sensitive area of the sural nerve (Source: Author's personal archive).

All the patients were hospitalized for 48 hours after the surgical procedure. We collected the pain intensity data through the Visual Analogue Scale⁽⁹⁾ in the immediate postoperative period (considered six hours after the end of the procedure), on the first postoperative day (24 hours after the end of the procedure), and on the second day (considered 48 hours after the procedure). No type of postoperative scheduled analgesia was prescribed. After the onset of pain, its intensity was identified by the visual analogue scale, and only 2mg of intravenous dipyron was given intravenously. No centrally acting analgesic medication such as opioids or benzodiazepines was used.

In addition, we recorded data on time of onset of pain in hours after the end of surgery and whether the first night of sleep after the procedure was considered comfortable for the patient or not.

The statistical analysis was performed through the Statistical Package for Social Sciences (SPSS, Inc., Chicago, IL) version 23.0. The mean, median, standard deviation, maximum and minimum were applied to the numerical variables, while we used descriptive statistics for the nominal variables.

RESULTS

A total of 30 patients participated in the study, amounting to 32 feet (Table 1). All participants completed the questionnaire responses without loss to follow-up.

Table 1 | Characteristics of the participants

	Frequency	Percentage
Smoker		
No	30	100%
Yes	0	0%
Alcoholism		
No	29	97%
Yes	1	3%
Diabetes		
No	28	93%
Yes	2	7%
Sex		
Male	12	40%
Female	18	60%
Worker		
Active	19	63%
Retired	11	37%

(Source: SAME HSPE).

Table 2 | Evaluation of pain intensity by the Visual Analogue Scale

Study participants	Immediate postoperative pain intensity	Pain intensity on first postoperative day	Pain intensity on second postoperative day	Time from onset of pain (hours)
Mean	2.94	3.81	3.00	14.50
Standard deviation	2.382	2.250	2.272	5.412
Median	2.00	4.00	3.00	14.50
Variation	7	9	8	24

(Source: SAME HSPE).

The surgical procedures were performed on the right side in 20 feet (62%) and on the left side in 12 feet (38%). In the anatomical region of the surgery, most were located in the ankle (47%), then in the forefoot (44%) and hindfoot (9%).

The patients had a mean score on the Visual Analog Pain Scale of 2.94 in the immediate postoperative period. For the first postoperative day, the mean was 3.81 while on the second postoperative day the mean was 3.00. In the analgesia time values, the mean of the group was 14.50 hours for the onset of pain after the end of the procedure (Table 2).

The group had 26 participants (87%) who reported the first night of sleep after the surgical procedure as being comfortable.

DISCUSSION

The anesthetic block performed in the study was based on the technique described by Sarrafian et al. in 1983⁽¹⁰⁾. The sequence described by the authors was altered in the saphenous nerve block, when the anesthetic was infiltrated in the approximate region of two centimeters anterior to the medial malleolus.

Peripheral nerve block in the ankle region is a procedure considered safe, simple, and effective for anesthesia in the foot and ankle, enabling optimal control of pain in the postoperative period and in early rehabilitation⁽¹¹⁾.

In the patients from the case series, the mean immediate postoperative (six hours after surgery) pain was less than three, and this result showed that the block helped to control pain safely and effectively.

The peripheral block anesthesia time in the study by Mineo et al. was considered long lasting with the use of bupivacaine, with mean analgesia of 17 hours; in this way the patient was able to benefit from the effect while still in hospital⁽¹²⁾.

The mean postoperative analgesia time after a spinal anesthesia is around 4 to 6 hours. In our study, we also

obtained a prolonged postoperative analgesia time averaging 14.50 hours. This value corroborates the use of the peripheral ankle block for prolonged, long-lasting analgesia, allowing early patient rehabilitation.

Another important factor employed in the study was the use of ropivacaine as this is a safe anesthetic, which provides a sensory blockade similar to bupivacaine, but with less motor blockade⁽¹³⁾, enabling earlier rehabilitation.

Most participants felt that they had had a comfortable night's sleep. These data can be found in studies that demonstrated diminished use of analgesics and greater control of pain after peripheral nerve block⁽¹⁴⁾.

CONCLUSION

The study of this case series demonstrated that peripheral nerve block in the ankle and foot region maintained a low mean on the Visual Analogue Scale in the immediate postoperative period and on the first and second postoperative days, prolonging analgesia and, therefore, making it possible to maximize postoperative physiotherapy. We also concluded that most of the patients who were given the nerve block had a more comfortable first night's sleep.

REFERENCES

1. Hamilton PD, Pearce CJ, Pinney SJ, Calder JD. Sciatic nerve blockade: a survey of orthopaedic foot and ankle specialists in North America and the United Kingdom. *Foot Ankle Int.* 2009; 30(12):1196-201.
2. Provenzano DA, Viscusi ER, Adams SB, Jr., Kerner MB, Torjman MC, Abidi NA. Safety and efficacy of the popliteal fossa nerve block when utilized for foot and ankle surgery. *Foot Ankle Int.* 2002;23(5):394-9.
3. Needoff M, Radford P, Costigan P. Local anesthesia for postoperative pain relief after foot surgery: a prospective clinical trial. *Foot Ankle Int.* 1995;16(1):11-3.
4. McQuay HJ, Carroll D, Moore RA. Postoperative orthopaedic pain—the effect of opiate premedication and local anaesthetic blocks. *Pain.* 1988;33(3):291-5.
5. McCartney CJ, Brull R, Chan VW, Katz J, Abbas S, Graham B, et al. Early but no long-term benefit of regional compared with general anesthesia for ambulatory hand surgery. *Anesthesiology.* 2004; 101(2):461-7.
6. Collins L, Halwani A, Vaghadia H. Impact of a regional anesthesia analgesia program for outpatient foot surgery. *Can J Anaesth.* 1999; 46(9):840-5.

7. Chelly JE, Greger J, Al Samsam T, Gebhard R, Masson M, Matuszczak M, et al. Reduction of operating and recovery room times and overnight hospital stays with interscalene blocks as sole anesthetic technique for rotator cuff surgery. *Minerva Anesthesiol.* 2001;67(9):613-9.
8. Beskin JL, Baxter DE. Regional anesthesia for ambulatory foot and ankle surgery. *Orthopedics.* 1987;10(1):109-11.
9. Downie WW, Leatham PA, Rhind VM, Wright V, Branco JA, Anderson JA. Studies with pain rating scales. *Ann Rheum Dis.* 1978;37(4):378-81.
10. Sarrafian SK, Ibrahim IN, Breihan JH. Ankle-foot peripheral nerve block for mid and forefoot surgery. *Foot Ankle.* 1983;4(2):86-90.
11. Dhukaram V SKC. Nerve blocks in foot and ankle surgery. *Foot Ankle Surg.* 2004;10(1):1-3.
12. Mineo R, Sharrock NE. Venous levels of lidocaine and bupivacaine after midtarsal ankle block. *Reg Anesth.* 1992;17(1):47-9.
13. McClure JH. Ropivacaine. *Br J Anaesth.* 1996;76(2):300-7.
14. Kullenberg B TC, Resch S. Ankle nerve block-perioperative pain relief in surgery of the forefoot. *The Foot.* 2006;16(3):135-7.