

# Intermetatarsal coalition: case report

## Coalizão intermetatarsal: relato de caso

Henrique Mansur<sup>1</sup>, César Barbosa Gonçalves<sup>2</sup>, Thiago Coelho Lima<sup>3</sup>, Isnar Castro Júnior<sup>4</sup>

### ABSTRACT

Coalition is an abnormal bone fusion that most commonly occurs between the tarsals. Coalition in the forefoot is a rare pathology, especially between metatarsals. The authors present a case of a female patient with coalition of the 4th and 5th metatarsals of the left foot, which was treated surgically through resection of the osseous bar and osteotomy with dorsal subtraction wedge in the 5th metatarsal, with resolution of the symptoms and correction of the deformity. The relevance of the case lies in the fact that this deformity is little described in the worldwide literature, and has not yet been described in the national literature.

### Keywords:

Tarsal coalition; Tarsal Bones/surgery; Forefoot; Synostosis; Osteotomy

### RESUMO

Coalizão é uma união anormal entre ossos que ocorre mais comumente entre os ossos do tarso. A coalizão no antepé é uma patologia rara, especialmente entre metatarsos. Os autores apresentam caso de paciente do sexo feminino com coalizão entre o 4º e 5º metatarsos do pé esquerdo, que foi tratada cirurgicamente através de ressecção da barra óssea e osteotomia com cunha de subtração dorsal no 5º metatarso, com resolução dos sintomas e correção da deformidade. A relevância do caso reside no fato de se tratar de uma deformidade pouco descrita na literatura mundial e ainda não descrita na literatura nacional.

### Descritores:

Coalizão Tarsal; Ossos do tarso/cirurgia; Antepé; Sinostose; Osteotomia

### INTRODUCTION

Coalition is an abnormality defined as a union between two bones that can be osseous, cartilaginous, or fibrous, and occur in any part of the body. It is more common between the tarsal bones and affects approximately 1-2% of the population<sup>(1-4,6-8)</sup>. Coalition between bones in the forefoot is a rare pathology, especially between metatarsals, so there are few case reports in the global literature<sup>(1,3-6)</sup>. This union between the metatarsals can cause stiffness in the forefoot and alteration of the metatarsal formula, entailing uneven distribution of weight upon the metatarsals, which causes pain, difficulty walking, and calluses.

We present a case of a skeletally mature patient with unilateral coalition between the 4<sup>th</sup> and 5<sup>th</sup> metatarsals of the left foot, manifestation of pain and deformity in the forefoot, who underwent surgical treatment with a good outcome.

### CASE REPORT

A 50-year-old female patient complaining of chronic pain and deformity in the left foot, without reports of previous trauma, infection, or relatives with syndromes or similar deformity. In clinical terms, the patient presents with

<sup>1</sup> Orthopedist at Hospital da Força Aérea de Brasília, Brasília, DF, Pursuing a Master's degree at Universidade Federal do Estado do Rio de Janeiro, Rio de Janeiro, RJ.

<sup>2</sup> Orthopedist at Hospital Naval Marcílio Dias, Rio de Janeiro, RJ.

<sup>3</sup> Pursuing Master's degree at Faculdade de Medicina de Ribeirão Preto, Ribeirão Preto, SP.

<sup>4</sup> Orthopedist, Head of the Foot and Ankle Surgery Group of INTO, Rio de Janeiro, RJ.

### Correspondence to:

Henrique Mansur  
Área Militar do Aeroporto Internacional de Brasília  
Zip Code: 71607-900 – Lago Sul, Brasília, DF, Brazil  
E-mail: henrimansur@globo.com

### Conflict of interest:

none reported.

### Source of funding:

none reported.

### Received on:

February 21, 2017

### Accepted on:

May 15, 2017

prominence, pain, and plantar callus under the heads of the second and fifth metatarsals, and diminished mobility of the lateral rays (Figures 1A and B).

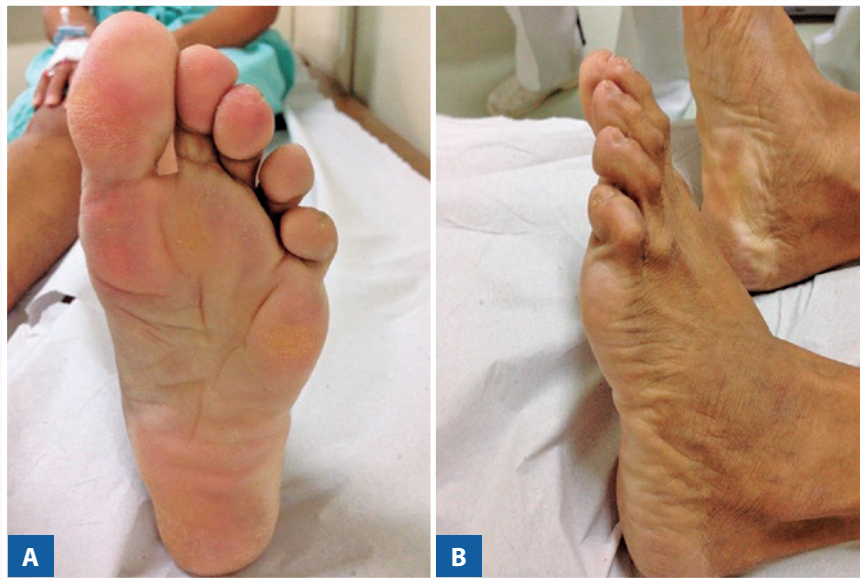The plain radiographs taken with support showed a metatarsal coalition, with an osseous bar between the fourth and fifth metatarsals in the diaphyseal region of the left foot. Compared with the right foot, there was shortening, enlargement, and plantar deviation of the 5<sup>th</sup> metatarsal head (Figures 2A and B).

### Surgical technique

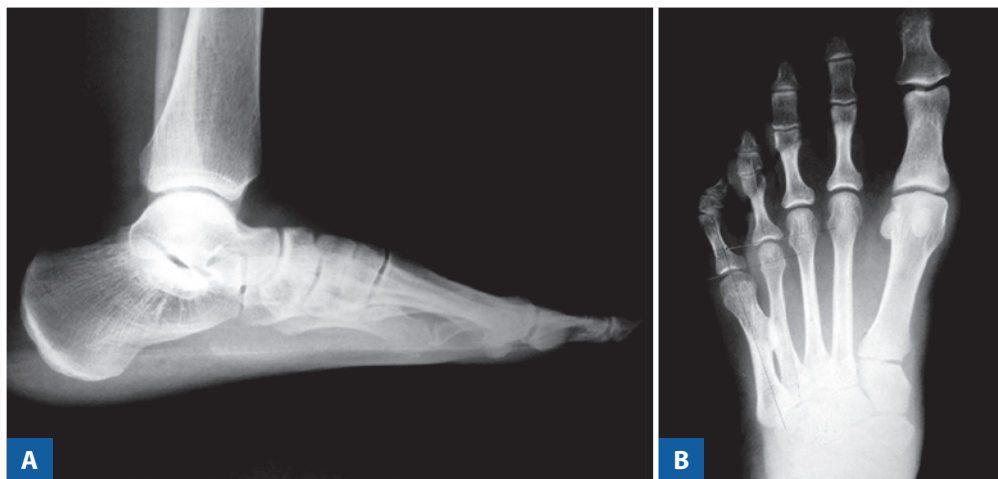
The surgery was performed with the patient in dorsal decubitus, under spinal anesthesia and with pneumatic

cuff installed at the top of the left thigh. A dorsal approach was made on the diaphysis of the fifth metatarsal, with resection of the osseous bar and osteotomy with dorsal subtraction wedge in the distal metaphyseal region using a bone saw, and fixation of the osteotomy in the plate positioning, mini fragments and five screws (Figures 3A and B).

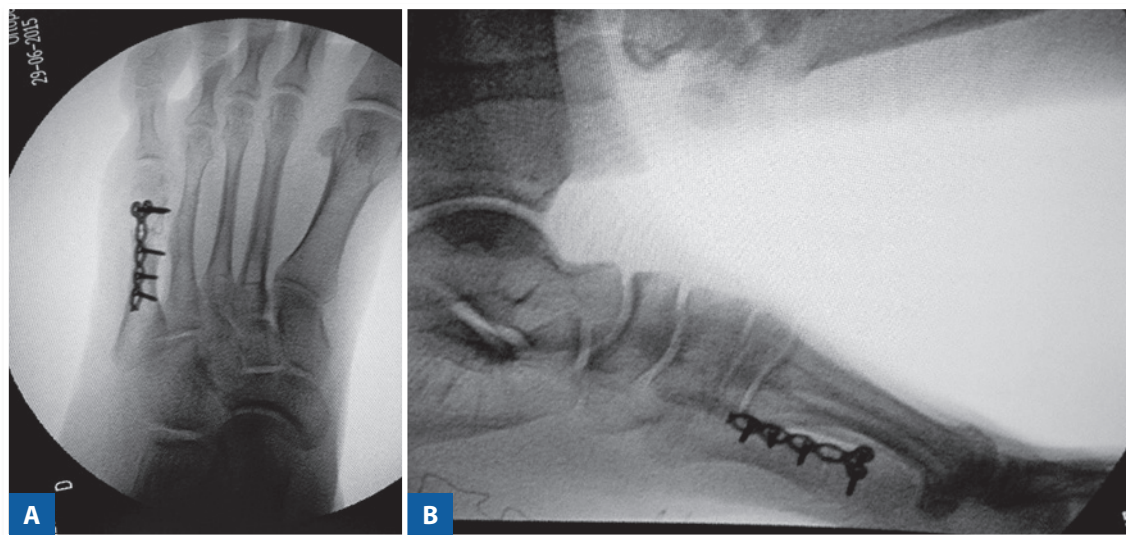
The patient was discharged after 24 hours wearing a cast boot without support. The outpatient return visit took place after one week for Barouk shoe fitting. The stitches were removed at three weeks, and the patient was authorized to start bearing weight in the sixth week following control radiographs confirming osteotomy consolidation (Figures 4A, B and C). At twelve months, the patient retur-



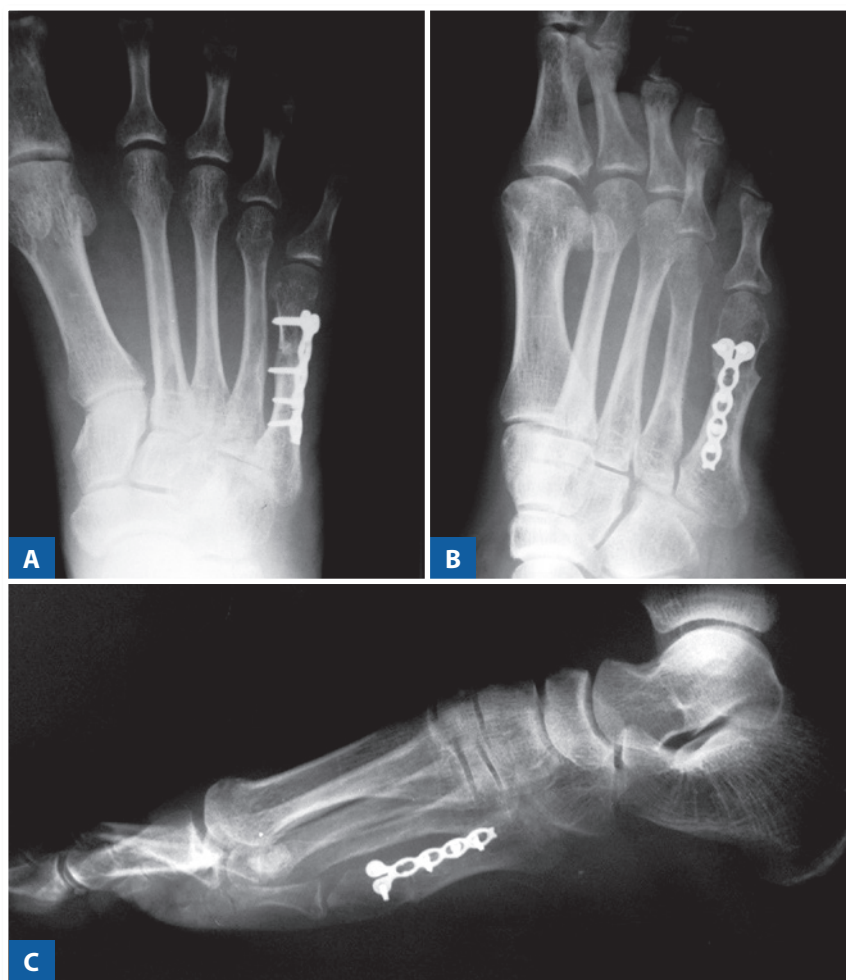**Figure 1** | Preoperative physical examination.



**Figure 2** | Preoperative radiographs.



**Figure 3 |** Preoperative control following resection of the coalition and osteotomy of the 5<sup>th</sup> metatarsal bone.



**Figure 4 |** Late postoperative radiographs of consolidated osteotomy and non-recurrence.

ned without complaints of pain and with no plantar calluses or areas of hyperpressure (Figures 5A, B and C). An AOFAS score was applied which totaled 100 points.

This study was carried out after approval by the Institutional Review Board of the sponsoring Institution.

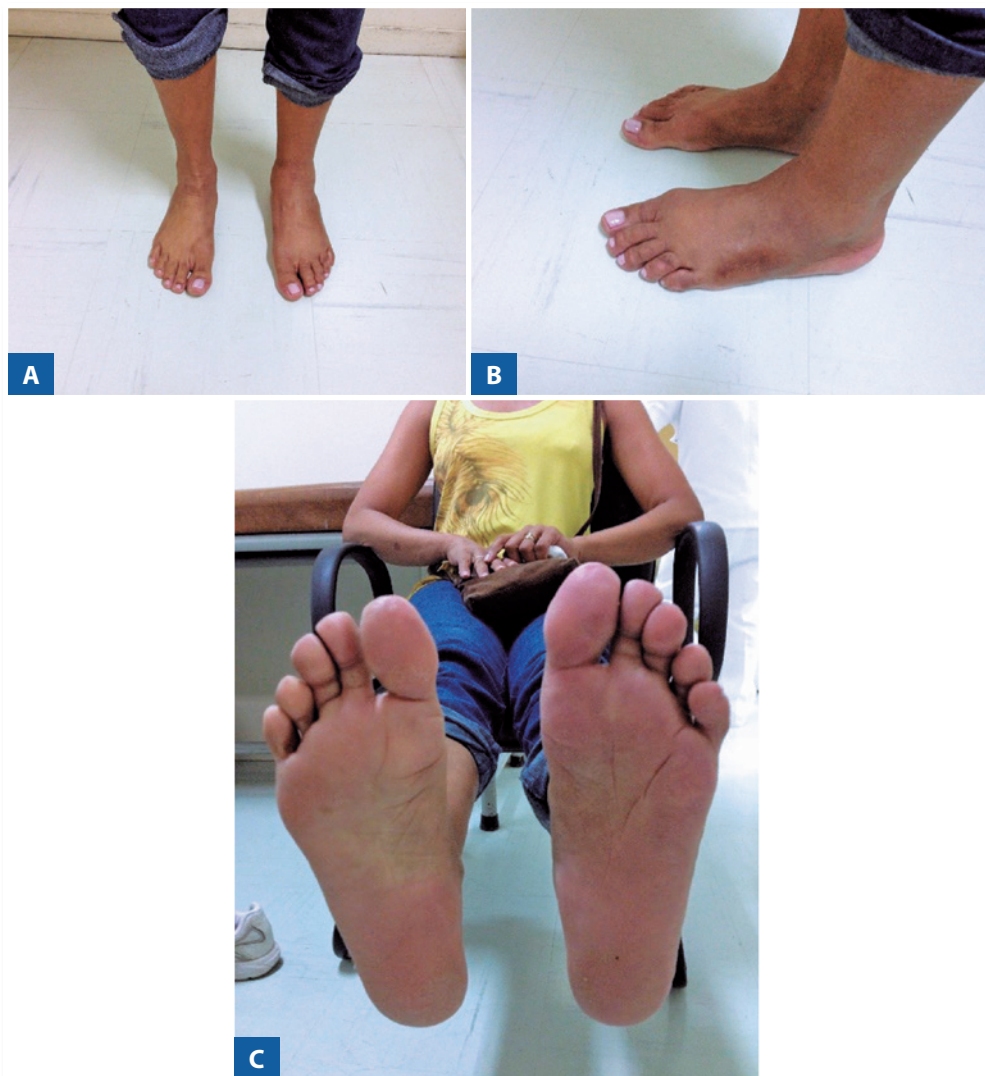## DISCUSSION

Histologically, coalitions can be classified as fibrous (syndesmosis), cartilaginous (synchondrosis), osseous (synostosis), as in the case described, or a combination of the three types<sup>(8)</sup>.

According to Perman and Wertheimer<sup>(6,9)</sup>, coalitions may be of congenital or acquired etiology. Congenital coalitions result from failure in the differentiation of the me-

senchymal embryonic tissue, evidenced by the presence of osseous bars in fetuses<sup>(1,4,7,8)</sup>. The acquired bars were described in cases of trauma, infections, and as being of iatrogenic origin in the postoperative period<sup>(1,9)</sup>.

Congenital osseous coalitions in the foot are relatively uncommon, present in 1-2% of the population. However, since they are asymptomatic in most people, the true prevalence is probably higher<sup>(4,8)</sup>. The most common bars that are extensively described in the literature occur between the tarsal bones, typically in children, with calcaneonavicular and talocalcaneal bars being the most common, accounting for more than 90% of cases<sup>(1,3,6,8)</sup>. Other less common bars include the calcaneocuboid, cuneonavicular, cuboid-navicular<sup>(2)</sup> and metatarsocuboid types<sup>(9)</sup>. Intermetatarsal coalitions are rare, so there are few cases described in the global



**Figure 5** | Postoperative appearance with correction of the deformities and calluses.

literature, and most commonly occur between the 1<sup>st</sup> and 2<sup>nd</sup>(3-5) or 4<sup>th</sup> and 5<sup>th</sup> metatarsals(6-8), with one case between 3<sup>rd</sup> and 4<sup>th</sup> metatarsals(1), and two bilateral cases(1,5). They may be isolated deformities or be associated with inherited syndromes such as Pfeiffer-Kapferrer, Cenani-Lenz syndactyly, Townes-Brocks syndrome and Apert syndrome(6,7,10).

Genetic studies in tarsal coalitions suggest an autosomal dominant inheritance pattern with bilateral occurrence in more than 85% of patients(4). In metatarsal bars, genetic inheritance is not known(3).

Proper weight distribution during gait requires a normal relationship between the metatarsals, occurring gradually over their heads, which requires correct alignment and mobility in the sagittal plane(1,3,4). In our patient, the osseous bar and fixed plantar deviation of the 5<sup>th</sup> metatarsal altered the normal biomechanics of the foot, causing overload in the lateral rays, which produced calluses and metatarsalgia.

Treatment of metatarsal coalition may be conservative or surgical. According to Córdoba-Fernández(8), as it refers to a rare pathology, each case should be treated separately and according to the patient's symptoms and associated deformities, aiming to reestablish the metatarsal formula and, thus, restore the biomechanics and the weight distribution of the forefoot(3,5). According to Mohammed(5), the presence of coalition of the 4<sup>th</sup> and 5<sup>th</sup> metatarsals is less severe functionally, but appears later in life, thus entailing poorer functional results since patients may manifest degenerative alterations at the time of diagnosis.

In the case presented here, as the patient was skeletally mature with established deformity and important metatarsalgia, we opted for surgical treatment. In addition to resection of the osseous bar, which allows mobility of the lateral column of the foot, osteotomy was performed with dorsal closure wedge to correct the plantar deviation of the 5<sup>th</sup> metatarsus, redistribute the weight and reestablish normal foot biomechanics. These results were confirmed by the resolution of symptoms and the disappearance of the calluses under the heads of the 2<sup>nd</sup> and 5<sup>th</sup> metatarsals. Some surgeons(1) use bone wax, fat or muscle interposition to cover the coalition area, preventing its recurrence. However, in our report and in most of the cases described(4,5,7,8), resection alone was performed, without recurrence. The use of a tech-

nique to cover the bar was not described in the only reported case(6), but this was an 8-year-old child with recurrence after 2 years. In the follow-up to this case, conservative treatment was performed for 1 year, with good progress. The authors emphasize that surgical treatment should preferably be performed after skeletal maturity.

The importance of the case presented here is due to the rarity of metatarsal coalition and it should be remembered among the differential diagnoses of metatarsalgia. In addition, it serves as an aid and option for the treatment of new cases, since studies with a higher level of evidence are hard to carry out as the deformity is so uncommon.

## CONCLUSION

Osseous bar resection associated with corrective osteotomy of the plantar flexion deformity redistributes the weight on the forefoot, thus correcting the deformity, plantar callus and metatarsalgia.

## REFERENCES

1. Dunn KW, Giordano AR. Surgical resection of bilateral coalition of the third and fourth metatarsals: a case report. *J Foot Ankle Surg.* 2016;55(5):1038-42.
2. Prado MP, Mendes AAM, Olivi R, Amodio DT. Coalizão tarsal cuboide-navicular. *Rev Bras Ortop.* 2010;45(5):497-9.
3. Yang C, Goukd ES, Mason M. Metatarsal coalition complicated by interdigital neuroma. *Radiol Case Rep.* 2016;4(2):286.
4. Novak EJ, Elzik M, Diab M. Symptomatic coalition between the first and second metatarsals in a child. *Orthopedics.* 2008;31(12):1241.
5. Mohammed F, Hoford R, Naraynsingh V, Maharaj D, Ali T. A rare case of bilateral congenital metatarsal synostosis. *Foot.* 2011;11(3):163-5.
6. Yun SH, Drampalos E, Shareef S, Sinha S, Bramley. Distal metatarsal coalition: A rare case report. *Int J Surg Case Rep.* 2015;8C:182-4.
7. Aspros D, Ananda-Rajan E, JNR ZK, Rajan R. Distal metatarsal synostosis: A case report. *Foot.* 2014; 24(3):153-6.
8. Córdoba-Fernández A, Rayo-Rosado R, López-García D, Juárez-Jimenez JM. A rare intermetatarsal coalition with rigid fifth metatarsal deformity and symptomatic plantar lesion. *J Foot Ankle Surg.* 2016;55(5):1091-6.
9. Kobayashi H, Kageyama Y, Shido Y. Isolated fifth metatarsocuboid coalition: a case report. *J Foot Ankle Surg.* 2015;54(4):734-8.
10. Mendioroz J, Fernández-Toral, Suárez E, López-Grondona, Kjaer KW, et al. Sensorineural deafness, abnormal genitalia, synostosis of metacarpals and metatarsals 4 and 5, and mental retardation: description of a second patient and exclusion of HOXD13. *Am J Med Genet A.* 2005;135(2):211-3.