

## Original Article

# Preliminary short-term results of ankle arthroplasty with the Taric<sup>®</sup> prosthesis

Waldo Campos Lisboa Neto<sup>1</sup> , Marco Túlio Costa<sup>1</sup> , Ricardo Cardenuto Ferreira<sup>1</sup> 

1. Santa Casa de Misericórdia de São Paulo, São Paulo, SP, Brazil.

## ABSTRACT

**Objective:** Present the clinical and functional outcome of the first five ankle arthroplasties performed in our department.

**Methods:** Five patients (five feet) with secondary arthrosis of the ankle underwent ankle arthroplasty with the Taric<sup>®</sup> prosthesis. Average age at the time of surgery was 42 years. Follow-up time averaged 43 months. We recorded the immediate postoperative complications. For clinical evaluation we used the VAS pain scale, the AOFAS hindfoot and ankle scale, and the Foot Function Index. We measured the leg-foot range of motion. On the radiographs, we measured the alpha, beta, and gamma angles as well as sagittal balance. We sought to identify the presence of posterior osteophytes (bone spurs).

**Results:** We observed a case of medial malleolus fracture and a case of superficial suture dehiscence. In two cases, we considered the final outcome to be poor. The mean VAS of pain before surgery was 8.8 points while the postoperative score was 5.4 points. On the AOFAS scale, the average preoperative score was 52 points and the score at final evaluation, 70 points. We noticed a 10° increase in leg-foot range of motion.

**Conclusion:** The assessment of the first patients undergoing ankle arthroplasty with the Taric<sup>®</sup> prosthesis yielded outcomes considered poor in 40% of cases. However, in those with an outcome considered satisfactory, there was an improvement in pain and an increase in leg-foot range of motion. In all patients, we noticed the formation of a posterior osteophyte alongside the posterior cortex of the distal tibia.

**Level of Evidence IV; Therapeutic Studies; Case Series.**

**Keywords:** Ankle; Osteoarthritis; Surgery; Arthroplasty, Replacement, Ankle.

## Introduction

Symptomatic ankle arthrosis causes a significant decline in the quality of life of patients<sup>(1)</sup>. The advent of ankle arthroplasty brought new expectations, but the real benefits and long-term outcomes are still being studied<sup>(1)</sup>. Although there is still uncertainty about which procedure leads to better outcomes, whether it is arthrodesis or arthroplasty, the latter has increased in popularity, with a large number of recent publications<sup>(1-6)</sup>. However, the risks and potential complications still persist<sup>(7-10)</sup>, and adequate knowledge of the procedure may help us avoid them.

The aim of this work is to present the preliminary results of the first five ankle arthroplasties performed in our department and to identify the factors of good outcomes and the main complications to date.

## Methods

This study was approved by the Institutional Review Board and registered on the Plataforma Brazil database under CAAE (Ethics Evaluation Submission Certificate) number: 19234719.2.0000.5479.

Study performed at the Santa Casa de Misericórdia de São Paulo, São Paulo, SP, Brazil.

**Correspondence:** Marco Túlio Costa. 112 Cesário Mota Junior St., Pavilhão Fernandinho Simonsen, Vila Buarque, São Paulo, SP, Brazil, Zip Code: 01221-010. **E-mail:** marcotulio9@me.com. **Conflicts of interest:** none. **Source of funding:** none. **Date received:** March 27, 2020. **Date accepted:** April 01, 2020. **Online:** April 30, 2020.

**How to cite this article:** Lisboa Neto WC, Costa MT, Ferreira RC. Preliminary short-term results of ankle arthroplasty with the Taric<sup>®</sup> prosthesis. *J Foot Ankle.* 2020;14(1):29-35.



This is a retrospective observational study that met the requirements in relation to human and animal rights.

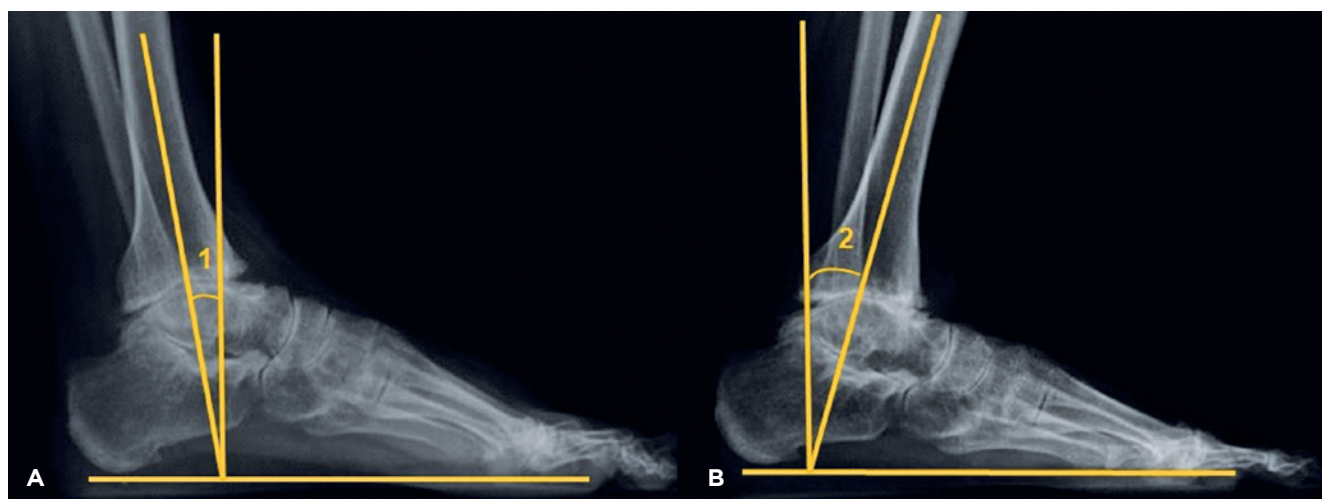
Between May 2015 and April 2016, five patients (five extremities), all female, underwent surgical treatment of ankle osteoarthritis with arthroplasty of this joint, performed by the Foot and Ankle Surgery Group of our hospital. Taric® prostheses (Implantcast) were used in all cases. The mean age at the time of surgery was 42 years (ranging from 35 to 49 years). The follow-up time ranged from 37 to 48 months, averaging 43 months. Body mass index (BMI) ranged from 28.1 to 34, indicating that patients were in the range between overweight and obesity. In all patients, ankle arthrosis was considered secondary: three patients had a diagnosis of rheumatoid arthritis, one patient a history of osteochondral lesion of the talus, and another, a history of ankle fracture. Patients diagnosed with rheumatoid arthritis were being regularly monitored by the rheumatologist, with the disease controlled and using immunosuppressive medication, which was suspended at the time of surgery<sup>(7)</sup>.

For functional clinical assessment, in addition to the orthopedic physical examination, we also used clinical photographs, the visual analogue scale of pain (VAS)<sup>(11,12)</sup>, and the American Orthopaedic Foot and Ankle Society (AOFAS) ankle and hindfoot scale<sup>(13)</sup>, and compared data obtained in the preoperative period with data obtained in the last outpatient appointment. In addition, the Foot Function Index (FFI)<sup>(14)</sup> was used in the postoperative period (the FFI was not collected in the preoperative period). To assess joint range of motion, we chose to measure movement between the leg and the foot, knowing that this movement involves other hindfoot joints. We asked the patient to perform as much plantar

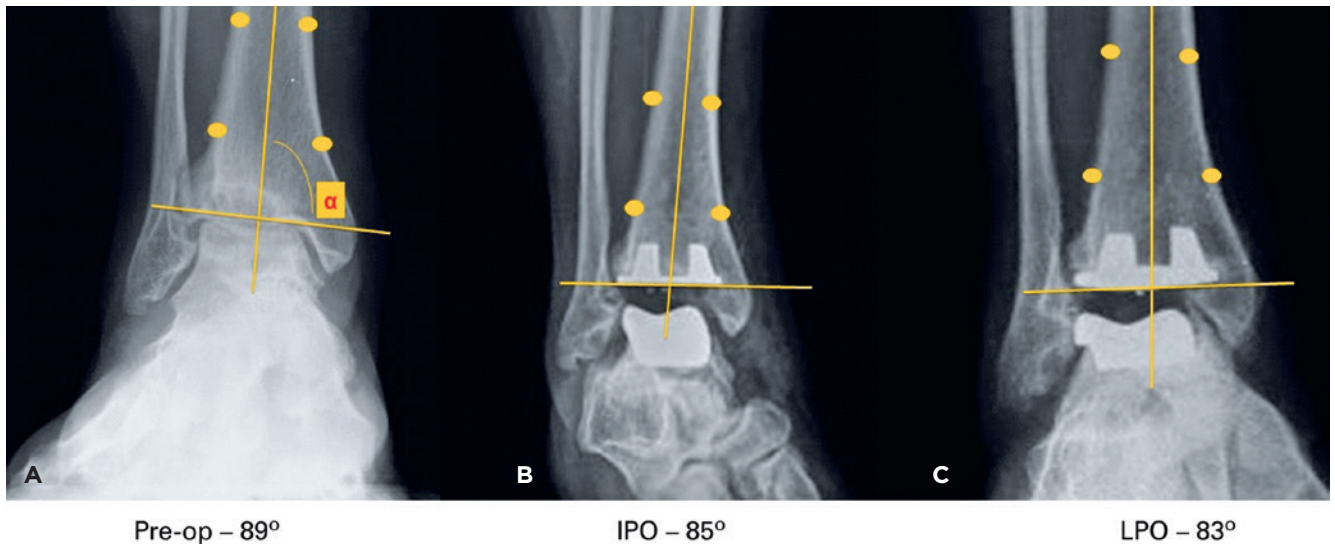
flexion movement as possible, followed by maximum dorsiflexion, while maintaining the sole of their foot on the ground at all times. The positions obtained were documented with photography and lateral radiography of the ankle and foot (in the upright position). By measuring the longitudinal axis of the distal tibia with the position of the ground, we obtain the range of motion between the ankle and the ground (leg-foot movement) (Figure 1).

We measured radiographic data, both pre- and postoperatively. We used the alpha angle to assess valgus and varus deformity of the joint surface of the distal “tibia” on the anteroposterior radiograph with internal rotation of 20 degrees<sup>(15-18)</sup> (Figure 2). In the lateral radiograph, we evaluated tibial component inclination using the beta angle<sup>(15-18)</sup> (Figure 3). To evaluate the positioning of the talar component, also in the lateral radiograph, we measured the gamma angle<sup>(15-17)</sup>. The variation of these angles during outpatient follow-up was considered a sign of component movement and a high risk of loosening or sinking.

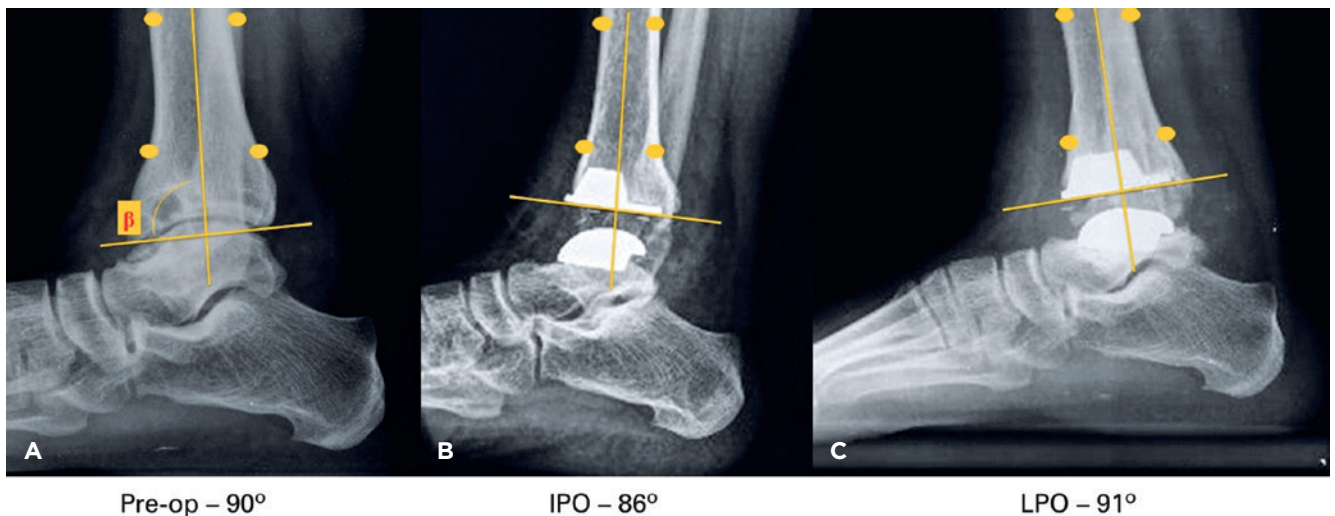
In addition to the abovementioned angles, we also evaluated sagittal balance, which reveals the offset of the ankle joint (anteroposterior position of the talus in relation to the long axis of the tibia). This enabled us to observe whether there were cases with ankle subluxation<sup>(19)</sup> (Figure 4). Sagittal balance is measured on the lateral radiograph of the ankle. In this radiograph, we also evaluated the coverage of the posterior cortex of the distal tibia by the tibial component. According to the manufacturer of this prosthesis model, this coverage (extension of the tibial component to the posterior cortical limit of the distal tibia) is not necessary. We also examined the radiographs for signs of periprosthetic



**Figure 1.** Method for radiographic measurement of ankle range of motion. In figure “A” we can see angle “1”, which represents maximum plantar flexion, measured through the difference between the angle formed by the long axis of the tibia with the ground, and the right angle (neutral) of 90° with the ground. In figure “B” we can see angle “2”, which represents maximum dorsiflexion, measured through the difference between the angle formed by the long axis of the tibia with the ground, and the right angle (neutral) of 90° with the ground. The sum of the two angles (1 + 2) represents the total range of motion of the ankle being assessed.



**Figure 2.** Measurement of the alpha angle “ $\alpha$ ”. Measured on the radiograph in the frontal view with medial rotation of 20°, through the medial angle formed by the long axis of the tibia and the distal joint surface of the tibia/joint surface of the tibial component. The figure shows the values of one of the cases assessed in the preoperative (A), immediate postoperative (B), and late postoperative (C) periods.

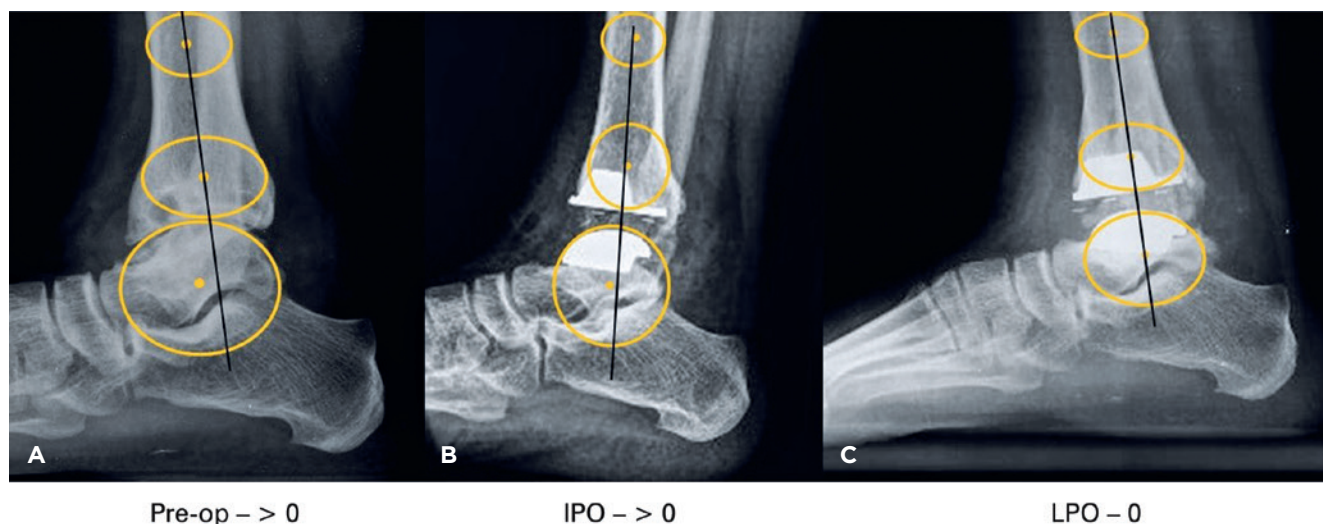


**Figure 3.** Measurement of the beta angle “ $\beta$ ” on the lateral radiograph. Anterior angle formed by the long axis of the tibia and the distal joint surface of the tibia/joint surface of the tibial component. The figure shows the values of one of the cases assessed in the preoperative (A), immediate postoperative (B) and late postoperative (C) periods.

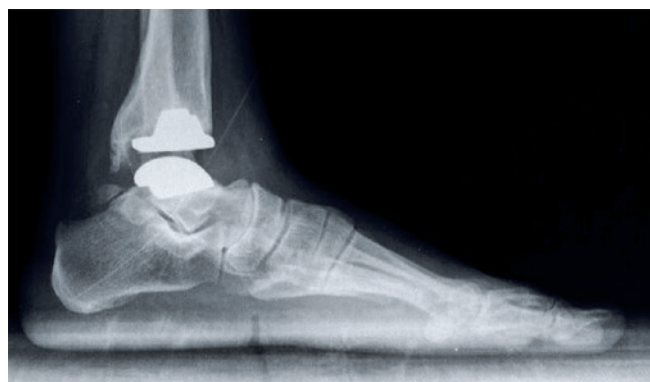radiolucency, which indicates loosening of the component, presence of intraosseous cysts and formation of osteophytes in the distal tibia (Figure 5).

The access route used was the anterior approach, between the extensor hallucis longus and the tibialis anterior, described for this surgery. The joint surfaces of both the distal tibia and the talus were prepared according to the recommendations of the standard implant technique. Stability and range

of motion were tested with the test prosthesis. If these were considered satisfactory, the final prosthesis was implanted. Special care was taken in distancing the soft tissues over the course of the surgery, in order to avoid wound healing issues. In a patient with rheumatoid arthritis, there was also arthrosis in the talocalcaneal joint, which was fixed, in the same procedure, with a 6.0 mm cannulated screw inserted from the dorsal to plantar direction (from the talus to the calcaneus), and without removing the talocalcaneal joint cartilage.



**Figure 4.** Evaluation of sagittal balance on the lateral radiograph of the ankle, where there must be alignment between the long axis of the tibia and the center of rotation of the talus. The figure shows the sagittal balance of one of the cases assessed in the preoperative (A), immediate postoperative (B) and late postoperative (C) periods.



**Figure 5.** Posterior osteophyte - Lateral radiograph of the ankle of one of the cases assessed, 37 months after surgery, showing the formation of an osteophyte in the posterior region of the tibia. Despite the ectopic bone formation, the patient had a satisfactory functional outcome and 23° gain in the total range of motion of the ankle.

We also assessed the complications that can occur during surgery, such as malleolus fractures, and the immediate postoperative complications such as suture dehiscence, skin necrosis, exposure of the anterior tibial tendon, superficial and deep infection, and whether there was any relationship between these complications and the final outcome<sup>(7,8)</sup>.

## Results

During surgery, a medial malleolus fracture occurred in one case, treated immediately with fixation using cannulated

screws. Fracture consolidation was achieved. This patient had arthrosis secondary to osteochondral lesion of the talus. We also observed, in one case, suture dehiscence in a patient diagnosed with rheumatoid arthritis who was taking corticosteroids. It was resolved with local dressings alone.

Of the five patients, we observed significant improvement in pain in three cases, in which the outcomes were considered satisfactory. Two patients still reported severe pain at their last return appointment. The average VAS score prior to surgery was 8.8 points (ranging from 8 to 9 points). After the procedure, this mean score was 5.4 points (ranging from 0 to 10), a reduction of 3.4 points. However, considering only the three cases with good outcomes, we noticed a significant improvement in pain. The three patients had a VAS score of nine points in the preoperative period and scores of zero, two and five points postoperatively.

On the AOFAS scale<sup>(13)</sup>, the mean value before surgery was 52 points (ranging from 39 to 66). In the postoperative period, the mean score was 70 points (ranging from 38 to 90). Considering only the three cases with satisfactory outcome, the final result was 85, 85 and 90 points. As regards the Foot Function Index, we found a mean of 40%, ranging from 14% to 68%.

When evaluating the range of motion (ROM) between foot and ankle (leg-foot movement), prior to the surgical procedure, we found a mean value of 31° (ranging from 25° to 35°). In comparison, the mean ROM observed in the postoperative assessment was 41° (ranging from 27° to 58°), a 10° increase. In the cases with outcomes considered satisfactory, there was a gain in the range of this motion (11°, 12° and 23°), while in the cases with outcomes considered unsatisfactory, there was no increase in motion.

The results of the measurement of radiographic parameters are shown in tables 1 to 4. No particularities were observed between these parameters and the final result of the assessment. As regards the gamma angle, there are no values described as normal for this type of implant. Nevertheless, in case number four, we believe that the talar component was poorly positioned and that the 25° angle was high.

**Table 1.** Values obtained in the measurement of the alpha angle ( $\alpha$ ) (coronal inclination) on the preoperative, immediate postoperative, and last outpatient assessment postoperative radiographs.

	$\alpha$ -Preoperative	$\alpha$ -IPO	$\alpha$ -IPO
Case 1	89	85	83
Case 2	88	87	91
Case 3	89	91	92
Case 4	91	89	90
Case 5	85	90	94

**Table 2.** Values obtained in the measurement of the beta angle ( $\beta$ ) (sagittal inclination) on the preoperative, immediate postoperative, and last outpatient assessment postoperative radiographs

	$\beta$ -Preoperative	$\beta$ -IPO	$\beta$ -IPO
Case 1	90	94	91
Case 2	92	92	93
Case 3	95	91	93
Case 4	94	89	90
Case 5	89	85	83

**Table 3.** Values obtained in the measurement of the gamma angle ( $\lambda$ ) (positioning of the talar component) on the preoperative, immediate postoperative, and last outpatient assessment postoperative radiographs.

	$\lambda$ -IPO	$\lambda$ -IPO
Case 1	18	12
Case 2	21	21
Case 3	9	10
Case 4	22	25
Case 5	21	19

**Table 4.** Values obtained in the measurement of sagittal balance on the preoperative, immediate postoperative, and last outpatient assessment postoperative radiographs

Sagittal Balance	Preoperative	IPO	LPO
Case 1	>0	>0	0
Case 2	0	>0	>0
Case 3	0	0	<0
Case 4	0	<0	<0
Case 5	>0	>0	>0

We observed the growth of a posterior osteophyte near the distal tibia, of varying sizes, in all cases; however, none of these were symptomatic.

## Discussion

Despite the small number of cases and the average follow-up time of 43 months, which we consider short in this type of surgery, the publication of this case series is relevant. This is the first article with this prosthesis model published in our country (Brazil). The analysis of outcomes and complications at this time helps to minimize future negative outcomes and to draw a profile where this surgery may be the best choice, besides emphasizing the importance of adequate training before the surgeon undertakes an ankle arthroplasty<sup>(7,20)</sup>.

Fracture of the medial malleolus is a complication described during surgery and in the postoperative period<sup>(6-9,20)</sup>. It can happen during the cutting of bone with the saw, or during the insertion of a particular prosthesis component<sup>(7)</sup>. It appears to decrease as the surgeon's experience with the surgical technique increases, and immediate treatment is advocated following its detection.<sup>7</sup> It occurred in one case, and was fixed during surgery using cannulated screws. Consolidation was achieved.

Surgical wound healing complications are also described<sup>(2,4,6,10,20)</sup>. Small suture dehiscences, small areas of skin necrosis and superficial infection are considered minor complications. Deep necrosis, with exposure of a tendon or one of the prosthesis components, and deep infections are major complications that can affect the treatment outcome<sup>(4,6,7)</sup>. We observed only one case of suture dehiscence, which was adequately treated with a series of dressings. This patient had arthrosis secondary to rheumatoid arthritis, a fact that may increase the incidence of this complication. For this reason, we recommend, as do other authors<sup>(4,9,18)</sup>, greater care in manipulation and distancing of soft tissues during surgery on patients diagnosed with rheumatoid arthritis.

The major advantage of arthroplasty over ankle arthrodesis lies in maintaining joint mobility<sup>(18,20)</sup>. Range of motion after arthroplasty varies in the literature<sup>(10,17,20,21)</sup>. Accurate measurement of ankle range of motion is the subject of studies<sup>(22,23)</sup>. Coetzee and Castro<sup>(23)</sup> published a method that assesses isolated ankle movement following arthroplasty. Thornton et al.<sup>(22)</sup> believe that the movement between leg and foot is easier to measure and can be used in the assessment of both patients with arthrosis, and those undergoing arthroplasty or ankle arthrodesis. We chose to assess leg-foot movement, with the same parameters described by Thornton, yet using weight-bearing radiographs in the lateral view, with maximum plantar flexion and maximum ankle extension. We hope to thus obtain a measure that is reliable and reproducible both preoperatively and postoperatively. In the cases evaluated, there was a 10 degree gain in the range of motion, which we consider important.

We also observed pain relief, but wish to emphasize that it was not complete. Valderrabano et al.<sup>(17)</sup> observed total pain

relief in 54% of their patients. Gougoulias et al.<sup>(10)</sup> stressed that residual pain is common after ankle arthroplasty. In our small case series, there was an improvement in the VAS scale in cases considered satisfactory, and only one patient was completely pain free.

Although the indication for total ankle arthroplasty in patients diagnosed with rheumatoid arthritis is discussed, some<sup>(4)</sup> argue that in patients with good bone stock, whose disease is under control and who do not have major ankle and hindfoot deformity, arthroplasty can avoid accelerated articular degeneration of neighboring joints, which usually happens after ankle arthrodesis<sup>(2,9)</sup>. Adequate preoperative preparation must be observed<sup>(2,9,18)</sup>. In our study, the prosthesis was implanted in three patients diagnosed with rheumatoid arthritis. We considered one patient to have a good outcome, another an acceptable outcome, and one a poor outcome. In one case (good outcome), due to concomitant subtalar arthrosis, we performed the percutaneous fixation of this joint without removing joint cartilage. We believe that in these cases, due to rheumatoid arthritis, spontaneous joint fusion should occur. This enables us to avoid a new approach. The only case in which we observed delayed wound healing also occurred in a patient with rheumatoid arthritis. Although complete healing occurs after 4 weeks and we can use only local dressings changed weekly, we recommend greater care in the manipulation and distancing of soft tissues in these patients.

To measure the loosening of the prosthesis components, we used radiographic measurements. Supporting the tibial component in the posterior tibial cortex could prevent arthroplasty failure due to loosening and sinking of the tibial component<sup>(1)</sup>. However, in the surgical technique of the prosthesis adopted in this study, there is no such recommendation. We did not observe sinking and loosening. A minor accommodation of the components is to be expected. The angle described for assessing the talar component is the gamma angle. Valderrabano et al.<sup>(17)</sup> found a mean for this angle of 17.2 degrees in the STAR® prosthesis. Cadden found a mean of 20 degrees in the full prosthesis<sup>(5)</sup>, while Le et al.<sup>(16)</sup> recorded values of 22 degrees when evaluating two types of implant. We did not find values described for the Taric® prosthesis in the literature. In this study, assessing the four cases in which we believe that the component was implanted correctly, we recorded a mean value of 17 degrees for the gamma angle.


Poor positioning of the implant can also have a detrimental effect on the final outcome<sup>(8,19)</sup>. If the implant was poorly positioned, the outcome was considered poor. This focuses on the need for adequate surgeon training before performing this surgical procedure.

Heterotopic ossification is a common finding after ankle arthroplasty (25% to 63%), and is more common in the posterior region of the distal tibia<sup>(17,21,24)</sup>. Valderrabano et al.<sup>(17)</sup> correlated heterotopic ossification to a reduced range of motion. Lee et al.<sup>(21)</sup> found less mobility and worse scores on the AOFAS hindfoot and ankle scale. The prophylaxis of this complication is still a matter of debate, and it appears to be more frequent in post-traumatic arthrosis. Other possible related factors are long surgical time, inadequate removal of bone debris after osteotomies, and the size of the small tibial component, leaving areas of spongy bone of the distal tibia exposed after the placement of the tibial component<sup>(21,24)</sup>. In the model evaluated in this study, there is no concern with covering the posterior cortex of the distal tibia with the tibial component. We observed heterotopic ossification of varying sizes in all cases. We were unable to relate this ossification to the range of motion or the AOFAS score, but its presence in the five cases drew our attention. Follow-up for a longer period of time, as well as a larger sample group, could help us respond to this issue.

This case series consisted of the first cases of arthroplasty undergoing surgery in our department. Despite the small sample and the short follow-up time, we observed some complications. At first glance, it appears to us that the ankle arthroplasty evaluated here did not produce the outcomes we initially expected. However, we must remember that there is a learning curve for this surgical technique, and the results tend to improve in the hands of surgeons who are more experienced with the procedure<sup>(7,20)</sup>. According to Haskell and Mann<sup>(8)</sup>, complications tend to decrease substantially after the fifth prosthesis fitting.

## Conclusion

The assessment of the first patients to undergo ankle arthroplasty with the Taric® prosthesis had outcomes considered poor in 40% of cases. However, in cases with an outcome considered satisfactory, there was improvement in pain and gain in leg-foot range of motion. In all patients, we noticed the formation of a posterior osteophyte alongside the posterior cortex of the distal tibia.

**Authors' contributions:** Each author contributed individually and significantly to the development of this article: WCLN \*(<https://orcid.org/0000-0001-7997-4868>) wrote the article, participated in the review process; MTC \*(<https://orcid.org/0000-0001-9411-9376>) conceived and planned the activities that led to the study, wrote the article, interpreted the results of the study, participated in the review process and approved the final version; RCF \*(<https://orcid.org/0000-0002-9886-5082>) conceived and planned the activities that led to the study, participated in the review process and approved the final version. \*ORCID (Open Researcher and Contributor ID) 

## References

- Escudero MI, Le V, Barahona M, Symes M, Wing K, Younger A, et al. Total ankle arthroplasty survival and risk factors for failure. *Foot Ankle Int.* 2019;40(9):997-1006.
- Yano K, Ikari K, Okazaki K. Radiographic outcomes of mobile-bearing total ankle arthroplasty for patients with rheumatoid arthritis. *Foot Ankle Int.* 2019;40(9):1037-42.
- Lee GW, Seon JK, Kim NS, Lee KB. Comparison of intermediate-term outcomes of total ankle arthroplasty in patients younger and older than 55 years. *Foot Ankle Int.* 2019;40(7):762-8.
- Gross CE, Hamid KS, Green C, Easley ME, DeOrio JK, Nunley JA. Operative wound complications following total ankle arthroplasty. *Foot Ankle Int.* 2017;38(4):360-6.
- Cadden AR. Imaging in total ankle replacement. *Semin Musculoskelet Radiol.* 2012;16(3):205-16.
- Glazebrook MA, Arsenault K, Dunbar M. Evidence-based classification of complications in total ankle arthroplasty. *Foot Ankle Int.* 2009;30(10):945-9.
- Myerson MS, Mroczek K. Perioperative complications of total ankle arthroplasty. *Foot Ankle Int.* 2003;24(1):17-21.
- Haskell A, Mann RA. Perioperative complication rate of total ankle replacement is reduced by surgeon experience. *Foot Ankle Int.* 2004;25(5):283-9.
- Wood PL, Crawford LA, Suneja R, Kenyon A. Total ankle replacement for rheumatoid ankle arthritis. *Foot Ankle Clin.* 2007;12(3):497-508.
- Gougoulias N, Khanna A, Maffulli N. How successful are current ankle replacements?: a systematic review of the literature. *Clin Orthop Relat Res.* 2010;468(1):199-208.
- Downie WW, Leatham PA, Rhind VM, Wright V, Branco JA, Anderson JA. Studies with pain rating scales. *Ann Rheum Dis.* 1978;37(4):378-81.
- Huskisson EC. Measurement of pain. *Lancet.* 1974;2(7889):1127-31.
- Kitaoka HB, Alexander IJ, Adelaar RS, Nunley JA, Myerson MS, Sanders M. Clinical rating systems for the ankle-hindfoot, midfoot, hallux, and lesser toes. *Foot Ankle Int.* 1994;15(7):349-53.
- Budiman-Mak E, Conrad KJ, Roach KE. The foot function index: a measure of foot pain and disability. *J Clin Epidemiol.* 1991;44(6):561-70.
- Haytmanek CT Jr, Gross C, Easley ME, Nunley JA. Radiographic outcomes of a mobile-bearing total ankle replacement. *Foot Ankle Int.* 2015;36(9):1038-44.
- Le V, Escudero M, Symes M, Salat P, Wing K, Younger A, et al. Impact of sagittal talar inclination on total ankle replacement failure. *Foot Ankle Int.* 2019;40(8):900-4.
- Valderrabano V, Hintermann B, Dick W. Scandinavian total ankle replacement: a 3.7-year average followup of 65 patients. *Clin Orthop Relat Res.* 2004;(424):47-56.
- Nery C, Fernandes TD, Réssio C, Fuchs ML, Santos ALG, Ortiz RT. Artroplastia total de tornozelo: experiência brasileira com a prótese HINTEGRA. *Rev Bras Ortop.* 2010;1(45):92-100.
- Barg A, Elsner A, Anderson AE, Hintermann B. The effect of three-component total ankle replacement malalignment on clinical outcome: pain relief and functional outcome in 317 consecutive patients. *J Bone Joint Surg Am.* 2011;93(21):1969-78.
- Kumar A, Dhar S. Total ankle replacement: early results during learning period. *Foot Ankle Surg.* 2007;13(1):19-23.
- Lee KB, Cho YJ, Park JK, Song EK, Yoon TR, Seon JK. Heterotopic ossification after primary total ankle arthroplasty. *J Bone Joint Surg Am.* 2011;93(8):751-8.
- Thornton J, Sabah S, Segaren N, Cullen N, Singh D, Goldberg A. Validated method for measuring functional range of motion in patients with ankle arthritis. *Foot Ankle Int.* 2016;37(8):868-73.
- Coetzee JC, Castro MD. Accurate measurement of ankle range of motion after total ankle arthroplasty. *Clin Orthop Relat Res.* 2004;(424):27-31.
- Buechel FF Sr, Buechel FF Jr, Pappas MJ. Ten-year evaluation of cementless Buechel-Pappas meniscal bearing total ankle replacement. *Foot Ankle Int.* 2003;24(6):462-72.