

Original Article

The interobserver reliability of first metatarsal rotational component of axial sesamoid radiographs in hallux valgus

Mariel Garcia-Limon^{1,2} , Jaime Isaias Ortiz-Garza^{1,2} , Abraham Guadalupe Espinosa-Uribe^{2,3} , Eduardo Rafael Carranza-Cantú¹ , Javier Meza-Flores^{2,3} , Jorge Gutiérrez-de la O^{2,4} 

1. Instituto de Seguridad Social de Trabajadores del Estado de Nuevo León, Monterrey, Nuevo León, Mexico.

2. Hospital Christus Muguerza, Monterrey, Nuevo León, Mexico.

3. Universidad de Monterrey, San Pedro Garza García, Nuevo León, Mexico.

4. Universidad Autónoma de Nuevo León, Monterrey, Nuevo León, Mexico.

Abstract

Objective: Hallux valgus is a progressive triplanar deformity of the forefoot with an important rotational component (RC) in the first metatarsal, which has been associated with recurrence. There is controversy about using weight-bearing vs. non-weight-bearing radiographs in RC measurement. This study aims to assess interobserver reliability for RC of the first metatarsal using a non-weight-bearing sesamoid view, as well as to correlate the hallux valgus angle, intermetatarsal angle, distal metatarsal articular angle (DMAA) and sesamoid position regarding RC.

Methods: An observational, cross-sectional and descriptive study was conducted with 81 feet from 48 patients (66.6% female). RC was evaluated regarding the first metatarsal proximal shaft in non-weight-bearing axial metatarsal radiographs and weight-bearing anteroposterior radiographs. Measurements were taken independently by two foot and ankle subspecialists and an orthopedic resident, all of whom were blinded.

Results: Statistically significant intraclass correlations ($p=0.02$) were obtained for first metatarsal RC assessment among the three observers (95%CI 0.01–0.65; Cronbach's $\alpha=0.41$) in non-weight-bearing axial metatarsal views. Significant correlations (Spearman ρ) were also found for hallux valgus angle ($p=0.04$) and DMAA ($p=0.01$), and non-significant correlations were found for intermetatarsal angle and sesamoid position ($p>0.05$).

Conclusion: The significant correlations between hallux valgus angle and DMAA for RC suggest that RC is isolated from the first metatarsal bone structure. This practical assessment method may isolate the first metatarsal head RC regarding the proximal metatarsal in the metaphyseal region and could be useful in centers where weight-bearing CT scans are not available.

Level of Evidence IV; Therapeutic Studies; Case Series.

Keywords: Bunion; Metatarsal bones; Foot deformities; Pronation; Rotation.

Introduction

Hallux valgus is a progressive triplanar deformity of the forefoot, characterized by a lateral deviation of the hallux towards the medial side of the foot and a rotational component (RC) with pronation of the head corresponding to the

first metatarsal⁽¹⁻³⁾ regarding its diaphysis or proximal metaphysis. It has been described that more than a third of the population over 65 years of age suffer from this deformity⁽⁴⁾.

In addition to conservative management, operative treatment of hallux valgus includes more than 200 procedures⁽⁵⁾.

Study performed at the Hospital Christus Muguerza, Monterrey, Nuevo León, Mexico.

Correspondence: Abraham Guadalupe Espinosa-Uribe. 2525 Hidalgo Av., Col. Obisnado, Monterrey, Nuevo León, Mexico, Zip Code: 64460. **E-mail:** abe.920224@gmail.com. **Conflicts of interest:** none. **Source of funding:** none. **Date received:** September 09, 2020. **Date accepted:** October 31, 2020. **Online:** December 21, 2020



This high number can be interpreted to reflect an incomplete understanding of the pathophysiology⁽⁴⁾. Historically, and especially recently, there has been an interest in RC, which can lead to better understanding and resolution in an effort to improve functionality and decrease recurrences^(6,7). Currently, there is controversy about RC assessment due to the technical heterogeneity and load quantity variance involved in both weight-bearing^(3,8) and partial weight-bearing radiographic projections⁽⁹⁾. Likewise, transurgical non-weight-bearing projections have been considered to have practical utility^(10,11), although without taking RC into account.

To our knowledge, there is no current well-accepted method for assessing RC in plain radiographs^(9,12-15). This study aimed to assess the inter-rater reliability of the RC of the first metatarsal from a non-weight-bearing sesamoid view, as well as to correlate hallux valgus angle (HVA), intermetatarsal angle (IMA), distal-metatarsal articular angle (DMAA) and sesamoid position regarding RC.

Methods

This study was approved by the research ethics committee of our university and hospital (number 22052020-ENM-1-CM-CI). All the radiographs were reviewed under the local law NOM-004-SSA3-2012 regarding medical file management, privacy rights and the ethical standards laid down in the 1964 Declaration of Helsinki. This study was conducted with resources from our institution and hospital. Since no financial profit was obtained through this study, no financial biases exist for any author and, thus, the authors declare no conflicts of interest.

This descriptive, cross-sectional observational study evaluated radiographs of 58 subjects. The study included patients over 16 years of age diagnosed with hallux valgus. Patients with previous forefoot surgeries were excluded, as were patients who did not comply with the weight-bearing anteroposterior foot and non-weight-bearing axial metatarsal views (10 patients). The RC of the first metatarsal head was evaluated in 48 patients (81 feet) according to the method of Mortier et al. (2012)⁽¹⁴⁾, in which a line representing the rotation of the plantar aspect is measured according to the line of the diaphysis of the first metatarsal or proximal metaphysis. We consider this measurement technique relevant in axial projections of the hallux sesamoids with 45 degrees of plantar flexion, since it considers a single bone structure, isolating to some extent the configuration and effect of other bone structures. The measurements were performed independently by two foot and ankle orthopedic subspecialists and one trauma and orthopedic resident, all of whom were blinded. For RC assessment in sesamoid views, as well as HVA, IMA, DMAA and sesamoid position assessment in anteroposterior projections, ImageJ digital Goniometer software was used (version 1.52q, National Institutes of Health, Bethesda, MD, USA) (Figure 1).

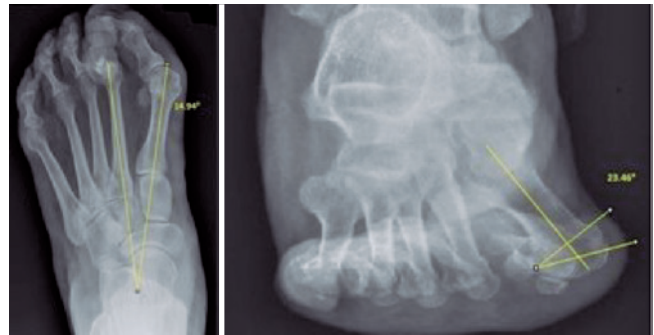


Figure 1. Weight-bearing anteroposterior and non-weight-bearing axial sesamoid view using the assessment method employed in this study.

Statistical analysis

Numerical variables are summarized as measures of central tendency and dispersion, and categorical variables as frequencies and percentages. The Kolmogorov-Smirnov test was performed to evaluate the distribution of the numerical variables. Numerical variables were compared using the Mann-Whitney U test. To assess interobserver agreement, the intraclass correlation test was used with a two-way random model for absolute agreement. In addition to the Spearman correlation coefficient (Spearman's ρ), scatter diagrams were made to graphically visualize the correlation of measurements between observers. $P < 0.05$ was considered statistically significant. SPSS version 25 for Mac (IBM, Armonk, NY, USA) was used for the analyses.

A priori sample size calculation was not performed because the entire available population was to be included in the databases. However, it was decided to estimate the power of the included sample. Using a sample estimation formula for agreement studies, the included sample size was determined to have a 90% confidence level and a 95% power to find an inter-observer agreement of 0.80 with an accuracy of 15%.

Results

Weight-bearing anteroposterior radiographs and non-weight-bearing axial sesamoid projections were evaluated in 48 patients (81 feet), whose mean age was 47.85 ± 14.75 years; 66.6% (32/48) were female and 33.3% (16/48) male.

The demographic characteristics of the sample, as well as the mean and standard deviation of the angles reported by the three observers are shown in tables 1 and 2. Statistically significant intraclass correlations (95%CI 0.01-0.65; $p=0.02$) were obtained for RC of the first metatarsal (Figure 2) among the three observers (Cronbach's $\alpha=0.41$).

We also found statistically significant correlations when evaluating HVA ($p=0.04$) and DMAA ($p=0.01$), as well as non-significant correlations when evaluating IMA and PS ($p>0.05$) (Table 3).

Table 1. Descriptive Statistics with average measures. Hallux valgus angle (HVA), intermetatarsal angle (IMA), distal metatarsal articular angle (DMAA) and rotational component (RC)

n=48 (81 feet)	Mean ± SD (degrees)
HVA observer 1	22.92 ± 11.38
IMA observer 1	12.38 ± 2.87
DMAA observer 1	15.81 ± 6.74
RC observer 1	18.07 ± 8.09
HVA observer 2	23.12 ± 11.29
IMA observer 2	12.54 ± 3.03
DMAA observer 2	16.00 ± 6.57
RC observer 2	13.31 ± 4.3
HVA observer 3	23.45 ± 12.65
IMA observer 3	13.11 ± 3.13
DMAA observer 3	15.39 ± 6.13
RC observer 3	21.98 ± 13.74

Table 2. Frequencies and percentages reported for sesamoid position by three observers

Sesamoid position	Grade 0	Grade 1	Grade 2	Grade 3
Observer 1	12 (14.8%)	31 (38.3%)	19 (23.5%)	19 (23.5%)
Observer 2	13 (16.0%)	31 (38.3%)	17 (21.0%)	20 (24.7%)
Observer 3	6 (7.4%)	31 (38.3%)	28 (34.6%)	16 (19.8%)

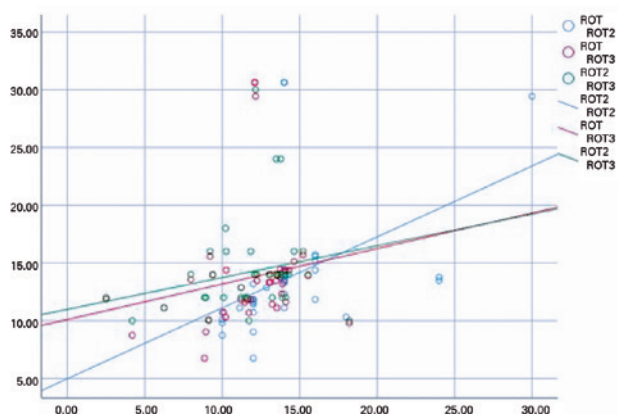


Figure 2. Scatter diagram of the correlation trend of the measurements between three observers for the rotational component.

Table 3. Non-parametric rotational component (RC) Spearman rank correlation coefficient (Spearman's ρ ; SCC) regarding hallux valgus angle (HVA), intermetatarsal angle (IMA), distal metatarsal articular angle (DMAA) and sesamoid position (SP)

	HVA	IMA	DMAA	SP
RC SCC	-0.22	-0.11	-0.27	-0.01
ρ	0.04	0.33	0.01	0.87

Discussion

There were significant intraclass correlations ($p=0.02$) among the three observers when assessing RC of the first metatarsal in axial projections of non-weight-bearing metatarsals using the method of Mortier et al.⁽¹⁴⁾ We consider this measurement technique relevant for axial projections of the hallux sesamoids since it considers the first metatarsal diaphysis, as well as another line that intersects the plantar cortices of the medial and lateral sesamoid grooves. We specifically selected this assessment technique since it considers the morphology of a single bone structure (first metatarsal) and its center of rotation⁽¹⁶⁾ (the head of the first metatarsal regarding the proximal diaphysis or epiphysis). Although it has been described that the morphology and relation of bony structures of the forefoot changes with the axial load^(17,18), these changes could be minimized by evaluating a single anatomical structure without considering the rest.

Although the clinical use of non-weight-bearing radiographic projections has been widely questioned in the literature^(17,19), most of these studies assessed RC using different techniques that involve technical differences^(9,12-15). Furthermore, there is increased interest in RC assessment using weight-bearing CT^(4,7,20). A practical method for assessing RC in plain radiographs could be clinically relevant, since it would allow it to be performed in a transurgical setting, as well as in centers in which no weight-bearing CT scans are available or where it is difficult to recreate the properties of the axial load^(10,11) in the operating room.

Regarding pathophysiology, interest has been expressed in the literature about the role of RC in first metatarsal hallux valgus deformity^(7,16), as well as dynamic factors⁽¹⁸⁾, such as muscle strength or ligament resistance, that could have a biomechanical effect on the global architecture of a weight-bearing foot⁽¹⁷⁾ in addition to an isolated bone structure. Our results are relevant in morphological terms because they describe the rotation by trying to isolate the first metatarsal deformity. They are also relevant in clinical and methodological terms by establishing good inter-observer agreement.

There is also controversy in the literature regarding the morphometric relationship between HVA, IMA, the position of the sesamoids^(9,15,21) and their relationship with RC⁽¹²⁾. This relationship was not significant in some studies⁽²⁰⁾ but significant in others^(9,12,15) mainly regarding the correlation between DMAA and RC⁽¹²⁾. In this study we found significant correlations when evaluating HVA ($p=0.04$) and DMAA ($p=0.01$), as well as non-significant correlations when evaluating IMA and PS ($p>0.05$) in relation to RC.

It is important to point out that due to the method of radiological evaluation used in the present study, which included the use of weight-bearing anteroposterior projections, some biomechanically dependent variables (HVA, IMA, and sesamoid position, i.e., which involve more than one bone structure in the forefoot) could not correlate due to the effect of load distribution when evaluating RC in non-weight-bearing axial projection. Despite a p -value of 0.04, the correlation between HVA and RC could be dependent on factors such as the DMAA in relation to the proximal phalanx and the HVA.

Likewise, the statistically significant correlation for DMAA ($p=0.01$) regarding RC could be explained as being partially independent of weight load. These findings could be due the fact that the progression of RC is related to the progression of DMAA and not to the correlation of weight-bearing angles (HVA, IMA, sesamoid position). Thus, evaluation and preoperative planning in patients for whom RC must be reduced could be clinically relevant.

Limitations

To our knowledge, this is the first study to evaluate morphological characteristics of first metatarsal rotation in a Mexican sample, as well as to standardize a method of RC evaluation with practical and clinical utility.

However, this study has important limitations. It was performed with axial radiographs of non-weight-bearing sesamoids to evaluate RC, while HVA, IMA, DMAA and the position of the sesamoids were measured using weight-bearing radiographs. We are aware of the controversy surrounding the use of non-weight-bearing projections in clinical practice^(17,19). However, studying RC in non-weight-bearing projections could help clarify the pathophysiological or morphological mechanism of hallux valgus, which could translate into future improvements in medical/surgical management, with better functional results in centers located in low- and middle-income countries that have limited resources.


Future studies on RC assessment should include different techniques with plain radiographs, comparing and adding these evaluations to weight-bearing CT. Although this is a retrospective study, the power of the sample size was calculated post-hoc, not prior to the study. However, our results will be useful when conducting secondary research about RC assessment and its morphological relationship with other clinically relevant anatomical structures.

Conclusion

Significant intraclass correlations ($p=0.02$) were obtained in the evaluation of first metatarsal rotation by three observers ($\alpha=0.41$) in axial radiographs of non-weight-bearing metatarsals. We also found significant correlations when evaluating HVA ($p=0.04$) and DMAA ($p=0.01$), as well as non-significant correlations when evaluating IMA and PS ($p>0.05$) regarding RC. This practical method of assessment may isolate the RC of the first metatarsal head regarding the proximal metatarsal in the metaphyseal region and could be useful in centers where weight-bearing CT scans are not available.

Acknowledgements

We wish to acknowledge the assistance of Fernando Fernandez-Garza, MD. and Luis Andres Valverde-Galindo, MD. for their comments on the manuscript.

Authors' contributions: Each author contributed individually and significantly to the development of this article: MGL (<https://orcid.org/0000-0002-8941-348X>) conception and design, acquisition and data analysis and interpretation of data, drafting the article and revising it critically for important intellectual content and discussion, final approval of the version to be published; JIOG (<https://orcid.org/0000-0002-3283-2843>) conception, design, acquisition and data analysis, statistical analysis, drafting the article or revising it critically for important intellectual content, final approval of the version to be published, and agree to be accountable for all aspects of the work if questions arise related to its accuracy or integrity. IRB approval process; AGEU (<https://orcid.org/0000-0003-0642-2063>) conception and design acquisition, analysis and interpretation of data, translation and English edition of the manuscript, drafting the article and revising it critically for important intellectual content and discussion, final approval of the version to be published, and agree to be accountable for all aspects of the work if questions arise related to its accuracy or integrity, text redaction for IRB approval process; ERCC (<https://orcid.org/0000-0003-1162-4997>) conception and design, interpretation of data, revising the manuscript critically for important intellectual content, final approval of the version to be published, and agree to be accountable for all aspects of the work. IRB approval process; JMF (<https://orcid.org/0000-0001-8493-7105>) drafting the article, text redaction for IRB approval, statistical analysis, manuscript translation and final approval of the manuscript version to be published; JGO (<https://orcid.org/0000-0002-4372-061X>) conception and design, statistical analysis, data interpretation, revising the manuscript critically for important intellectual content and discussion, agree to be accountable for all aspects of the work if questions arise related to its accuracy or integrity, IRB approval process and final approval of the version to be published. *ORCID (Open Researcher and Contributor ID) 

References

1. Wagner P, Wagner E. Is the rotational deformity important in our decision- making process for correction of hallux valgus deformity? *Foot Ankle Clin.* 2018;23(2):205-17.
2. Wagner P, Ortiz C, Wagner E. Rotational osteotomy for hallux valgus. A new technique for primary and revision cases. *Tech Foot Ankle Surg.* 2017;16(1):3-10.
3. Prado M, Baumfeld T, Nery C, Mendes A, Baumfeld D. Rotational biplanar Chevron osteotomy. *Foot Ankle Surg.* 2020;26(4):473-6.
4. Collan L, Kankare JA, Mattila K. The biomechanics of the first metatarsal bone in hallux valgus: a preliminary study utilizing a weight bearing extremity CT. *Foot Ankle Surg.* 2013;19(3):155-61.
5. Easley ME, Trnka HJ. Current concepts review: hallux valgus part 1: pathomechanics, clinical assessment, and nonoperative management. *Foot Ankle Int.* 2007;28(5):654-9.
6. Hatch DJ, Santrock RD, Smith B, Dayton P, Weil L Jr. Triplane hallux abducto valgus classification. *J Foot Ankle Surg.* 2018;57(5):972-81.
7. Wagner E, Wagner P. Metatarsal pronation in hallux valgus deformity: a review. *J Am Acad Orthop Surg Glob Res Rev.* 2020; 4(6):e20.00091.
8. Eustace S, O'Byrne J, Stack J, Stephens MM. Radiographic features that enable assessment of first metatarsal rotation: the role of pronation in hallux valgus. *Skeletal Radiol.* 1993;22(3):153-6.

9. Dayton P, Carvalho S, Egdorf R, Dayton M. Comparison of Radiographic Measurements Before and After Triplane Tarsometatarsal Arthrodesis for Hallux Valgus. *J Foot Ankle Surg.* 2020;59(2):291-7.
10. Park CH, Lee WC. Recurrence of hallux valgus can be predicted from immediate postoperative non-weight-bearing radiographs. *J Bone Joint Surg Am.* 2017;99(14):1190-97.
11. Midjord J. Bunion surgery: check these radiographic parameters intraoperatively to avoid recurrence: commentary on an article by Chul Hyun Park, MD, PhD, and Woo-Chun Lee, MD, PhD: "Recurrence of hallux valgus can be predicted from immediate postoperative non-weight-bearing radiographs". *J Bone Joint Surg Am.* 2017;99(14):e80.
12. Cruz EP, Wagner FV, Henning C, Sanhudo JAV, Pagnussato F, Galia CR. Comparison between simple radiographic and computed tomographic three-dimensional reconstruction for evaluation of the distal metatarsal articular angle. *J Foot Ankle Surg.* 2017;56(3):505-9.
13. Saltzman CL, Brandser EA, Anderson CM, Berbaum KS, Brown TD. Coronal plane rotation of the first metatarsal. *Foot Ankle Int.* 1996;17(3):157-61.
14. Mortier JP, Bernard JL, Maestro M. Axial rotation of the first metatarsal head in a normal population and hallux valgus patients. *Orthop Traumatol Surg Res.* 2012;98(6):677-83.
15. Dayton P, Feilmeier M, Hirschi J, Kauwe M, Kauwe JS. Observed changes in radiographic measurements of the first ray after frontal plane rotation of the first metatarsal in a cadaveric foot model. *J Foot Ankle Surg.* 2014;53(3):274-8.
16. Durrant M, Durrant L, McElroy T. Establishing a common instantaneous center of rotation for the metatarso-phalangeal and metatarso-sesamoid joints: a theoretical geometric model based on specific morphometrics. *J Orthop Surg Res.* 2019;14(1):107.
17. Fuhrmann RA, Layher F, Wetzel WD. Radiographic changes in forefoot geometry with weightbearing. *Foot Ankle Int.* 2003;24(4):326-31.
18. Kimura T, Kubota M, Taguchi T, Suzuki N, Hattori A, Marumo K. Evaluation of first-ray mobility in patients with hallux valgus using weight-bearing CT and a 3-D analysis system: a comparison with normal feet. *J Bone Joint Surg Am.* 2017;99(3):247-55.
19. Shereff MJ, DiGiovanni L, Bejjani FJ, Hersh A, Kummer FJ. A comparison of nonweight-bearing and weight-bearing radiographs of the foot. *Foot Ankle.* 1990;10(6):306-11.
20. Kim Y, Kim JS, Young KW, Naraghi R, Cho HK, Lee SY. A New measure of tibial sesamoid position in hallux valgus in relation to the coronal rotation of the first metatarsal in CT scans. *Foot Ankle Int.* 2015;36(8):944-52.
21. Ono Y, Yamaguchi S, Sadamasu A, Kimura S, Watanabe S, et al. The shape of the first metatarsal head and its association with the presence of sesamoid-metatarsal joint osteoarthritis and the pronation angle. *J Orthop Sci.* 2020;25(4):658-63.