

Original Article

Minimally invasive technique for suprasyndesmotic ankle fracture fixation: clinical and radiographic analysis

Renê Hobi¹, Rodolfo Galera², José Tárício de Campos Filho¹, Leonardo Mugnol¹

1. Hospital do Trabalhador, Curitiba, PR, Brazil.

2. Hospital Pequeno Príncipe, Curitiba, PR, Brazil.

Abstract

Objective: To evaluate the clinical and radiographic results of suprasyndesmotic ankle fracture fixation with a minimally invasive technique.

Methods: Retrospective study of 11 patients with suprasyndesmotic fractures of the lateral malleolus who underwent surgery between 2016 and 2018. Retrospective analysis of medical records considered the following: radiographic assessments (preoperative, immediate postoperative, six weeks postoperative), clinical evaluation, and strength scale and movement test results.

Results: Of the 18 patients qualified for inclusion, 7 failed to appear at the follow-up appointment and were excluded. The patients' age varied from 20 to 53 years, and 72.7% were male. The trauma mechanisms included torsion (46% of the cases), automobile accidents (36.4%) and direct trauma (17.6%). The mean time between trauma and definitive surgery was 3.27 days. The mean talocrural angle in the preoperative period was 83.13°, ranging from 80.63° in the immediate postoperative period to 81.27° at 6 months postoperatively. Approximately 90% of the patients did not lose strength. Regarding the range of motion, the mean dorsiflexion and plantar flexion 6 months postoperatively were 10.72° and 34.4°, respectively.

Conclusion: The minimally invasive technique had excellent technical results in patients treated surgically for ankle fractures and required smaller incisions than conventional surgery. Osteolysis or fatigue of the osteosynthesis material is a possibility with this technique, which generally occurred between three and four months postoperatively.

Level of Evidence IV; Therapeutic Studies; Case Series.

Keywords: Ankle fractures/diagnostic imaging; Minimally invasive surgical procedures; Fracture fixation, intramedullary; Treatment outcome.

Introduction

Ankle fractures are among the most common injuries treated by orthopedists. Typically, ankle fractures result from injuries caused by a low-energy mechanism, such as torsional trauma. In the United States, about 8.3 of every 1000 patients seen at health services each year have an ankle fracture⁽¹⁾.

Knowledge of the trauma mechanism is significant, since it helps the orthopedist understand the fracture, assess the patient's clinical and soft tissue conditions, and determine the best surgical approach⁽²⁾.

The criteria for conservative or surgical treatment are well established. In fractures that require surgery, open reduc-

tion with internal plate and screw fixation is the gold standard. Despite good results with this technique, patients who smoke, have diabetes or have peripheral vascular diseases are more vulnerable to complications, such as surgical wound dehiscence, skin necrosis and absence of fracture consolidation. Use of a new technique, known as minimally invasive percutaneous plate osteosynthesis (MIPPO), has increased due to its decreased rate of postoperative complications⁽³⁾ and smaller incisions (3cm vs. approximately 10cm in the conventional technique).

One of the main objectives of ankle fracture treatment is to maintain tibiotalar congruence, which promotes joint stability and allows joint movement and early rehabilitation.

Study performed at the Hospital do Trabalhador, Curitiba, PR, Brazil.

Correspondence: Leonardo Mugnol, 1399 Afonso Camargo Av., 8th Floor, Room 813, Cristo Rei, Curitiba, PR, Brazil, Zip Code: 80050-370. **Conflicts of interest:** none. **Source of funding:** none. **Date received:** September 29, 2020. **Date accepted:** November 16, 2020. **Online:** December 21, 2020

How to cite this article: Hobi R, Galera R, Campos Filho JT, Mugnol L. Minimally invasive technique for suprasyndesmotic ankle fracture fixation: clinical and radiographic analysis. *J Foot Ankle.* 2020;14(3):274-7.

Lauge-Hansen⁽³⁾ classified ankle fractures based on the mechanism of injury. Through a cadaveric study, he assessed the position of the foot (supination or pronation) and the deforming force at the time of trauma (external rotation, abduction and adduction) and proposed that understanding the mechanism of injury would facilitate the fracture reduction procedure by recreating the deforming force:

- 1) Pronation-abduction: the talus is abducted in the mantle, coming into contact with the medial structures and compressing the sides.
- 2) Pronation and external rotation: injury to the lateral and posterior elements occurs
- 3) Supination and adduction: this mechanism of injury leads to the following two stages:
 - Stage I: Fracture of the malleolus below the syndesmosis;
 - Stage II: Vertical fracture of the medial malleolus.
- 4) Supination and external rotation: this is the most common mechanism, which includes about 75% of all ankle injuries

In addition to Lauge-Hansen classification, the Danis-Weber system is used to classify fractures of the lateral malleolus:

- **Type A:** Infrasyndesmotric fracture, which is usually associated with avulsion of the lateral ligament complex.
- **Type B:** Oblique or spiral fracture at the level of the syndesmosis, which may be associated with injuries to the posterior elements.
- **Type C:** Fracture above the level of the syndesmosis, which may include Maisonneuve-type injuries.

Type C fractures are visible radiographically above the level of distal tibiofibular syndesmosis and are associated with loss of joint congruence. These are usually treated with open reduction and internal fixation. In the intraoperative period of these patients, we evaluated the syndesmosis lesion using the Cotton test⁽³⁾ or the dorsiflexion test; external rotation of the ankle was assessed with fluoroscopy.

These patients are immobilized for 15 days with an orthosis and were followed serially (15, 45, 90,180 days) until their return to normal activities. We indicate physical therapy and partial body-weight support beginning at 15 days postoperatively. At approximately 90 postoperative days, the patient is ready to return to work and resume normal activities.

The aim of the study was to propose a minimally invasive technique for treating suprasyndesmotric lateral malleolus fractures, assessing its results through a retrospective analysis of the medical records of patients who underwent the procedure between 2016 and 2018.

Methods

This study was approved by the Institutional Review Board and registered on the Plataforma Brasil database under CAAE (Ethics Evaluation Submission Certificate) number: 36477520.1.0000.5225.

The comparative retrospective analysis included medical records and complementary exams (radiography), patient satisfaction results (self-report), strength test results (dynamometry), and range of motion test results (goniometry), as well

as measurement of the talocrural angle preoperatively, in the immediate postoperative period and at least six weeks postoperatively.

The medical records were collected through a Unified Health System procedure code ("Surgical treatment of unimalleolar ankle fracture" - 040805057-80).

The inclusion criteria were patients with Danis-Weber type C suprasyndesmotric lateral malleolus fractures with instability of the distal tibiofibular syndesmosis who underwent surgery between 2016 and 2018. The exclusion criteria were bimalleolar fractures, trimalleolar fractures, treatment with conventional osteosynthesis techniques, Danis-Weber type A or B fractures and failure to appear at the post-operative follow-up appointment.

We retrospectively analyzed radiographic images and joint congruence. Clinical evaluation of the medical records included the degree of strength on a scale of 0-5 (compared to the contralateral side), the range of motion, the visual analog pain score, and the trauma mechanism that caused the fracture.

All selected patients provided written informed consent prior to inclusion. In the cases selected for this study (patients with Danis-Weber type C ankle fractures), it was decided to use a minimally invasive technique for syndesmosis fixation.

The data were tabulated in Microsoft Excel 2016 and analyzed in SPSS.

Surgical technique

1. Distal tibiofibular syndesmosis was assessed using fluoroscopy following Koenig et al.⁽⁵⁾, including dorsiflexion and external rotation of the ankle, maintaining the true anteroposterior incidence of the ankle.
2. Indirect fracture reduction using traction and countertraction, rotation and fluoroscopy to obtain ankle and distal tibiofibular joint congruence.
3. Joint reduction was maintained with a 2.0mm Kirschner wire that entered the distal region of the fibula and was anchored in the medial cortex of the tibia.
4. A lateral incision of approximately 3cm in the fibula, always below the level of the fracture and slightly suprasyndesmotric.
5. Fixation with a one-third tubular plate with three holes and two transyndesmal screws⁽⁶⁾, which stabilized the syndesmosis, indirectly stabilized the proximal fracture and maintained the joint congruence of the ankle (Figure 1).
6. Intraoperative fluoroscopy was performed, keeping the ankle in true anteroposterior incidence during dorsiflexion and external rotation. Distal tibiofibular stability was assessed after fixation.

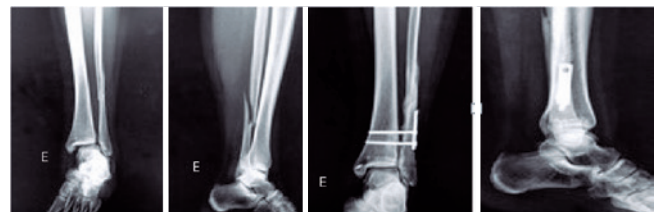

Figure 1. Minimally invasive surgery results in the immediate postoperative period.

It should be noted that the indirect reduction of syndesmosis and stabilization with the third tubular plate and screws was addressed, and not the suprasyndesmotic fracture.

Results

Although 18 patients met the inclusion criteria, 7 failed to appear at the 6-month follow-up appointment regarding patient satisfaction and were excluded from the study. The 11 included patients had a mean age of 34.7 years (20-53) and 72.7%(8) were male.

The trauma mechanisms included torsional trauma (46%; 5), automobile accidents (36.4%; 4) (we could not determine whether the trauma was direct or indirect), and direct trauma (17.6%; 2). The mean time between trauma and surgical treatment was 3.27 days, with a maximum of 19 days and a minimum of zero.

According to radiographic analysis, the preoperative talocrural angle varied from 79° to 95° with a mean of 83.13°. The angle in the immediate postoperative period ranged from 78° to 83°, with a mean of 80.63°. Finally, at the 6-month postoperative evaluation, the angle varied from 80° to 86°, with a mean of 81.27° (Figure 2).

After 6 months of follow-up, we obtained the following strength values: inversion grade 5 in 90.9% (10) and grade 4 in 9.1% (1), eversion grade 5 in 90.9%(10) and grade 4 in 9.1%(1), dorsiflexion grade 5 in 90.9%(10) and grade 4 in 9.1%(1), and plantar flexion grade 5 in 90.9%(10) and grade 4 in 9.1%(1). Four different patients had a decrease in each type of movement. The analog pain scale was used to assess postoperative pain. Scores ranged from 0 to 6, with a mean of 1.54. Regarding the range of motion of the operated ankle, dorsiflexion varied between 5° and 15°, with a mean of 10.72°, whereas the plantar flexion varied from 35° to 45°, with a mean of 34.4° (Figure 3). There were no complications in any of the cases.

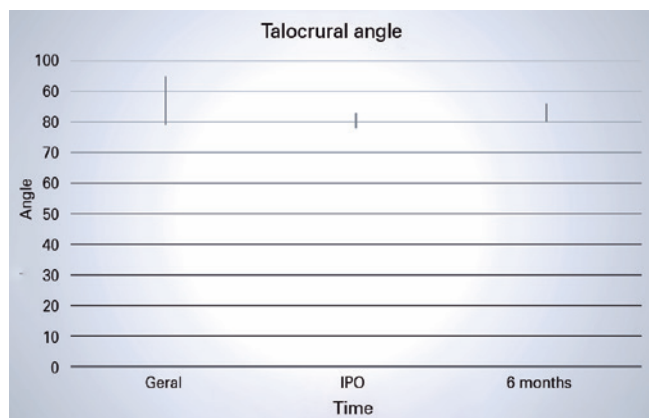


Figure 2. Variation of the talocrural angle in the preoperative period, immediate postoperative (IPO) period and at 6 months of follow-up.




Figure 3. Range of motion assessment.

Discussion

Classically, open reduction and internal fixation with plates and screws is considered the gold standard for correcting fractures of the suprasyndesmotic lateral malleolus. However, due to the increased risk of complications related to wound healing, especially in patients with vasculopathies due to diabetes or vascular insufficiency, minimally invasive approaches are gaining ground.⁽¹⁾

Although a number of studies have demonstrated the success of minimally invasive surgery, considerably fewer have been carried out on ankle fractures, such Pires et al. (2014). Thus, the aim of our study was to demonstrate the effectiveness of minimally invasive treatment for suprasyndesmotic lateral malleolus fractures (Danis-Weber type C).

Our patients had a lower mean age (34.7 years) than other studies^(1,4), as well as a different sex prevalence (more men than women)^(1,4). However, such information was not relevant since the most frequent trauma mechanism in the sample, torsional trauma (45.5%), was the most commonly described mechanism in the literature. The prevalence of trauma due to automobile accidents in our sample was also expressive (36.4%), which is explained by the fact that our Orthopedics and Traumatology Service is a reference center for trauma.

The mean time until surgery (3.27 days) was acceptable given that fractures of the suprasyndesmotic lateral malleolus, in most cases, are not considered emergencies and are likely to receive elective treatment within two weeks of the trauma.

Regarding surgical efficacy in the late postoperative period, the chosen treatment can be considered excellent, both for the minimal pain reported by the patients (a mean of 1.54 on a scale of 0 to 10) and for the degree of muscle strength during inversion, reversal, and plantar and dorsal ankle flexion, which was maximal (grade 5) in almost all cases (90.9%).

In addition, our surgical approach showed mean plantar and dorsiflexion (34.4° and 10.72°, respectively) close to the peak range of motion (45° and 20°, respectively)^(4,5).

We used a minimally invasive incision of about 3cm in the lateral portion of the fibula, as described by Pires et al.⁽¹⁾, which is much smaller than the approximately 10 cm incision used in the conventional technique .

In cases where the medial clear space was ≥ 5 mm after fixation, a medial approach involving retensioning of the medial capsule with transosseous sutures or a metallic anchor with high-strength wire was selected⁽⁷⁾.

In the radiographic analysis, it was observed that four months postoperatively, all patients had either osteolysis around the osteosynthesis material or implant fatigue (broken screws). This is not surprising, since the distal tibiofibular joint is highly mobile and becomes rigid when stabilized. As it tries to return its natural degree of mobility, lysis or implant breakage can occur⁽⁶⁾.


Finally, it is worth mentioning that the minimally invasive technique was applied to Danis-Weber type C fractures, which, according to the literature, require treatment with syndesmosis fixation, unlike the Danis-Weber type B fractures analyzed by Pires et al.⁽¹⁾, who only recommended stabilizing the lateral malleolus.

When performing this type of procedure, we advise removing the surrounding osteosynthesis material approximately four months after the operation to avoid breakage and/or lyse.⁽⁶⁾ However, osteolysis or fatigue of the osteosynthesis material did not lead to clinical complications and/or functional deficits in our sample.

We obtained good radiographic and functional results with a minimally invasive surgery technique in this sample of patients. Despite the short follow-up period, the fact that seven patients failed to appear for the final follow-up, and the biases implicit in these factors, the results were promising. Thus, another option for treating these fractures is available in the therapeutic arsenal of the orthopedic surgeon.

Conclusion

In comparison to the traditional technique of open reduction and internal fixation of unimalleolar suprasyndesmotic ankle fractures, minimally invasive surgery is becoming increasingly common as an approach for these injuries due to its excellent functional results, the preservation of strength and mobility, and smaller surgical incisions.

Authors' contributions: Each author contributed individually and significantly to the development of this article: RH *(<https://orcid.org/0000-0002-3371-1752>) wrote the article; participated in the review process; RG *(<https://orcid.org/0000-0001-8099-820X>) interpreted the results of the study; conceived and planned the activities that led to the study; JTCF *(<https://orcid.org/0000-0001-8274-2195>) participated in the review process; approved the final version; LM *(<https://orcid.org/0000-0003-3377-7919>)) wrote the article; approved the final version. *ORCID (Open Researcher and Contributor ID) 

References

1. Pires RES, Mauffrey C, de Andrade MAP, Figueiredo LB, Giordano V, Belloti JC, et al. Minimally invasive percutaneous plate osteosynthesis for ankle fractures: a prospective observational cohort study. *Eur J Orthop Surg Traumatol*. 2014;24(7):1297-303.
2. Warner SJ, Garner MR, Hinds RM, Helfet DL, Lorch DG. Correlation between the Lauge-Hansen classification and ligament injuries in ankle fractures level of evidence: diagnostic level II. see instructions for authors for a complete description of levels of evidence. *J Orthop Trauma*. 2015;29(12):574-8.
3. Russo A, Reginelli A, Zappia M, Rossi C, Fabozzi G, Cerrato M, et al. Erratum: Ankle fracture: Radiographic approach according to the Lauge-Hansen classification. *Musculoskelet Surg*. 2013;97(3):279.
4. Litrenta J, Saper D, Tornetta P 3rd, Phieffer L, Jones CB, Mullis BH, et al. Does syndesmotic injury have a negative effect on functional outcome? A multicenter prospective evaluation. *J Orthop Trauma*. 2015;29(9):410-3.
5. Koenig SJ, Tornetta P, Merlin G, Bogdan Y, Egol KA, Ostrum RF, et al. Can we tell if the syndesmosis is reduced using fluoroscopy? *J Orthop Trauma*. 2015;29(9):e326-30.
6. Michelson JD, Wright M, Blankstein M. Syndesmotic ankle fractures. *J Orthop Trauma*. 2018;32(1):10-4.
7. Ebraheim NA, Weston JT, Ludwig T, Moral MZ, Carroll T, Liu J. The association between medial malleolar fracture geometry, injury mechanism, and syndesmotic disruption. *Foot Ankle Surg*. 2014; 20(4):276-80.