

Technical Tips

Calcaneonavicular coalition resection: technical tip

Mercedes Elizabeth Tacuri Juncay¹, Rafael Barban Sposeto¹, Alexandre Leme Godoy-Santos¹, Túlio Diniz Fernandes¹

1. Instituto de Ortopedia e Traumatologia, Hospital das Clinicas HCFMUSP, Faculdade de Medicina, Universidade de São Paulo, SP, Brazil.

Abstract

Tarsal coalition is an abnormal connection between tarsal bones, caused by an embryogenic failure. Its most common forms are calcaneonavicular and talocalcaneal coalition, which are present in 53% and 37% of the cases, respectively. The onset of symptoms is related to tarsal bone ossification, and mean age for this event is estimated at 16 years for calcaneonavicular coalition. Surgical treatment is indicated for patients who did not improve symptoms with conservative treatment. The aim of this study is to present a surgical technique as a treatment option for resection of calcaneonavicular coalition associated with abnormal cuboid-navicular joint.

Level of Evidence V; Therapeutic Studies; Expert Opinion.

Keywords: Tarsal coalition/surgery; Tarsal bones; Foot deformities, congenital; Osteotomy/methods.

Introduction

Tarsal coalition is a term used to define an abnormal connection between two tarsal bones, was officially described for the first time by Buffon in 1796, and is caused by failure of mesenchymal segmentation during embryogenesis⁽¹⁾.

The incidence of tarsal coalition is from 1 - 2% in the general population; its most common forms are calcaneonavicular (53%) and talocalcaneal (37%) coalitions, which may be present bilaterally in 60 - 50% of the cases, respectively. Other tarsal coalitions, such as talonavicular, calcaneocuboid, and cuboid-navicular, are less common and represent < 10% of the general population⁽²⁾. Only 25% of tarsal coalitions are symptomatic⁽³⁾.

Calcaneonavicular coalition may be a osseous, cartilaginous, or fibrous bar⁽⁴⁾ that locks the affected joint, leading to reduced range of motion of hindfoot and thus to loss of foot accommodation capacity on uneven surfaces, since overload on surrounding joints^(5,4) leads to inflammation and pain, which are the most frequent symptoms in adolescents⁽⁶⁾. The onset of symptoms is correlated with the ossification process and usually occurs between 12-15 years for calcaneonavicular coalition⁽⁷⁾.

The classical clinical presentation in adolescents is heel pain that worsens with physical activity, difficulty to walk on uneven surfaces along with history of ankle sprains⁽⁶⁾, and the most evident clinical signs are hindfoot valgus deformity, forefoot

abduction, collapse of the medial arch of the foot, and spasticity of fibular tendons⁽⁸⁾. However, some authors report cases of varus cavus deformity.

The diagnosis is based on clinical history, physical examination, and imaging tests, starting with radiographies in 3 incidences: anteroposterior (AP), lateral, and oblique- weighted scans. Computed tomography (CT) and magnetic resonance imaging (MRI) are very useful, because they provide a more detailed description of location, size, degenerative changes in joints or of any concomitant coalition, which helps develop a more effective pre-operative planning⁽⁹⁾.

The treatment aimed to relieve pain and to reduce stress on calcaneonavicular coalition; moreover, is indicated for patients with symptomatic calcaneonavicular coalition and may start with changes in habits, wearing of rigid sole shoes, physical therapy, nonsteroidal anti-inflammatory drugs, insoles, orthosis, and immobilization with a cast.

Surgical resection of coalition is indicated when there is no improvement with conservative measures⁽¹⁰⁾. Corrective osteotomies may be used in cases when calcaneonavicular coalition is associated with pes planus valgus, or arthrodeses when it is associated with joint degeneration⁽¹¹⁾.

The objective of this study is to present a surgical treatment option for resection of calcaneonavicular coalition associated with abnormal cuboid-navicular joint using a dorsolateral access in the topography of the heel.

Study performed at the Instituto de Ortopedia e Traumatologia, Hospital das Clinicas HCFMUSP, Faculdade de Medicina, Universidade de São Paulo, SP, Brazil.

Correspondence: Mercedes Elizabeth Tacuri Juncay. 150 Alves Guimarães St., Pinheiros, São Paulo, Brazil, Zip Code: 05410-000. **Conflicts of interest:** none. **Source of funding:** none. **Date received:** November 10, 2020. **Date accepted:** November 25, 2020. **Online:** December 21, 2020



The case used to illustrate the surgical technique consisted of a 13-year-old male adolescent with no comorbidities and history of lateral foot pain and recurrent left ankle sprains.

In this case, feet alignment was symmetrical and adequate. Range of inversion and eversion of the left foot was slightly limited, with pain in the motion threshold.

Complementary tests revealed reverse anteatler nose sign in AP incidence (Figure 1A), and anteatler nose sign in lateral weighted incidence (Figure 1B). Computed tomography provided information on a little usual navicular shape extending toward lateral and plantar maintaining contact with the dorsal and plantar portions of anterior process of the calcaneus. Furthermore, an abnormal facet joint was observed between the lateral portion of the navicular bone and the cuboid bone. Three-dimension reconstruction CT (Figure 2) and MRI (Figure 1C, 1D) scans were obtained to achieve a better understanding on calcaneonavicular coalition and to help operative planning.

Surgical technique

This surgical technique is indicated for resection of symptomatic calcaneonavicular bar refractory to conservative treatment.

Patient positioning

Patient in the supine position under general anesthesia, on a radiolucent surgical table, with a cushion under the ipsilateral hip to promote a slight internal rotation of the limb to be operated.

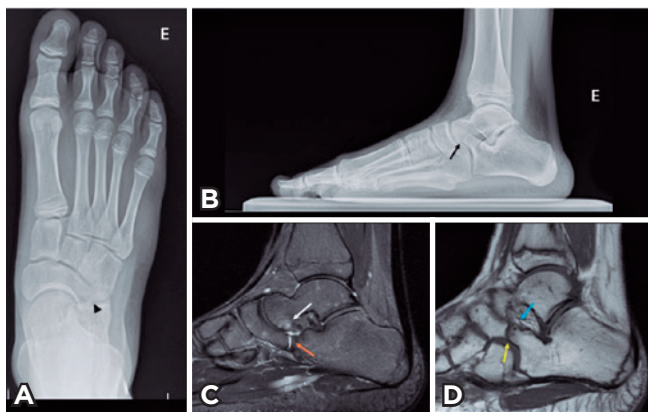


Figure 1. A. AP x-ray showing reverse anteatler nose sign (arrow head). B. Weighted lateral x-ray: Elongated anterior process of the calcaneus (black arrow). Magnetic resonance imaging. C. Sagittal T2 section. Plantar elongation of the navicular in contact with the head of the talus; moreover, osseous edema and fluid between the talus and the coalition was observed (white arrow). Fibrocartilaginous coalition between the calcaneus and the navicular (orange arrow). D. Sagittal T1 section. Elongation of the navicular bone creating an abnormal joint with the cuboid bone. (yellow arrow), cysts in the anterior portion of the calcaneus in contact with the navicular (blue arrow).

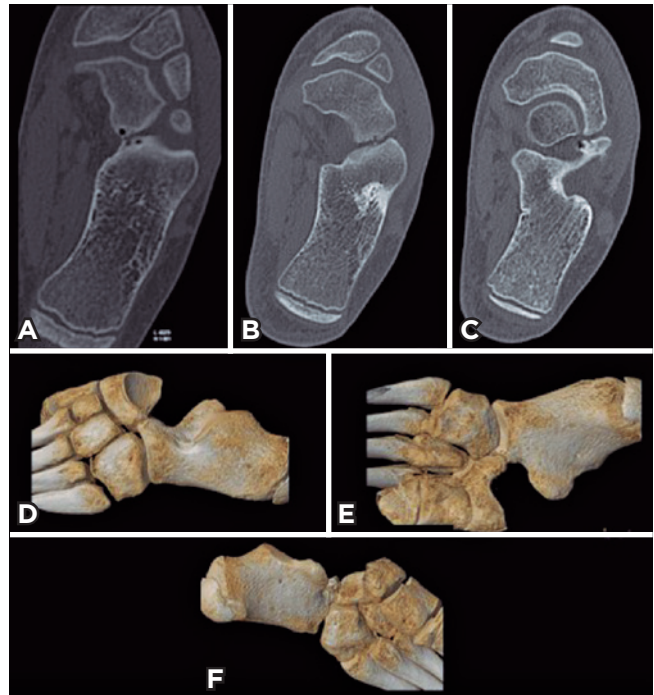

Figure 2. Computed tomography showing the extension of the entire tarsal coalition (left and right). A. Tarsal coalition with plantar and medial contact. B. Tarsal coalition in contact with the medial portion. C. Tarsal coalition with dorsolateral contact. 3D reconstruction images. D. Lateral view. E. Plantar view. F. Medial view.

A non-sterile tourniquet is placed on the tight of the limb to be operated.

Surgical approach

1. An oblique 3-cm incision is made at the dorsolateral surface of the foot centered on the anterior process of the calcaneus at a line between the between towards the base of the fourth metatarsal (Figure 3A);
2. It is necessary to identify and dissect the inferior extensor retinaculum so as to maintain its integrity;
3. The proximal portion of the belly of the extensor digitorum brevis muscle is desinserted and this muscle is distally separated in order to expose the anterior process of the calcaneus, the lateral portion of the navicular bone, the dorsal portion of the cuboid bone, and the plantar portion of the head of the talus (Figure 3B, 3C), and care should be taken not to injury the lateral branch of the superficial peroneal nerve;
4. The first section is made so as to resect the dorsolateral volume of the coalition, allowing for the visual access of the deeper and more medial portion, in order to avoid inadvertently extensive resections that could compromise the healthy cartilage;

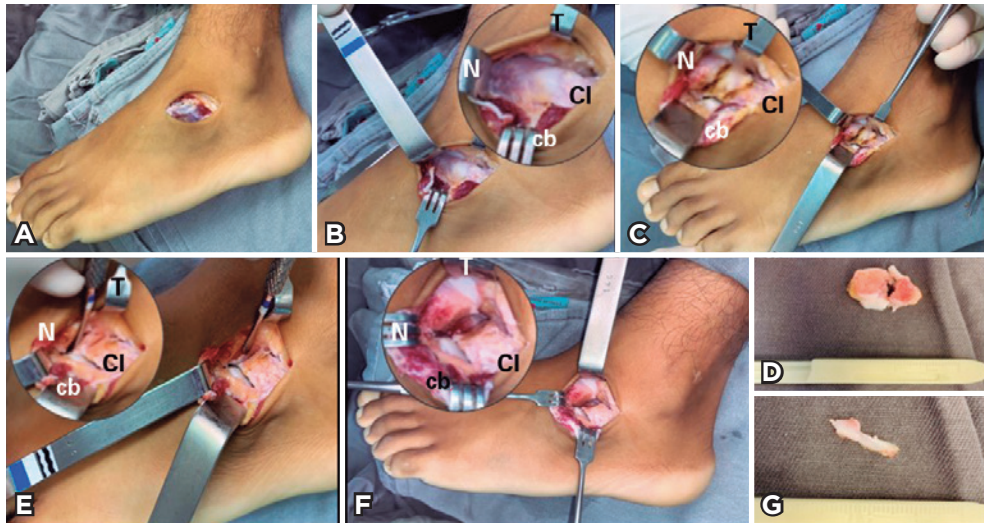


Figure 3. A. Oblique incision on the dorsolateral surface of the foot B. Exposure of calcaneonavicular bar. C. Marking of sections for calcaneonavicular bar resection. D. Resected surgical specimen of the calcaneonavicular bar. E. Identification of abnormal facet joint between the navicular and the cuboid. F. Osteotomy for resection of facet joint between the navicular and the cuboid. G. Surgical specimen of resected facet joint of the navicular bone. *T: Talus, N: Navicular, Cl: Calcaneus, Cb: Cuboid.

5. Therefore, it is important to visualize the plantar portion of the head of the talus, which is the lower anatomical parameter for navicular resection;
6. An osteotome is placed at the navicular bone, respecting the lower edge of the head of the talus, and another osteotome is placed at the anterior process of the calcaneus, convergent with the first one;
7. It is important to note that this osteotome arrangement leads to an incomplete resection of coalition, since the plantar and medial bony portions of the navicular and the calcaneus will remain in contact, but this arrangement will allow for the excision of the most superficial portion of the bar, followed by the direct visualization of its deepest portion, thus allowing for a more accurate resection of the entire coalition and preventing damages to healthy joint regions, especially those located at the head of the talus;
8. The surgical specimen is removed, and complete resection of the osseous bar should be confirmed by fluoroscopy, since one of main errors in this procedure is performing an incomplete resection of the osseous bar (Figure 3D, 4A);
9. After resection of the calcaneonavicular bar, a little contact between navicular and cuboid bones is observed, residual from its abnormal joint, which is partially locking joint range of motion. Its resection is performed by vertical osteotomy of the most distal and lateral portion of the navicular bone, and, once section is finished, the surgical specimen is removed and a new control is made using direct fluoroscopy (Figure 3E, 3F, 3G, 4B);
10. The range of motion of subtalar joint is verified;

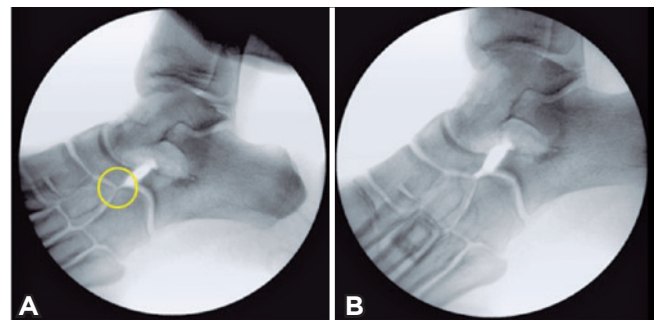


Figure 4. Intraoperative images with fluoroscopy A. Control image after calcaneonavicular bar resection, abnormal facet joint between the navicular and the cuboid (circle). B. Complete resection of calcaneonavicular coalition and abnormal navicular-cuboid joint.

11. The inferior extensor retinaculum is reinserted between the navicular bone and the anterior process of the calcaneus, interposing the muscle in place of the coalition;
12. The tourniquet is deflated and an adequate hemostasis of the surgical field is obtained;
13. Surgical planes are closed with a vicryl 3.0 absorbable thread for subcutaneous and with a nylon 4.0 non-absorbable thread for skin;
14. Sterile bandages and dressing is placed.

Discussion

The lack of identification of when other joints are involved in calcaneonavicular coalition may result in persisting


symptoms and surgical failure. Although its true incidence is unknown, between 3.8% to 20% of patients with tarsal coalition have multiple affected joints⁽¹²⁾. For this reason, sectional imaging methods (such as CT and MRI) provide additional information for diagnostic complementation and give evidence on possible associated joints.

Therefore, these imaging tests make surgical planning more accurate, facilitating the selection of the incision technique and reducing the possibilities of maintaining abnormal tissue and resecting healthy tissue, with better surgical results.

In a clinical retrospective study with 30 patients with symptomatic tarsal coalition (14 patients with conservative treatment and 16 with surgical treatment) analyzed whether there were changes in pain levels after treatment, and concluded that, in patients with high pain levels at baseline, these were gradually intensifying during conservative treatment, and showed a drastic improvement in pain intensity after surgical treatment, whereas patients with low pain levels at baseline are likely to improve pain intensity throughout the conservative treatment⁽¹³⁾. With these results, it could be deduced that patients with low intensity pain at the onset of symptoms could respond to conservative treatment more adequately than patients with high intensity pain; additionally, it is possible to suppose that surgery could be indicated as first-line treatment for these patients.

A historical report from Mitchell and Gibson, who undertook resection without interposition, demonstrated a recurrence rate of 66%⁽¹⁾. In response to those results, Mubarak et al.⁽¹⁴⁾ conducted a retrospective study that found good results using autogenous fat as an interposition graft, showing lower rates of reossification and reoperation compared with the use of extensor digitorum brevis as interposition graft. In another study published by Masquijo et al.⁽¹⁵⁾ reported that using autogenous fat graft and bone wax promoted greater pain relief, higher functional scores, in addition to effectively preventing reossification of coalition compared to the use of the extensor digitorum brevis muscle as interposition graft, but additional studies are needed to assess bone wax as an interposition material. The literature still discusses which would be the best option, but most authors indicate best results when some tissue is interposed.

It is important to emphasize that complete resection of coalition is required for a good outcome. The case reported in this study is a clear example of the existence of calcaneonavicular bars with great amount of plantar and medial bone of difficult visualization. If diagnosis and surgical planning are not thoroughly performed, deeper segments of the coalition or abnormal joints would be maintained, not resolving reduced mobility, inadequate osseous impact, and patient's pain complaints.

Authors' contributions: Each author contributed individually and significantly to the development of this article: METJ *(<https://orcid.org/0000-0002-4249-426X>) conceived and planned the activities that led to the study; wrote the article; participated in the review process; approved the final version; RBS *(<https://orcid.org/0000-0003-1085-0917>) wrote the article; participated in the review process; approved the final version; ALGS *(<https://orcid.org/0000-0002-6672-1869>) wrote the article; participated in the review process; approved the final version; TDF *(<https://orcid.org/0000-0002-9687-7143>) wrote the article; participated in the review process. *ORCID (Open Researcher and Contributor ID) .

References

- Kothari A, Masquijo J. Surgical treatment of tarsal coalitions in children and adolescents. *EFORT Open Rev.* 2020;5(2):80-9.
- Farid A, Faber FWM. Bilateral triple talocalcaneal, calcaneonavicular, and talonavicular tarsal coalition: a case report. *J Foot Ankle Surg.* 2019;58(2):374-6.
- Yildiz KI, Misir A, Kizkapan TB, Keskin A, Akbulut D. Functional and radiological outcomes after tarsal coalition resections: a minimum 5-year follow-up. *J Foot Ankle Surg.* 2019;58(6):1223-8.
- Elis J, Yaniv M, Luger EJ. [Tarsal coalition]. *Harefuah.* 2001;140(8):733-7.
- Kulik SA Jr, Clanton TO. Tarsal coalition. *Foot Ankle Int.* 1996;17(5):286-96.
- Swensen SJ, Otsuka NY. Tarsal coalitions--calcaneonavicular coalitions. *Foot Ankle Clin.* 2015;20(4):669-79.
- Mahan ST, Spencer SA, Vezeridis PS, Kasser JR. Patient-reported outcomes of tarsal coalitions treated with surgical excision. *J Pediatr Orthop.* 2015;35(6):583-8.
- Cass AD, Camasta CA. A review of tarsal coalition and pes planovalgus: clinical examination, diagnostic imaging, and surgical planning. *J Foot Ankle Surg.* 2010;49(3):274-93.
- Lawrence DA, Rolen MF, Haims AH, Zayour Z, Moukaddam HA. Tarsal coalitions: radiographic, CT, and MR imaging findings. *HSS J.* 2014;10(2):153-66.
- Shirley E, Gheorghe R, Neal KM. Results of Nonoperative Treatment for Symptomatic Tarsal Coalitions. *Cureus.* 2018;10(7):e2944.
- Quinn EA, Peterson KS, Hyer CF. Calcaneonavicular coalition resection with pes planovalgus reconstruction. *J Foot Ankle Surg.* 2016;55(3):578-82.
- Masquijo JJ, Jarvis J. Associated talocalcaneal and calcaneonavicular coalitions in the same foot. *J Pediatr Orthop B.* 2010;19(6):507-10.
- Birisik F, Demirel M, Bilgili F, Salduz A, Yeldan I, Ismet Kilicoglu O. The natural course of pain in patients with symptomatic tarsal coalitions: a retrospective clinical study. *Foot Ankle Surg.* 2020;26(2):228-32.
- Mubarak SJ, Patel PN, Upasani VV, Moor MA, Wenger DR. Calcaneonavicular coalition: treatment by excision and fat graft. *J Pediatr Orthop.* 2009;29(5):418-26.
- Masquijo J, Allende V, Torres-Gomez A, Dobbs MB. Fat graft and bone wax interposition provides better functional outcomes and lower reossification rates than extensor digitorum brevis after calcaneonavicular coalition resection. *J Pediatr Orthop.* 2017;37(7):e427-e431.