

## Case Report

# Tendoscopic treatment of acute posterior tibial tendon dysfunction: case report

Daniel Saraiva<sup>1,2</sup> , Markus Knupp<sup>3</sup> , André Sá Rodrigues<sup>1</sup> , Tiago Mota Gomes<sup>2</sup> , Xavier Martin Oliva<sup>2,4</sup> 

1. Hospital da Prelada, Porto, Portugal.

2. Foot and Ankle Unit, Department of Anatomy and Human Embryology, Faculty of Medicine, University of Barcelona, Barcelona, Spain.

3. Mein Fusszentrum, Basel, Switzerland. Faculty of Medicine, University of Basel, Switzerland.

4. Clínica del Remei, Barcelona, Spain.

## Abstract

We present a case of a rheumatoid patient presenting with acute signs of posterior tibial tendon dysfunction (PTTD). Magnetic resonance imaging (MRI) results were inconclusive regarding the grade of posterior tibial tendon (PTT) tear.

We performed posterior tibial tendoscopy, releasing all tendon adhesions, and accomplished complete synovectomy. By the end of the procedure, we observed PTT integrity, normal excursion, and mild tendinosis.

At 24-month follow-up, the Visual Analog Scale for pain (VAS-Pain) decreased from 9 (preoperatively) to 1. The Foot and Ankle Outcome Score (FAOS) increased from 16% (preoperatively) to 94%. Clinically, the patient had a symmetric bilateral heel rise test and no pain over the course of the PTT. A standard radiographic assessment demonstrated a normal foot arch and hindfoot alignment.

This report illustrates how posterior tibial tendoscopy can simultaneously provide accurate diagnosis and surgically address acute PTTD on a rheumatoid patient, relieving symptoms and improving midterm clinical scores.

**Level of Evidence V; Therapeutic Studies; Expert Opinion.**

**Keywords:** Posterior tibial tendon dysfunction; Endoscopy; Treatment outcome.

## Introduction

The posterior tibial tendon (PTT) is commonly affected in chronic rheumatoid arthritis (RA)<sup>(1-3)</sup>. Chronic inflammation causes tenosynovitis, chronic tendinosis, and partial or complete rupture, which can lead to flatfoot<sup>(1-4)</sup>. The diagnosis of posterior tibial tendon dysfunction (PTTD) is based on clinical findings together with a radiographic assessment, initially with standard weight-bearing anteroposterior (AP) and lateral radiographs of the foot and ankle, combined with a long axial view for assessing hindfoot alignment<sup>(2-4)</sup>. Magnetic resonance imaging (MRI) can provide further information on the severity of PTT damage, but its sensibility is commonly affected by chronic local inflammation, as observed in RA<sup>(3,4)</sup>.

Failure of conservative treatment of acute PTTD in patients with RA prompts surgical treatment, which is classically performed by an open approach, with tendon debridement and direct repair, if necessary<sup>(4,5)</sup>. Posterior tibial tendoscopy presents a less invasive endoscopic alternative to traditional

open surgery or steroid injections, with potential benefits that include decreased postoperative pain and fewer postoperative complications such as wound infection or scar contracture<sup>(6-10)</sup>.

We present a case of a patient with a clinical and radiological suspicion of high-grade partial-thickness tear of the PTT, describing the endoscopic approach for diagnosis and treatment, as well as clinical and radiographic outcomes at 2 years follow-up. The patient provided informed consent for the publication of this report.

## Case description

A 68-year-old male patient with long-standing RA was referred to our institution after a gradual onset of pain and swelling of his right ankle over the previous 4 weeks. He did not report prior direct or indirect trauma of his foot or ankle. He had a normal foot arch, no clinical hindfoot valgus, and the bilateral heel rise test demonstrated that he was unable to

Study performed at the Hospital da Prelada, Porto, Portugal.

**Correspondence:** Daniel Saraiva. Rua de Sarmento de Beires, 153 - 4250-449, Porto, Portugal. **Email:** [daniel.saraiva@hospitaldaprelada.pt](mailto:daniel.saraiva@hospitaldaprelada.pt). **Conflicts of interest:** none. **Source of funding:** none. **Date received:** August 13, 2021. **Date accepted:** October 22, 2021. **Online:** December 20, 2021.



invert his right heel. This failure to invert on the heel rise test, on a normally aligned foot and ankle, was an important sign that the PTT was not ruptured and that the intense pain over its course was what probably limited normal foot movement. MRI results demonstrated a large amount of effusion, PTT tenosynovitis, and a suspected high-grade partial-thickness tear (Figure 1). Failure of a 2-week attempt at conservative treatment with oral medication, rest, cryotherapy, and a foot orthosis led to the decision to proceed with surgical treatment.

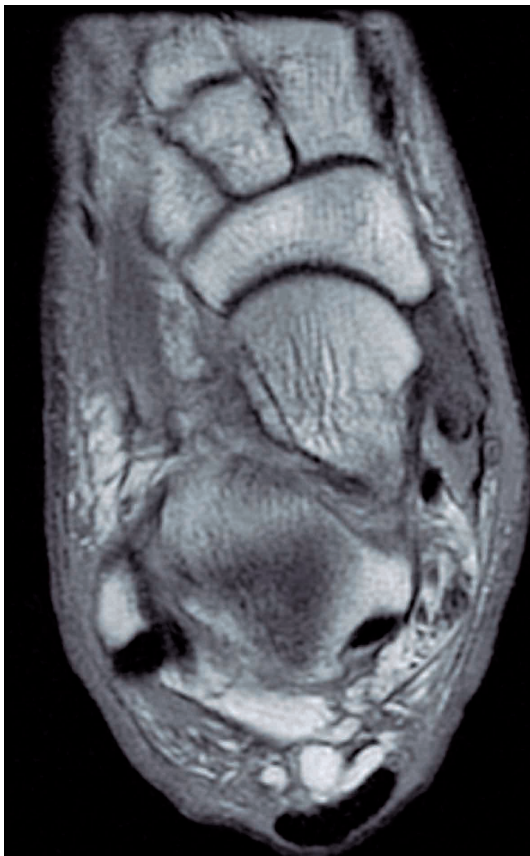Posterior tibial tendoscopy was performed with the patient in the supine position under regional anesthesia with a tight tourniquet, as described by van Dijk et al.<sup>(8)</sup> The distal portal was placed 2 centimeters distal and anterior to the medial malleolar tip, just proximal and above the insertion of the PTT on the navicular bone. After opening the PTT sheath, a 2.7mm 30-degree arthroscope (Dyonics; Smith & Nephew, Memphis, TN) was introduced under 30mmHg fluid pressure. The second portal was placed under direct visual control (Figure 2A). PTT tenosynovitis and adhesences to the tendon sheath were documented. We performed thorough debridement, complete synovectomy, and release

of tendon adhesences with a 2.5mm arthroscopic synovial shaver blade (Smith & Nephew, Memphis, TN) (Figure 2B). By the end of the procedure, we observed a PTT integrity of at least 50% of its thickness, with mild tendinosis and normal excursion (Figure 2C).

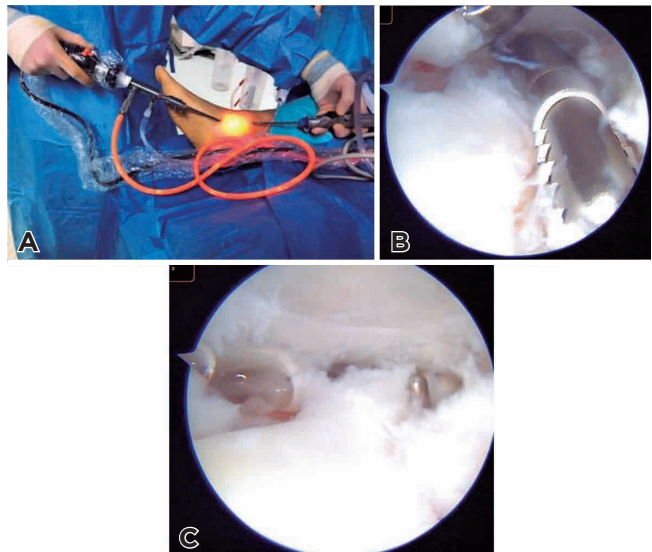
After surgery, protected weightbearing with a walking boot and crutches was prescribed for 2 weeks, with analgesics and anticoagulants. At 2 weeks, we proceeded with suture removal and allowed progressive weightbearing, together with a dedicated physiotherapy regimen for 6 weeks.

The pain level was measured using the Visual Analog Scale for pain (VAS-Pain), which ranges from 0 (no pain) to 10 (maximum pain). Functional evaluation was performed using the Foot and Ankle Outcome Score (FAOS), comprising 42 questions and 5 subscales: pain, symptoms, quality of life, daily activities, and sport activities. This score ranges from 0 to 100 and higher scores indicate better clinical outcomes.

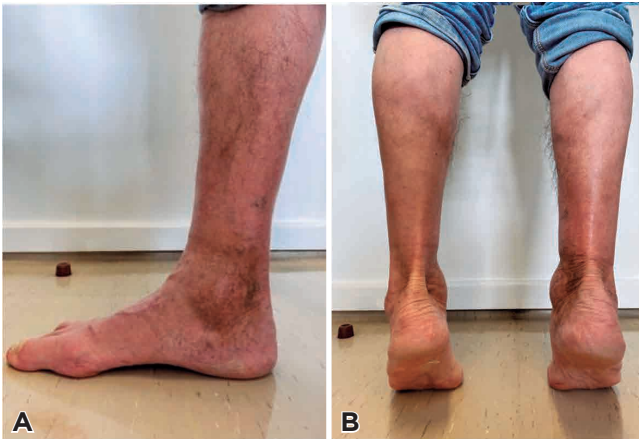At 24-month follow-up, the VAS-Pain decreased from 9 (preoperatively) to 1. The FAOS increased from 16% (preoperatively) to 94%, scoring zero on all items of the quality of life subscale. The patient progressively returned to his normal routine and only reported slight pain over the course of the PTT. No swelling was observed on the medial retromalleolar region of the ankle, the foot had a normal arch, and he had a positive, symmetric bilateral heel rise test (Figures 3A and 3B). Weight-bearing AP and lateral radiographs of the foot and ankle, as well as a long axial view, demonstrated normal foot arch and hindfoot alignment (Figures 4A and B).



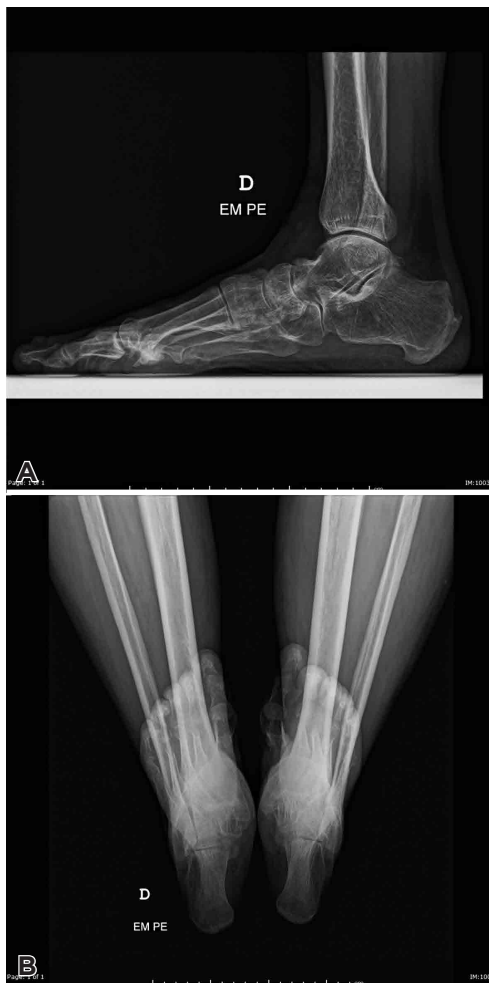**Figure 1.** Axial proton-density weighted MRI revealing a large amount of effusion, tenosynovitis, and a suspected high-grade partial-thickness tear of the PTT.



**Figure 2.** A) Posterior tibial tendoscopy of the right foot with the arthroscope placed in the distal portal and the arthroscopic synovial shaver blade placed in the proximal portal; B) intraoperative image documenting synovectomy and release of tendon adhesences with a 2.5mm arthroscopic synovial shaver blade; C) PTT integrity of at least 50% of its thickness, with mild tendinosis and normal excursion with the arthroscopic probe.



**Figure 3.** Two-year postoperative images of the right foot and ankle demonstrating A) a normal arch and no swelling on the medial retromalleolar region of the ankle and B) a symmetric bilateral heel rise test.



**Figure 4.** A) Weightbearing lateral and B) long axial view radiographs of the foot and ankle, demonstrating a normal foot arch and hindfoot alignment.

## Discussion

RA is a chronic inflammatory disease that can lead to acute or chronic joint and tendon pathologies<sup>(1,2)</sup>. PTT is often involved in RA and, in a recent publication by Harman et al., posterior tibial tenosynovitis was demonstrated to be significantly more prevalent in rheumatoid patients than in patients with other rheumatic diseases such as gout or spondyloarthropathies<sup>(1)</sup>.

In our report, we had a strong suspicion of PTT damage due to the patient's history of long-standing RA, together with clinical findings such as pain and swelling over the medial retromalleolar area combined with the patients' inability to perform the bilateral heel rise test. The presence of a normal foot arch and the absence of hindfoot valgus provided a positive outlook regarding the status of the PTT, indicating acute (and possibly reversible) PTTD. It was critical to differentiate this acute PTTD from chronic flatfoot, a condition frequently observed in rheumatoid patients<sup>(2,3)</sup>. In 1995, Michelson et al.<sup>(2)</sup> found that the combination of loss of foot arch support, lack of palpable posterior tendon, and inability to perform a single-leg heel rise were the most rigid criteria for the clinical diagnosis of PTTD in a group of 99 patients with RA.

Our initial basic radiographic assessment demonstrated a normally aligned foot and ankle. MRI results were inconclusive regarding the grade of the tear, which is a rare event when considering the high sensitivity of this examination; this was probably due to intense synovial proliferation around the PTT. Accordingly, Bouysset et al.<sup>(3)</sup> described a series of 67 rheumatoid feet and found that PTT tears were common in rheumatoid patients presenting with flat feet, but most were incomplete tears.

Classic PTT debridement through an open medial approach was proven to be a successful technique according to previous reports<sup>(4,5)</sup>. Hasler et al.<sup>(4)</sup> reported on a case of a rheumatoid patient with a high suspicion of complete PTT rupture on MRI and found an intact tendon after open synovectomy. Tokunaga et al.<sup>(5)</sup> described a series of 3 patients who underwent surgery for PTTD and found that open synovectomy and release of the PTT improved ankle swelling and pain, with an increase in the American Orthopaedic Foot and Ankle Scale (AOFAS) score from a mean 58.3 to a mean 90.3 postoperatively. Despite these good results, it must be kept in mind that rheumatoid patients with a long history of systemic or local steroid application are more likely to suffer from wound healing problems when an open technique is performed, meaning that the endoscopic approach can be a better option on this particular subset of patients<sup>(2,3)</sup>. Another advantage of posterior tibial tendoscopy is that it advantageously replaces steroid injections, which can lead to tendon rupture since they promote collagen disorganization and present tenocyte toxicity<sup>(6)</sup>.

Posterior tibial tendoscopy was first described by Wertheimer et al.<sup>(7)</sup> in 1995 in a case report of a tendon sheath opening through a two-incision endoscopic approach. This technique was later supported by the report of a cadaveric study and a clinical prospective study by van Dijk et al.<sup>(8)</sup> In 2014, a com-


prehensive review on foot and ankle tendoscopy by Cychosz et al.<sup>(9)</sup> concluded that PTT debridement and synovectomy by an endoscopic technique was a useful and safe procedure.

Posterior tibial tendoscopy was proven to be a powerful diagnostic tool by Gianakos et al.<sup>(10)</sup>, who found that tendoscopy was more sensitive than MRI in PTTD diagnosis. In 2018, Bernasconi et al.<sup>(11)</sup> described surgical results of posterior tibial tendoscopy in 16 patients with stage II PTTD and found that, at 2-year follow-up, 80% of the patients were relieved from symptoms. Also in 2018, an update on tendoscopy of the Achilles, peroneal, and tibialis posterior tendons found this procedure reliable and promising for different disorders around the foot and ankle<sup>(12)</sup>. It must be stressed that, as reported, this technique is limited to cases of no or very little

foot and ankle malalignment<sup>(10,11)</sup>. In presence of mechanical failure, with longitudinal arch collapse and hindfoot valgus, it is imperative to perform a bony realignment procedure. Our case is in line with these previous reports, demonstrating good results in a rheumatoid patient. Future studies with more patients could bring stronger evidence of the use of this technique on this particular set of patients.

## Conclusion

This report illustrates how posterior tibial tendoscopy can simultaneously provide accurate diagnosis and surgically address acute PTTD on RA, relieving symptoms and improving midterm clinical scores.

**Authors' contributions:** Each author contributed individually and significantly to the development of this article: DS \*(<https://orcid.org/0000-0002-6178-8263>) Conceived and planned the activities that led to the study, interpreted the results of the study, participated in the review process and approved the final version, performed the surgery and data collection; MK \*(<https://orcid.org/0000-0002-8260-9500>) Conceived and planned the activities that led to the study, interpreted the results of the study, participated in the review process and approved the final version; ASR \*(<https://orcid.org/0000-0002-9703-5589>) Conceived and planned the activities that led to the study, interpreted the results of the study, participated in the review process and approved the final version, performed the surgery and data collection; TMG \*(<https://orcid.org/0000-0002-7199-5389>) Conceived and planned the activities that led to the study, interpreted the results of the study, participated in the review process and approved the final version; XMO \*(<https://orcid.org/0000-0003-0132-2047>) Conceived and planned the activities that led to the study, interpreted the results of the study, participated in the review process and approved the final version. All authors read and approved the final manuscript. \*ORCID (Open Researcher and Contributor ID) 

## References

1. Harman H, Tekeoglu I. Ankle pathologies in patients with inflammatory rheumatic diseases: a clinical and ultrasonographic study. *Int J Rheum Dis.* 2017;20(6):675-84.
2. Michelson J, Easley M, Wigley FM, Hellmann D. Posterior tibial tendon dysfunction in rheumatoid arthritis. *Foot Ankle Int.* 1995; 16(3):156-61.
3. Bouysset M, Tebib J, Tavernier T, Noel E, Nemoz C, Bonnin M, et al. Posterior tibial tendon and subtalar joint complex in rheumatoid arthritis: magnetic resonance imaging study. *J Rheumatol.* 2003; 30(9):1951-4.
4. Hasler P, Hintermann B, Meier M. Posterior tibial tendon dysfunction and MR imaging in rheumatoid arthritis. *Rheumatol Int.* 2002; 22(1):38-40.
5. Tokunaga D, Hojo T, Takatori R, Ikoma K, Nagasawa K, Takamiya H, et al. Posterior tibial tendon tenosynovectomy for rheumatoid arthritis: a report of three cases. *Foot Ankle Int.* 2006;27(6):465-8.
6. Dean BJ, Lostis E, Oakley T, Rombach I, Morrey ME, Carr AJ. The risks and benefits of glucocorticoid treatment for tendinopathy: a systematic review of the effects of local glucocorticoid on tendon. *Semin Arthritis Rheum.* 2014;43(4):570-6.
7. Wertheimer SJ, Weber CA, Loder BG, Calderone DR, Frascone ST. The role of endoscopy in treatment of stenosing posterior tibial tenosynovitis. *J Foot Ankle Surg.* 1995;34(1):15-22.
8. van Dijk CN, Kort N, Scholten PE. Tendoscopy of the posterior tibial tendon. *Arthroscopy.* 1997;13(6):692-8.
9. Cychosz CC, Phisitkul P, Barg A, Nickisch F, van Dijk CN, Glazebrook MA. Foot and ankle tendoscopy: evidence-based recommendations. *Arthroscopy.* 2014;30(6):755-65.
10. Gianakos AL, Ross KA, Hannon CP, Duke GL, Prado MP, Kennedy JG. Functional Outcomes of Tibialis Posterior Tendoscopy With Comparison to Magnetic Resonance Imaging. *Foot Ankle Int.* 2015;36(7):812-9.
11. Bernasconi A, Sadile F, Welck M, Mehdi N, Laborde J, Lintz F. Role of Tendoscopy in Treating Stage II Posterior Tibial Tendon Dysfunction. *Foot Ankle Int.* 2018;39(4):433-42.
12. Bernasconi A, Sadile F, Smeraglia F, Mehdi N, Laborde J, Lintz F. Tendoscopy of Achilles, peroneal and tibialis posterior tendons: An evidence-based update. *Foot Ankle Surg.* 2018;24(5):374-82.