

## Special Article

# Hallux Arthrodesis

Jesús Vilá y Rico<sup>1,2,3</sup> , Yolanda Hernanz<sup>1</sup> , Ana Abarquero-Diezhandino<sup>1,2</sup> 

1. Hospital Universitario 12 de octubre, Madrid, Spain.

2. Hospital Quirónsalud Ruber, Madrid, Spain.

3. Universidad Complutense de Madrid, Madrid, Spain.

## Abstract

*Hallux* arthrodesis is a prominent technique, both in primary surgery and in reoperations. New devices and instruments have significantly improved outcomes, minimizing complications, although it is a demanding intervention from the technical point of view and not exempt from complications. Arthrodesis is indicated in cases of primary or secondary *hallux rigidus*, and also as a salvage surgery for previous failed treatments such as joint sparing osteotomies or arthroplasty. Proper arthrodesis positioning is important, maintaining a dorsiflexion of 10-15° with a *hallux valgus* angle of nearly 10° and neutral rotation, in order to prevent complications such as *hallux varus* or interphalangeal joint arthritis. Arthrodesis outcomes are excellent from the clinical-functional and radiological point of view, with a union rate of 93.5%; however, this technique is not exempt from complications such as nonunion, malunion, need for hardware removal, and skin and healing problems. Nonetheless, this technique provides excellent outcomes.

**Level of Evidence V; Therapeutic Studies; Expert Opinion.**

**Keywords:** Arthrodesis; Hallux rigidus; Metatarsophalangeal joint.

## Introduction

*Hallux rigidus* is defined as a metatarsophalangeal (MTP) and metatarsosesamoid arthritis of the great toe that causes limited mobility, especially in dorsiflexion range of motion. As a consequence, patients experience changes in gait and pain. During the takeoff phase of gait, or "third rocker", dorsiflexion of 65°-75° of the MTP joint (MTPJ) of the great toe is required<sup>(1)</sup>.

*Hallux rigidus* may be distinguished into primary and secondary. Secondary *hallux rigidus* appears as a sequel of previous surgeries, especially of interventions such as Keller resection arthroplasty or percutaneous surgery, as well as in other conditions such as after trauma or microtrauma, in me-

tabolic changes such as gout, in inflammatory processes such as rheumatoid arthritis or osteochondritis dissecans (Figure 1).

## Methods

### Indications

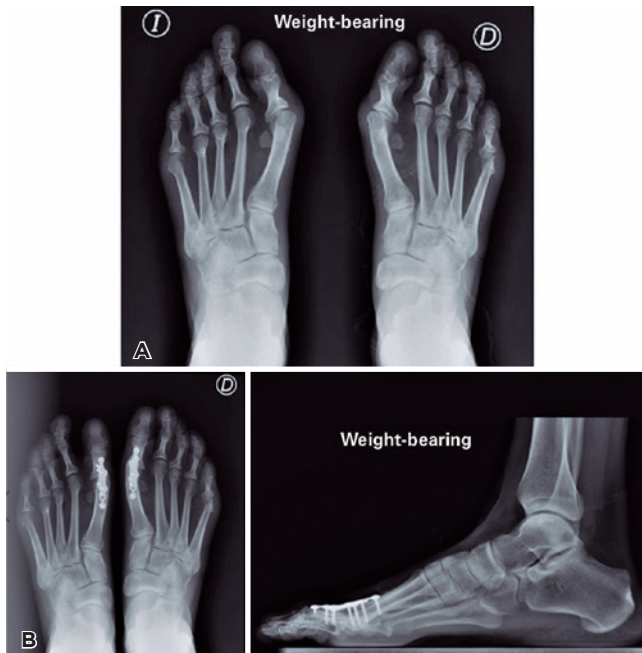
Main indications are primary end-stage *hallux rigidus* (grades III or IV), in cases of secondary hallux rigidus, especially in sequelae of Keller-Brandes-Lelievre resection arthroplasty, minimally invasive percutaneous surgery, or in cases of failure with other techniques for the treatment of *hallux rigidus*, whether joint sparing surgical procedures such as osteotomy or arthroplasty or hemiarthroplasty<sup>(2)</sup>.

Study performed at the Hospital Universitario 12 de octubre, Madrid, Spain.

**Correspondence:** Ana Abarquero-Diezhandino. Hospital Universitario 12 de Octubre. Av. de Córdoba, s/n, 28041. Madrid, Spain. **E-mail:** ana.abarquero@gmail.com. **Conflicts of Interest:** none. **Source of funding:** none. **Date received:** October 16, 2021. **Date accepted:** January 28, 2022. **Online:** April 30, 2022.

**How to cite this article:** Vilá y Rico J, Hernanz Y, Abarquero-Diezhandino A. Hallux Arthrodesis. *J Foot Ankle.* 2022;16(1):16-20.





**Figure 1.** A) A 42-year-old patient who presents *hallux rigidus* secondary to percutaneous forefoot surgery with severe degenerative changes and joint incongruence. B) Final radiological outcome after arthrodesis with dorsal plate and concave-convex reaming with proper position both in frontal and sagittal planes.

It is important to maintain a mobile interphalangeal joint for the success of intervention. Arthrolysis may also be performed if necessary.

At the time of selecting the surgical technique, it is essential to assess the size of the proximal phalanx of the *hallux* (P1) in order to perform single- or two-stage arthrodesis, as we will subsequently show. Furthermore, other comorbidities that may be associated with a higher rate of complications should be considered, such as diabetes mellitus, obesity, smoking, vascular diseases, etc.

## Surgical Technique

### Approach

Most cases consist of severe *hallux rigidus* and primary arthrodesis; thus, we recommend using dorsal approach. In reoperations in which medial approach to the MTPJ was previously used, this is the preferred approach. The advantage of dorsal approach is better exposure of the joint; however, if we choose dorsal plaque fixation, the implant is positioned immediately below the extensor tendon of the great toe, with the possible complications resulting from tendon irritation.

### Joint surface preparation

Currently, the most used form of joint preparation are concave-convex reamers, which allows for a greater joint

congruence and the possibility of correcting spatial plane deviations. There are other forms of joint surface preparation, such as simple chondral resection<sup>(3)</sup> with gouge and cartilage excision, planar sections using a saw<sup>(4)</sup>, or minimally invasive arthroscopic<sup>(5)</sup> or percutaneous<sup>(6,7)</sup> techniques.

In a systematic review, Hodel et al.<sup>(6)</sup> concluded that minimally invasive techniques are promising in terms of clinical outcomes, complication rate, and union rate. These techniques have the advantage of leading to fewer soft tissue injuries, and their disadvantages result from poorer osteosynthesis and limitations in placing the *hallux* in the proper position.

We recommend preparation with concave-convex reams and subsequent both stimulation through perforations with the same reaming guide wire on the surfaces of metatarsal head and P1 base. From the technical point of view, it is important to perform reaming directly with the approximate size of reams rather than progressive increasing from an initial small reaming.

### Arthrodesis position

The most commonly accepted position is 10-15° of dorsiflexion with a *hallux valgus* or metatarsophalangeal angle of 0-15° in the axial plane and neutral rotation. Over the last years, there has been a trend to reduce MTPJ dorsiflexion. This optimal position is essential for the correct contact of joint surfaces. Arthrodesis position may be intraoperatively tested using a hard surface and performing a load simulation test. It is important for the nail to be directed towards the zenith, in order to prevent malrotations.

Correct arthrodesis position is important to prevent complications such as *hallux varus* or interphalangeal joint arthritis<sup>(8,9)</sup>.

### Fixation methods

Numerous types of implants have been developed over the last years. In the early 1990's, dorsal plates started to experience a significant growth. Previously, Kirschner wires, cannulated screws, usually crossed, or pines biodegradables had been employed. Several biomechanical studies have endorsed the superiority of plates, whether associated with interfragmentary compression screws or not<sup>(10-12)</sup>. New designs of low-profile plates with the possibility of employing threaded screws increase stability, including in situations of bones with osteoporosis.

Asif et al.<sup>(3)</sup> advocate for the use of cannulated screws, stating that it is a simple technique with a lower economic cost than dorsal plates and with good results in terms of union rate, showing a nonunion rate of 6.6%, although up to 36% of these cases are asymptomatic. Other authors also endorse the use of cross cannulated screws, based on biomechanical stability and union rates<sup>(13-15)</sup>.

Recently, intramedullary devices have been developed for MTPJ fixation. These devices have the advantage of prevented hardware removal related to dorsal plates, and satisfactory outcomes have been published from the clinical point of view and high union rates (95%)<sup>(16)</sup>.

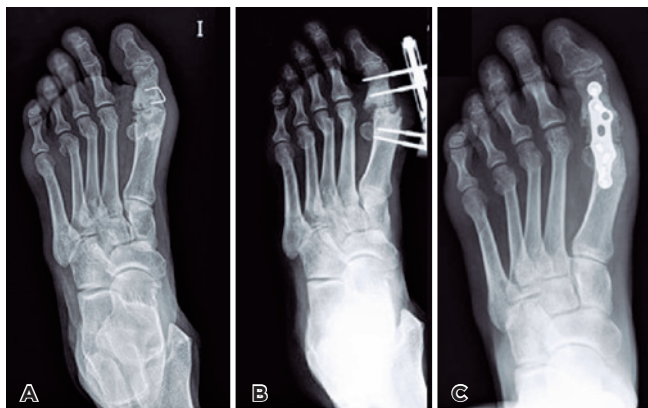
Roukis<sup>(17)</sup> conducted a systematic review of 2,656 arthrodesis procedures performed in cases of *hallux valgus* (47.2%), *hallux rigidus* (32%), rheumatoid arthritis (11.5%), and revision of failed surgery (9.3%) and fixed with cannulated screws, dorsal plaques, and staples. The incidence of nonunion was 5.4%, of malunion was 6.1%, and of hardware removal was 8.5%. The author concluded that union rate is higher when joint surfaces are prepared with low velocity systems and did not find statistically significant differences in fixation when comparing cannulated screws, locked plates, or non-locked plates, with a union rate of 93.5%, showing better results when the procedure is indicated for *hallux rigidus*.

Over the last years, nickel and titanium staples have been increasing popular, with or without shape memory for MTP arthrodesis, isolated or associated with other fixation systems such as screws or intramedullary devices, with good outcomes and high union rates<sup>(18,19)</sup>.

### Arthrodesis - distraction with intercalary graft

In cases of P1 deficiency due to shortening of 2.5-3 cm in length, it will be necessary to a cortico-spongy intercalary graft from the iliac crest and to perform single- or two-stage arthrodesis (Figure 2). The advantage of two-stage surgery with the first stage of surgical debridement, correction of deformity, and placement of a monolateral fixator is preventing neurovascular complications resulting from elongation<sup>(20)</sup>. Gradual elongation is gradually performed at a rate of 2 mm per day, with the close monitoring of toe vascularization of toe vascularization.

Since desired elongation is achieved, a new intervention is conducted after 2-3 weeks, with the removal of fixator through the same incision, resection of fibrous tissue remnants, and



**Figure 2.** Technique of two-stage distraction arthrodesis for *hallux rigidus* as a sequel of Keller-Brandes-Lelievre intervention in a 29-year-old patient. A) initial x-rays. B) first stage of arthrodesis with monolateral Hoffman minifixator. C) final outcome after placement of a cortico-spongy graft and osteosynthesis with a revision dorsal plate.

placement of autologous cortico-spongy bone graft from the iliac crest with the size previously measured between the two bone surfaces.

Afterwards, the entire assembly is stabilized with an appropriately contoured low-profile plate or with the same fixator exerting compression. Stability is greater with the plate. Currently, there are two plates available specific for reoperations that improve stability. Maintaining the external fixator as a definitive treatment is especially indicated in cases of poor soft tissue status or sequelae from infection.

Núñez-Samper and Viladot<sup>(20,21)</sup> published the surgical technique in a series of 40 patients, with satisfactory outcomes from the clinical point of view and a nonunion rate of 7.5%.

### Postoperative care

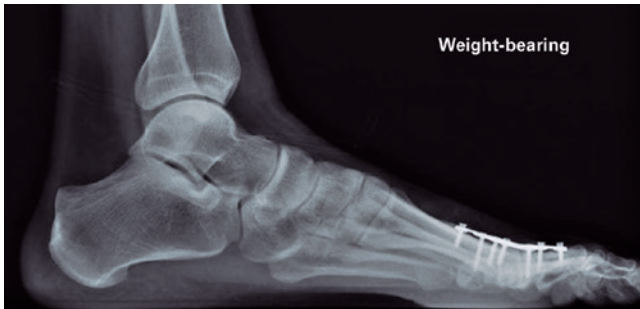Currently, the most spread postoperative protocol allows for immediate partial weight-bearing with rigid shoes during the first 6 weeks and for their subsequent removal and progressive weight-bearing with conventional shoes.

### Discussion

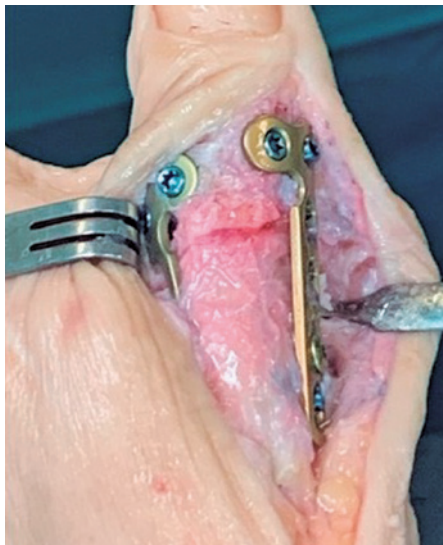
Metatarsophalangeal arthrodesis is the procedure of choice for the surgical correction of severe *hallux valgus* with great MTPJ instability, especially when associated with osteoarthritic degenerative processes or rheumatoid arthritis. It is equally useful and provides good results for first ray reconstruction due to sequelae from previous operations. Moreover, arthrodesis is an excellent option in young active patients, allowing for resumption of sports activities in 88% of patients<sup>(22)</sup>.

Arthrodesis success depends on technical and biological factors. Technical factors include satisfactory joint surface preparation, proper fusion position, and fixation technique. Biological factors include comorbidities (such as inflammatory arthropathy and vascular diseases), regular medications (such as corticosteroids, non-steroidal anti-inflammatory drugs, or immunosuppressive agents) that may impair union, and smoking. Joint surface preparation with cup and cone reamers has the advantage of being versatile in the positioning of fusion site and increasing stiffness at the fusion site<sup>(23)</sup>. The use of planar sections in joint surfaces may increase the area of fusion surface; Politi et al.<sup>(24)</sup> suggest that this preparation provide more stability than conical reaming when oblique compression screws are used for fixation; however, this type of planar preparation predetermines arthrodesis alignment.

Postoperative treatment may also be a determining factor for union success. Ellington et al.<sup>(25)</sup> found a nonunion rate of 12% in patients who started weight-bearing with a boot on the second postoperative week. Hunt et al.<sup>(26)</sup> described a nonunion rate of 23% with locked plate using the same postoperative protocol. Our protocol allows performing partial weight-bearing in the immediate postoperative period with rigid-sole shoes for 6 weeks, which enables earlier mobilization, facilitates patient's discharge on the day of the surgery, allows for an earlier return to work, and does not seem to have an adverse effect on union.



**Figure 3.** Protrusion of locked screws from a dorsal plate.



**Figure 4.** Double plating and grafting in a reoperation for nonunion.

Malunion is not well tolerated by patients<sup>(27)</sup>. Dorsiflexion of less than 10 degrees may increase pressure on the tip of the great toe, whereas excessive dorsiflexion leads to increased pressure below the first metatarsal head. Excessive pronation or medial rotation of the great toe may lead to increased pressure along the medial area.


With regard to the comparison between arthrodesis and total arthroplasty, Gibson and Thomson<sup>(28)</sup> conducted a prospective randomized study (level II) and found that arthrodesis is more effective than total arthroplasty, observing a rate of up to 16% of early failure of MTP prosthesis, establishing a grade of recommendation B or moderate for the treatment of end-stage hallux rigidus (grade IV).

The main complication of arthrodesis is nonunion, whose frequency ranges from 0 to 30%<sup>(29)</sup>. The proper positioning of the *hallux* in the coronal and sagittal planes is essential to the success of intervention and to prevent complications. Most complications of *hallux* arthrodesis are related to technical failures<sup>(30)</sup>. The main complications are nonunion and malunion<sup>(31,32)</sup>. Other complications include problems related to hardware (Figure 3), progression of interphalangeal joint arthritis, and transfer metatarsalgia. The overall incidence of malunion is 6.1%, a phenomenon that 87.1% of the cases result from dorsiflexion position of joint surfaces, which also leads to microtrauma from footwear and presence of subungual ecchymosis. Furthermore, the dorsiflexion position overloads the first metatarsal and the sesamoids, resulting in residual pain. In the coronal plane, excessive abduction damages the skin of the first interdigital space and there is difficulty in wearing shoes due to excessive varus. The nonunion rate of after primary arthrodesis ranges from 0 to 20% in the literature<sup>(19)</sup>. It is critical to perform a correct joint surface preparation until reaching a properly vascularized healthy subchondral bone and an appropriate and stable fixation.

Cases of nonunion should be treated with placement of cortico-spongy graft and stabilization with a revision single dorsal plate, or sometimes double-plating, in order to improve arthrodesis stability<sup>(33)</sup> (Figure 4).

## Conclusions

*Hallux* arthrodesis is the current gold standard, or standard technique, for the treatment of severe symptomatic *hallux rigidus* (grades III and IV). Better outcomes are related with proper fusion positioning (10-15° of dorsiflexion and 10-15° of valgus) and careful joint surface preparation.

Authors' contributions: Each author contributed individually and significantly to the development of this article: JVR \*(<https://orcid.org/0000-0002-8558-0109>) Wrote the article, participated in the review process, bibliographic review, formatting of the article, interpreted the results of the study, performed the surgeries; YH \*(<https://orcid.org/0000-0001-9590-9142>) Participated in the review process, bibliographic review; AAD \*(<https://orcid.org/0000-0001-9729-5471>) Participated in the review process, bibliographic review. All authors read and approved the final manuscript. \*ORCID (Open Researcher and Contributor ID) .

## References

- Viladot-Pericé R, Álvarez-Goenaga F, Formiguera-Sala S. Update on the treatment of hallux rigidus. *Rev OrtopTraumatol.* 2006; 50:233-40.
- Herrera-Pérez M, Andarcia-Bañuelos C, de Bergua-Domingo J, Paul J, Barg A, Valderrabano V. Proposed global treatment algorithm for Hallux rigidus according to evidence-based medicine. *Rev Esp Cir Ortop Traumatol.* 2014;58(6):377-86.



3. Asif M, Qasim SN, Kannan S, Bhatia M. A consecutive case series of 166 first metatarsophalangeal joint fusions using a combination of cup and cone reamers and crossed cannulated screws. *J Foot Ankle Surg.* 2018;57(3):462-5.
4. Korim MT, Mahadevan D, Ghosh A, Mangwani J. Effect of joint pathology, surface preparation and fixation methods on union frequency after first metatarsophalangeal joint arthrodesis: A systematic review of the English literature. *Foot Ankle Surg.* 2017;23(3):189-94.
5. Carro LP, Vallina BB. Arthroscopic-assisted first metatarsophalangeal joint arthrodesis. *Arthroscopy.* 1999;15(2):215-7.
6. Hodel S, Viehöfer A, Wirth S. Minimally invasive arthrodesis of the first metatarsophalangeal joint: A systematic literature review. *Foot Ankle Surg.* 2020;26(6):601-6.
7. De Prado M, Cuervas-Mons M, De Prado V, Golanó P. Minimally invasive management of hallux rigidus. In: Scuderi G, Tria A, editors. *Minimally invasive surgery in orthopedics.* New York: Springer; 2010. p. 75-87.
8. Hamilton GA, Ford LA, Patel S. First metatarsophalangeal joint arthrodesis and revision arthrodesis. *Clin Podiatr Med Surg.* 2009; 26(3):459-73.
9. Coughlin MJ, Shurnas PS. Hallux rigidus. Grading and long-term results of operative treatment. *J Bone Joint Surg Am.* 2003; 85(11):2072-88.
10. Bennett GL, Sabetta J. First metatarsophalangeal joint arthrodesis: evaluation of plate and screw fixation. *Foot Ankle Int.* 2009; 30(8):752-7.
11. Chraim M, Bock P, Alrabai H, Trnka HJ, Alrabai HM, Trnka HJ. Long-term outcome of first metatarsophalangeal joint fusion in the treatment of severe hallux rigidus. *Int Orthop.* 2016;40(11):2401-8.
12. Doty J, Coughlin M, Hirose C, Kemp T. Hallux metatarsophalangeal joint arthrodesis with a hybrid locking plate and a plantar neutralization screw: a prospective study. *Foot Ankle Int.* 2013; 34(11):1535-40.
13. Claassen L, Plaass C, Pastor MF, Ettinger S, Wellmann M, Stukenborg-Colsman C, et al. First metatarsophalangeal joint arthrodesis: a retrospective comparison of crossed-screws, locking and non-locking plate fixation with lag screw. *Arch Bone Jt Surg.* 2017;5(4):221-5.
14. Harris E, Moroney P, Tourne Y. Arthrodesis of the first metatarsophalangeal joint—a biomechanical comparison of four fixation techniques. *Foot Ankle Surg.* 2017;23(4):268-74.
15. Fuld RS 3rd, Kumparatana P, Kelley J, Anderson N, Baldini T, Younger ASE, et al. Biomechanical Comparison of Low-Profile Contoured Locking Plate With Single Compression Screw to Fully Threaded Compression Screws for First MTP Fusion. *Foot Ankle Int.* 2019;40(7):836-44.
16. Singhal R, Kwaees T, Mohamed M, Argyropoulos M, Amarasinghe P, Toh EM. Result of IOFIX (Intra Osseous FIXation) device for first metatarsophalangeal joint arthrodesis: A single surgeon's series. *Foot Ankle Surg.* 2018;24(5):466-70.
17. Roukis TS. Nonunion after arthrodesis of the first metatarsophalangeal joint: a systematic review. *J Foot Ankle Surg.* 2011; 50(6):710-3.
18. Chan JJ, Sarker SS, Nordio A, Guzman JZ, Hasija R, Vulcano E. Failure of fixation with nickel-titanium staples in first metatarsophalangeal arthrodesis with hallux valgus deformity. *Orthopedics.* 2019;42(4):e402-4.
19. Challagundla SR, Thomas R, Ferdinand R, Crane E. First metatarsophalangeal joint arthrodesis using memory staples: clinical and functional results. *Foot Ankle Spec.* 2021;14(5):410-4.
20. Núñez-Samper M, Viladot R, Ponce SJ, Lao E, Souki F. Serious sequelae of the hallux valgus surgery: More options for its surgical treatment. *Rev Esp Cir Ortop Traumatol.* 2016;60(4):234-42.
21. Núñez-Samper M. Tratamiento de las secuelas de la cirugía del 1.º radio. In: Martín Oliva X, Vila y Rico J, Viladot Voegeli A. *Tratado de cirugía de antepié.* Barcelona: Euromedice; 2010. Cap.7. p. 99-112.
22. Da Cunha RJ, MacMahon A, Jones MT, Savenkov A, Deland J, Roberts M, et al. Return to sports and physical activities after first metatarsophalangeal joint arthrodesis in young patients. *Foot Ankle Int.* 2019;40(7):745-52.
23. Curtis MJ, Myerson M, Jinnah RH, Cox QG, Alexander I. Arthrodesis of the first metatarsophalangeal joint: a biomechanical study of internal fixation techniques. *Foot Ankle* 1993;14(7):395-9.
24. Politi J, John H, Njus G, Bennett GL, Kay DB. First metatarsophalangeal joint arthrodesis: a biomechanical assessment of stability. *Foot Ankle Int.* 2003;24(4):332-7.
25. Ellington JK, Jones CP, Cohen BE, Davis WH, Nickisch F, Anderson RB. Review of 107 hallux MTP joint arthrodesis using dome-shaped reamers and a stainless-steel dorsal plate. *Foot Ankle Int* 2010;31(5):385-90.
26. Hunt KJ, Ellington JK, Anderson RB, Cohen BE, Davis WH, Jones CP. Locked versus nonlocked plate fixation for hallux MTP arthrodesis. *Foot Ankle Int.* 2011;32(7):704-9.
27. Coughlin MJ, Saltzman CL, Anderson RB. *Mann's surgery of the foot and ankle.* 9th ed. Philadelphia: Elsevier/Saunders; 2013.
28. Gibson JN, Thomson CE. Arthrodesis or total replacement arthroplasty for hallux rigidus: a randomized controlled trial. *Foot Ankle Int.* 2005;26(9):680-90.
29. Stevens J, de Bot RTA, Hermus JPS, van Rhijn LW, Witlox AM. Clinical Outcome Following Total Joint Replacement and Arthrodesis for Hallux Rigidus: A Systematic Review. *JBJS Rev.* 2017;5(11):e2.
30. Lunati MP, Manz WJ, Maidman SD, Kukowski NR, Mignemi D, Bariteau JT. Effect of Age on Complication Rates and Outcomes Following First Metatarsophalangeal Arthrodesis for Hallux Rigidus. *Foot Ankle Int.* 2020;41(11):1347-54.
31. Deland JT, Williams BR. Surgical management of hallux rigidus. *J Am Acad Orthop Surg.* 2012;20(6):347-58.
32. Galois L, Hemmer J, Ray V, Sirveaux F. Surgical options for hallux rigidus: state of the art and review of the literature. *Eur J Orthop Surg Traumatol.* 2020;30(1):57-65.
33. Bei C, Gross CE, Adams S, Parekh SG. Dual plating with bone block arthrodesis of the first metatarsophalangeal joint: A clinical retrospective review. *Foot Ankle Surg.* 2015;21(4):235-9.