

Special Article

Keller resection arthroplasty

Antonio Viladot Voegeli¹ , Mariano Nuñez-Samper² 

1. Orthopaedic Department, Clínica Tres Torres, Barcelona, Spain.

2. Hospital Virgen del Mar, Madrid, Spain.

Abstract

The resection arthroplasty first described by Keller for *hallux valgus* has subsequently been applied to treat *hallux rigidus*. Some variations to the original procedure have been described, such as the interposition of soft tissue in the resection area (joint capsule, tendon, etc.), as a spacer, in order to reduce the amount of phalanx to be resected and improve stability and mobility. Another procedure, proposed by Valente Valenti, consists of performing a “V” shaped arthrectomy in the sagittal plane, at the level of the metatarsal and the phalanx. We are faithful to the original technique, resecting approximately one third of the phalangeal base and the periarticular osteophytes, seeking for the correct balance between the flexor and extensor muscles of the hallux. Resection arthroplasty is indicated in stage III or in stage III-IV of the Regnaud and Coughlin and Shurnas classifications, respectively. Both in our own experience and when reviewing the bibliography, we find that very acceptable results are obtained.

Level of Evidence V; Therapeutic Studies; Expert Opinion.

Keywords: Hallux rigidus; Arthroplasty; Osteoarthritis.

Introduction

Resection arthroplasty was described by Keller⁽¹⁾ in 1904 for the surgical treatment of *hallux valgus* and subsequently started being used in the treatment of *hallux rigidus*. It bears noting that this technique has yielded better results in the treatment of *hallux rigidus* than in that of *hallux valgus*⁽²⁾.

Some authors⁽³⁾ proposed soft tissue interposition in the resection area, by way of spacer, in order to reduce the amount of phalanx to be resected and improve stability and mobility.

In 1985 Valenti⁽⁴⁾ proposed a change in resection arthroplasty that consisted of performing a V-shaped hinge arthrectomy in the sagittal plane, at the level of the metatarsal and the phalanx. This technique preserves length of first ray and function of *flexor hallucis brevis* and sesamoids.

Indications

Resection arthroplasty, with or without interposition, and Valenti technique, are indicated in advanced disease stages (grade III of the Regnaud classification⁽⁵⁾ and grade III-IV of the Coughlin and Shurnas classification⁽⁶⁾), in which patients feel constant pain during gait, which is often performed in a supine position, and present with plantar keratosis and sig-

nificant joint stiffness. Radiological findings show markedly reduced or absent joint space, deformities of the phalangeal base, great osteophytic reaction, and periarticular osteoarthritic sclerosis, behaving as a true “joint disease”.

For the surgical treatment in these stages, basically three techniques have been proposed: arthrodesis, arthroplasty with partial or complete prosthesis, and resection arthroplasty, which is the object of the present study.

For many authors^(7,8), metatarsophalangeal arthrodesis is the technique of choice, despite presenting a series of complications⁽⁹⁻¹¹⁾. These complications have an increased incidence in older patients and in those with inflammatory diseases, such as rheumatoid arthritis, or with diabetes⁽¹²⁾.

Metatarsophalangeal prostheses, either total or partial, are techniques currently under development. In the literature published so far, there are no satisfactory medium-long term outcomes^(7,13).

Surgical technique

To obtain good results with the Keller technique (Figure 1), several important technical details should be considered:

Study performed at the Hospital Virgen del Mar, Madrid, Spain.

Correspondence: Antonio Viladot Voegeli. **Address:** C. de Honduras, 14, 28016, Madrid, Spain. **E-mail:** 9393avv@gmail.com. **Conflicts of Interest:** none. **Source of funding:** none. **Date received:** October 24, 2021. **Date accepted:** February 8, 2022. **Online:** April 30, 2022.

How to cite this article: Viladot Voegeli A, Nuñez-Samper M. Keller resection arthroplasty. J Foot Ankle. 2022;16(1):12-5.



- *Avoid excessive resection.* It is usually sufficient to resect one-third of the phalanx, so that to prevent *hallux* instability.
- *Seek for sufficient resection.* This prevents postoperative joint stiffness and recurrence. At the end of the procedure, it is important to check joint mobility.
- At the end of intervention, there should be a *balance between flexor and extensor muscles.* Flexor insufficiency leads to flaccid *hallux* in the capacity of impulse in the third rocker of the gait. Extensor predominance will lead to claw *hallux* and valgus deviation. In order to prevent these complications, extensor elongation should be performed, if necessary, and the plantar plate should always be anchored to the flexor hallucis longus to maintain the flexor strength of the toe.
- *Hallux rigidus* usually appears in an Egyptian forefoot or in a square forefoot; therefore, phalangeal resection, if properly performed, does not cause excessive shortening of the *hallux* in relation to the second toe. The Keller technique should be ruled out in some cases when the *hallux* is preoperatively much shorter than the second toe (Greek forefoot), due to the esthetic and functional problem that it causes.

If soft tissue interposition arthroplasty is indicated, several surgical options are available, which use different bioimplants:

- *Resection arthroplasty with capsular interposition*⁽¹⁴⁾: the classical Keller technique is combined with the interposition of the dorsal capsule and the extensor *hallucis brevis* tendon.
- *Semitendinosus tendon allograft arthroplasty*⁽¹⁵⁾: this technique, which uses cryopreserved semitendinosus tendon, may be a salvage option for failed procedures in *hallux rigidus* surgery.
- *Tendon allograft arthroplasty of the metatarsophalangeal joint*⁽¹⁶⁾ consists of interposing the tendon allograft rolled in the form of an “anchovy” within the joint. Subsequently, the interposition graft is stabilized through a bone tunnel and suture anchors.

- *Soft tissue interposition arthroplasty.* Arthroplasty with interposition of autogenous soft tissue is another option proposed as an alternative to arthrodesis, due to its safety and efficacy, as presented by Schenk et al.⁽¹⁷⁾ in their studies.
- *Interposition arthroplasty using a regenerative tissue matrix.* In this procedure, a human acellular dermal regenerative matrix is used as an interposition graft (*Allo-derm*). Berlet et al.⁽¹⁸⁾ confirmed good outcomes with this technique.

As an anecdote, it is worth remembering that a procedure of metallic interposition arthroplasty, named “en Bouchon”, was used in France some years ago, consisting of the placement of a metallic button that was stabilized with a Kirschner needle. The needle and then the implant were removed after some weeks. This technique is not currently used.

In Valenti resection arthroplasty, osteotomy is performed with cuneiform resection of the metatarsal head at an angle of 45°, starting behind dorsal exostosis, directed from dorsal to plantar and from proximal to distal. Next cuneiform resection at an angle of 45° is performed on the phalangeal base, directed from dorsal to plantar and from distal to proximal. Subsequently, sesamoids are released and corrected. At the end of the surgery, *hallux* dorsiflexion should reach 90°.

Results

Good results have been published in the literature^(19,20) when the Keller technique is successfully conducted. Our personal experience is also favorable. In 2005, Gasch-Blasi et al.⁽²¹⁾ conducted a long-term review of 48 feet with a mean follow-up of 121 months (minimum 60 months, maximum 216 months). They found that 92% of patients were satisfied with the procedure and, considering the result, would undergo surgery again, and that the 8% of dissatisfied patients presented with recurrence of clinical manifestations.

We agree with Jahss⁽²²⁾ that the poor outcomes that are attributed to the Keller technique in *hallux rigidus* may be in fact attributable to a poor execution of the surgical technique rather than to the technique itself.

An interesting study by O’Doherty et al.⁽²³⁾ compared the results of metatarsophalangeal arthrodesis with those of Keller resection arthroplasty. The authors highlight the great patients’ satisfaction with both techniques and did not find differences in terms of pain relief, improved gait, comfort with shoes, and transfer metatarsalgia. According to these authors, with whose opinion we agree, the advantages of the Keller technique lie in its simplicity, its more comfortable postoperative period for the pain, its low level of reoperation (in their series, nonunion was found in 44% of arthrodesis procedures, although most of them were asymptomatic).

With regard to interposition arthroplasty, despite the theoretical advantages of the modified technique, some authors did not find better outcomes compared with those of the traditional Keller technique⁽¹⁷⁾. In a clinical and radiological study, Watson et al.⁽¹⁴⁾ compared 22 feet treated with interposition arthroplasty with 30 feet subjected to the traditional Keller

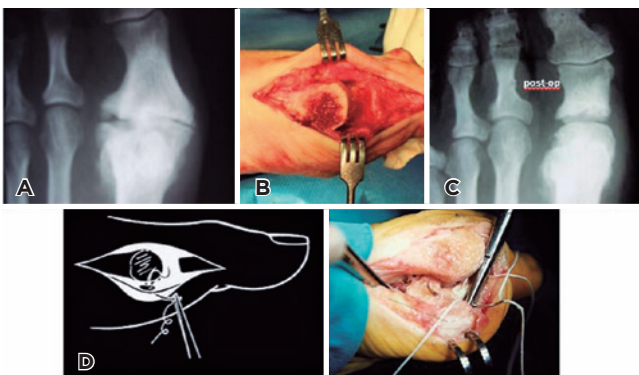


Figure 1. Keller technique. A) Preoperative radiograph; B) Surgical photograph of resection; C) Postoperative radiograph; D) Anchor of the flexor hallucis longus to the plantar plate, maintaining Hallux flexor strength.

procedure. The authors did not observe any statistically significant difference between the two groups in terms of patients' satisfaction.

As for the Valenti technique, there are few studies published in the literature, but the scarce results published so far are very similar.

In a review study conducted by Colò et al.⁽²⁴⁾ analyzed 8 articles, for a total of 347 patients, and a mean follow-up of 6±7 years. They did not find substantial differences in clinical outcomes between the original and modified techniques.

Complications

The most frequent complications of resection arthroplasty are (Figure 2):

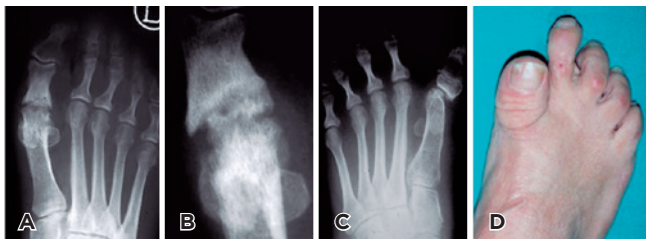

Figure 2. Complications of the Keller technique. A) Stiffness; B) Necrosis; C) Instability and secondary deviation; D) Excessively short *Hallux*


- *Joint Instability*, usually related to excessive resection of the phalanx. It leads to dorsiflexion valgus deformity of the *hallux*, to a flaccid toe that is unable to touch the ground and to perform the third rocker of gait, and to transfer metatarsalgia.
- *Joint stiffness and secondary arthrosis*, both related insufficient resection of the phalangeal base.
- *Avascular necrosis* of the metatarsal head, caused by excessive release of soft tissues and section of the vascular plantar package.
- *Esthetic problems*. In some cases, there is excessive shortening of the *hallux* in relation to the second toe.

Interposition arthroplasty may present the same complications, in addition to soft tissue reactions or failure of biological material.

The Valenti technique does not involve shortening of the ray; however, in addition to the previously described complications, sesamoiditis is a relatively frequent problem (7.4%), although it is often transient⁽²⁵⁾.

Conclusion

We believe that Keller resection arthroplasty, with or without interposition, and the Valenti technique are the techniques of choice in older patients with end-stage *hallux rigidus* and severe joint involvement.

Authors' contributions: Each author contributed individually and significantly to the development of this article: AVV *(<https://orcid.org/0000-0002-4192-6163>) Conceived and planned the activities that led to the study, interpreted the results of the study, performed the surgeries and data collection, survey of the medical records, and approved the final version; MNS *(<https://orcid.org/0000-0001-9398-0375>) Participated in the review process, statistical analysis, bibliographic review and formatting of the article, clinical examination. All authors read and approved the final manuscript. *ORCID (Open Researcher and Contributor ID) .

References

1. Keller WL. Surgical treatment of bunions and hallux valgus. *New York Med J.* 1904;80:741.
2. Wrighton JD. A ten-year review of Keller's operation. *Review of Keller's operation at the Princess Elizabeth Orthopaedic Hospital, Exeter. Clin Orthop Relat Res.* 1972;89:207-14.
3. Hamilton WG, O'Malley MJ, Thompson FM, Kovatis PE. Roger Mann Award 1995. Capsular interposition arthroplasty for severe hallux rigidus. *Foot Ankle Int.* 1997;18(2):68-70.
4. Valenti V. L'artrectomia "a cerniera" di valenti nel trattamento chirurgico dell'alluce rigido. *Chir Piede.* 1985;9:261-6.
5. Regnaud B. *The foot: pathology, etiology, semiology, clinical investigation and therapy.* Berlin: Springer Verlag; 1986.
6. Coughlin MJ, Shurnas PS. Hallux rigidus. Grading and long-term results of operative treatment. *J Bone Joint Surg Am.* 2003; 85(11):2072-88.
7. Simpson GA, Hembree WC, Miller SD, Hyer CF, Berlet GC. Surgical strategies: hallux rigidus surgical techniques. *Foot Ankle Int.* 2011;32(12):1175-86.
8. Deland JT, Williams BR. Surgical management of hallux rigidus. *J Am Acad Orthop Surg.* 2012;20(6):347-58.
9. Lombardi CM, Silhanek AD, Connolly FG, Dennis LN, Keslonsky AJ. First metatarsophalangeal arthrodesis for treatment of hallux rigidus: a retrospective study. *J Foot Ankle Surg.* 2001; 40(3):137-43.
10. Goucher NR, Coughlin MJ. Hallux metatarsophalangeal joint arthrodesis using dome-shaped reamers and dorsal plate fixation: a prospective study. *Foot Ankle Int.* 2006;27(11):869-76.
11. Roukis TS. Nonunion after arthrodesis of the first metatarsophalangeal joint: a systematic review. *J Foot Ankle Surg.* 2011; 50(6):710-3.

12. Anderson JJ, Rowe GP, Hansen M. Complication rates in diabetics with first metatarsophalangeal joint arthrodesis. *Diabetic Foot Ankle*. 2014;5:246-49.
13. Fuhrmann RA, Wagner A, Anders JO. First metatarsophalangeal joint replacement: the method of choice for end-stage hallux rigidus?. *Foot Ankle Clin* 2003;8(4):711-21.
14. Watson TS, Panicco J, Parek H. Allograft tendon interposition arthroplasty of the hallux metatarsophalangeal joint: a technique guide and literature review. *Foot Ankle Int*. 2019;40(1):113-9.
15. Miller D, Maffulli N. Fee gracilis interposition arthroplasty for severe hallux rigidus. *Bull Hosp Jt Dis*. 2005;62(3-4):121-4.
16. Thomas D, Thordarson D. Rolled Tendon Allograft Interposition Arthroplasty for Salvage Surgery of the Hallux Metatarsophalangeal Joint. *Foot Ankle Int*. 2018;39(4):458-62.
17. Schenk S, Meizer R, Kramer R, Aigner N, Landsiedl F, Steinboeck G. Resection arthroplasty with and without capsular interposition for treatment of severe hallux rigidus. *Int Orthop*. 2009;33(1):145-50.
18. Berlet GC, Hyer CF, Lee TH, Philbin TM, Hartman JF. Active Interpositional arthroplasty of the first MTP joint. A regenerative tissue matrix for the treatment of advanced hallux rigidus *Foot Ankle Int*. 2008;29(1):10-21.
19. Easley ME, Anderson RB. Hallux rigidus in the adult and adolescent. In: Adelaar R, editor. *Disorders of the Great Toe*. Rosemont, IL: American Academy Orthopaedic Surgeons; 1997. p. 23-32.
20. Schneider W, Kadnar G, Kranzl A, Knahr K. Long-term results following Keller resection arthroplasty for hallux rigidus. *Foot Ankle Int*. 2011;32(10):933-9.
21. Gasch-Blasi J, Marzal E, Viladot-Voegeli A. Resultados de la técnica de Brandes-Keller para la corrección del hallux rigidus. In: *Actas del 27 Congreso Nacional AEMCP*. Madrid: AEMCP; 2005. p. 60.
22. Jahss MH. Editorial. *Foot Ankle*. 1984;4:227-8.
23. O'Doherty DP, Lowrie IG, Magnussen PA, Gregg PJ. The management of the painful first metatarsophalangeal joint in the older patient. Arthrodesis or Keller's arthroplasty? *J Bone Joint Surg Br*. 1990;72(5):839-42.
24. Colò G, Samaila EM, Magnan B, Felli L. Valenti resection arthroplasty for hallux rigidus: A systematic review. *Foot Ankle Surg*. 2020;26(8):838-44.
25. Harisboure A, Joveniaux P, Madi K, Dehoux E. The Valenti technique in the treatment of hallux rigidus. *Orthop Traumatol Surg Res*. 2009;95(3):202-9.