

Technical Tips

Comminuted navicular fracture treated with an internal fixation plate – Technical Tip

Henrique Mansur^{1,2} , Landweherle de Lucena da Silva² , Daniel Augusto Maranhão³ 

1. Department of Orthopaedics Surgery, Hospital Santa Helena, Brasília, DF, Brazil.

2. Department of Orthopaedics Surgery Hospital Regional do Gama, Gama, DF, Brazil.

3. Department of Orthopaedics Surgery, Hospital Sírío-Libanês, Brasília, DF, Brazil.

Abstract

Fractures of the navicular are relatively uncommon lesions. Comminuted fractures of the navicular body may be associated with focal bone collapse and loss of integrity of the medial column of the midfoot with gross instability, leading to deformities and potential early osteoarthritis. The treatment is challenging due to the difficulties to maintain the length and stability of the midfoot medial column and restoring the anatomy without damaging the vascular supply. Here we present an option for the surgical treatment of comminuted fractures of the navicular using a low-profile locking plate with the “bridge” principle as a temporary internal fixator. The technique consists of restoring the navicular anatomy by fixing the larger fragments with screws and applying indirect reduction of minor fragments. The bone length is maintained by a bridge-plating system with screws inserted into the talus and the medial cuneiform, crossing the talonavicular and naviculocuneiform joints. Implants are removed after fracture healing.

Level of Evidence V; Therapeutic Study; Expert Opinion.

Keywords: Tarsal bones; Fractures, bone; Foot injuries; Diagnostic techniques, surgical.

Introduction

Fractures of the navicular are relatively uncommon lesions resulting from acute injuries or chronic overloading⁽¹⁾. The talus and the midfoot cuneiform bones compress the navicular with a combination of forces that may result in transverse fractures towards the plantar navicular aspect and superior displacement of the dorsal fragment⁽²⁾. The fractures of the navicular body with comminution or joint displacement may be associated with bone collapse and/or loss of integrity of the medial midfoot column. Moreover, they are frequently associated with gross instability, progressing to potentially severe deformities with flattening of the midfoot arch^(1,3). Even following adequate treatment, patients may experience chronic pain, disability, early osteoarthritis, and loss of quality of life⁽¹⁻⁵⁾.

Surgical treatment is recommended for the displaced and comminuted fractures of the navicular to restore the articular surface, the length of the medial column, and the anatomical relationship between the hindfoot and the forefoot⁽¹⁻⁵⁾. The decision-making criteria include articular displacement

>2 mm, shortening of the medial column >3 mm, subluxation or dislocation, open fracture, compartment syndrome, and risk of skin lesion due to an overlying bone fragment^(1,5,6). Simple and noncomminuted displaced fractures may be treated with open or closed reduction followed by fixation with isolated screws or plate and screw systems. However, comminuted fractures are challenging, requiring additional stability to maintain the length of the medial column, including external or internal fixation, Kirschner wires, and, in some cases, bone grafting^(1,2,5). As these lesions are uncommon, the literature reporting treatment details is relatively scarce.

This study aims to present an option for the surgical treatment of comminuted fractures of the navicular based on the use of a low-profile locking plate with the “bridge” principle as a temporary internal fixator. The technique consists of (1) restoring the navicular morphology by open reduction, (2) fixing the larger articular fragments with lag screws, and (3) positioning a plate that crosses the talonavicular and naviculocuneiform joints, with proximal screws inserted into the talus and distal screws into the medial cuneiform.

Study performed at the Hospital Santa Helena, Brasília, DF, Brazil.

Correspondence: Henrique Mansur. SMHN Quadra 2 - Centro Clínico Cléo Octávio - Asa Norte, 70710-146, Brasília, DF, Brazil. **E-mail:** drhenriquemansur@gmail.com.

Conflicts of Interest: none. **Source of funding:** none. **Date received:** February 08, 2022. **Date accepted:** March 23, 2022. **Online:** April 30, 2022.



Case presentation

The technique is indicated for comminuted and displaced fractures of the navicular body (type 3 in the classification of Sangeorzan et al.⁽⁷⁾) with subluxation of the dorsal fragment of the navicular or comminution of the plantar fragment resulting in loss of integrity of the medial column.

To illustrate the technique, we describe a case of a patient who had a motorcycle fall injury and sustained a comminuted and displaced fracture of the navicular. The dorsomedial fragment was displaced dorsally, with impaction of the dorsomedial articular surface of the talonavicular joint. The plantar-lateral fragment of the navicular was displaced with shortening of the medial column of the midfoot (Figures 1 and 2). The surgical strategy was to reduce major fragments through a direct dorsomedial approach, restoring articular talonavicular and naviculocuneiform surfaces with interfragmentary compression screws. Subsequently, a dorsal bridge plate crossing the navicular fracture was inserted to maintain the length of the medial column and indirectly reduce the comminuted fragments (Figures 3 and 4).

Surgical technique

1. The surgical procedure was performed with the patient in the supine position under spinal anesthesia in combination with peripheral sciatic and popliteal nerve block;
2. A pneumatic tourniquet was positioned proximally at the thigh and inflated to the pressure of 300 mm Hg (after Esmarch exsanguination);
3. A direct dorsomedial straight incision of 8 cm was performed from the talus neck to the medial cuneiform;

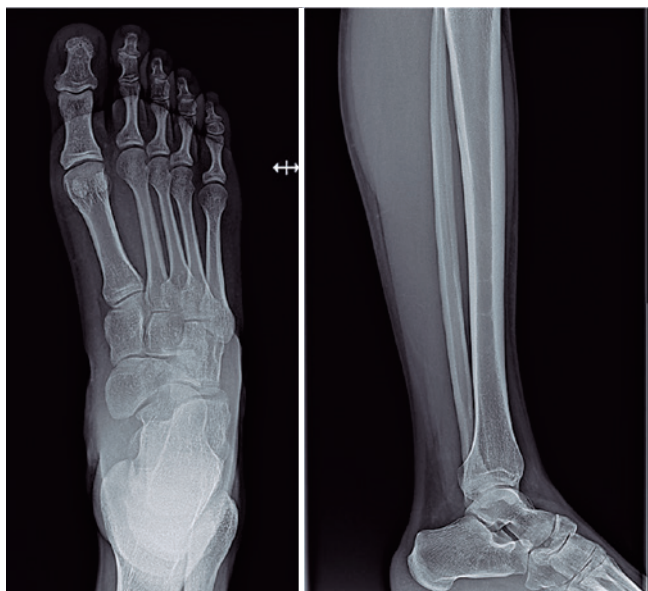

Figure 1. Initial radiographs of the foot and the ankle showing comminuted and displaced fracture of the navicular.

4. The anterior tibial tendon was identified and retracted medially, while the extensor hallucis longus tendon was retracted laterally (Figure 3A);

5. The articular capsules were partially disrupted, and their dorsal aspect was sectioned to widely expose the talonavicular and naviculocuneiform joints (Figure 3B);

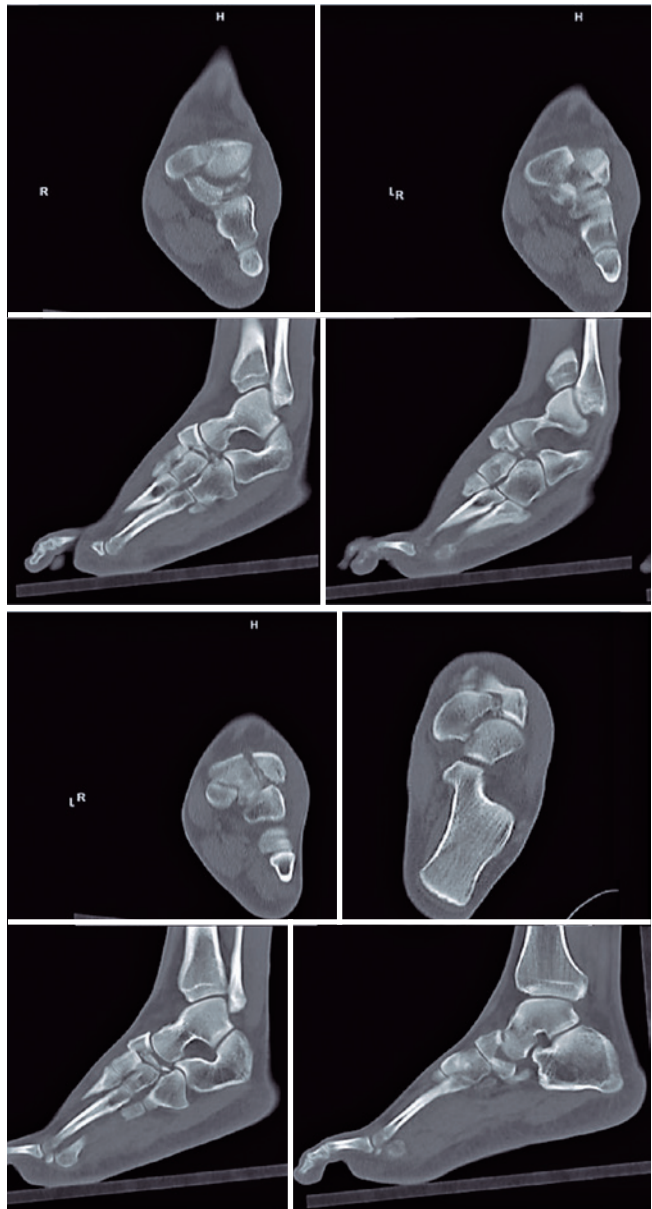


Figure 2. Computed tomography scans on the coronal, axial, and sagittal views showing the dorsomedial fragment displaced dorsally, with impaction of the dorsomedial articular surface of the talonavicular joint, and the plantar-lateral fragment comminuted and displaced, with shortening of the medial column of the midfoot.

6. The fracture of the navicular was noted with the presence of two major fragments, one dorsomedial, and the anatomical reduction of the articular surfaces. Such fragments were fixed with two 3.0 mm HCS™ lag screws (DePuy Synthes, J&J Company, USA) (Figure 3C);

7. Appropriate length of the medial column of the foot was restored and confirmed by radioscopy, and a 2.7-mm low-profile locking plate (Medartis AG, Switzerland) was positioned at the dorsal aspect of the midfoot. Then, 2.7-mm locking screws were inserted proximally into the talus head and distally into the medial cuneiform, sparing the navicular and maintaining the anatomy of the medial longitudinal arch (Figure 3D);

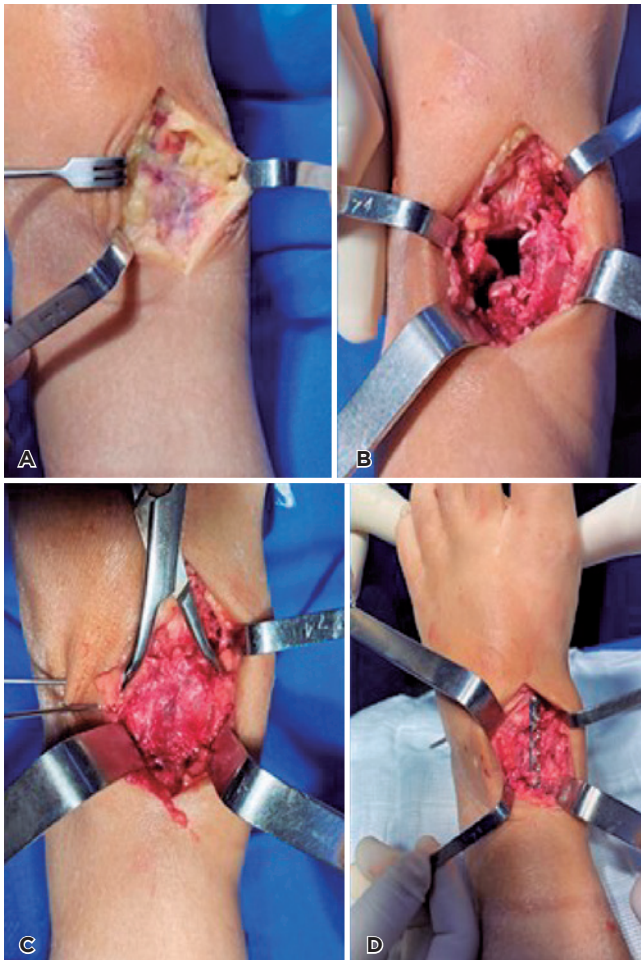


Figure 3. A) Dorsomedial incision from the talus neck to the medial cuneiform, with retraction of the anterior tibial and extensor hallucis longus tendons. B) Intraoperative image of the fracture of the navicular with the presence of two major fragments, one dorsomedial and the other plantar-lateral, and naviculocuneiform joint luxation. C) Reduction of the main articular fragments. D) Positioning of the bridge plate at the dorsal aspect of the midfoot after screw fixation of the main fragments.

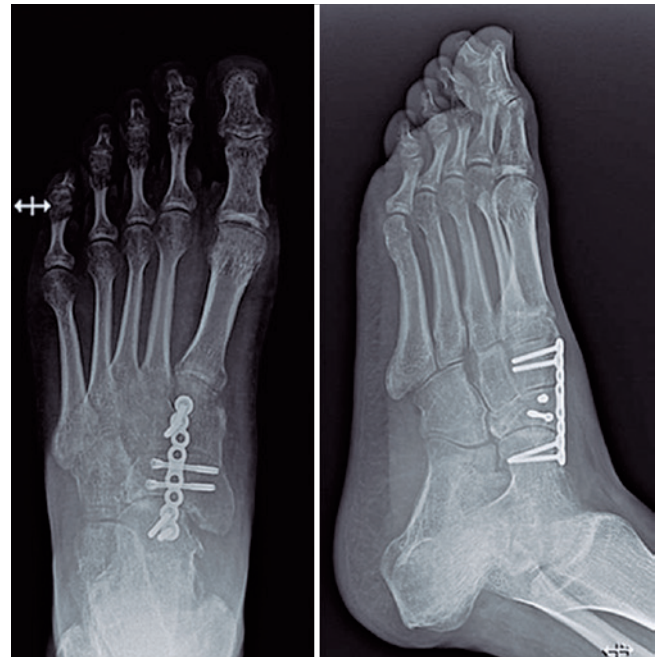

Figure 4. Postoperative radiographs with navicular fracture reduction and restoration of the talonavicular and naviculocuneiform joint congruence and medial column length.

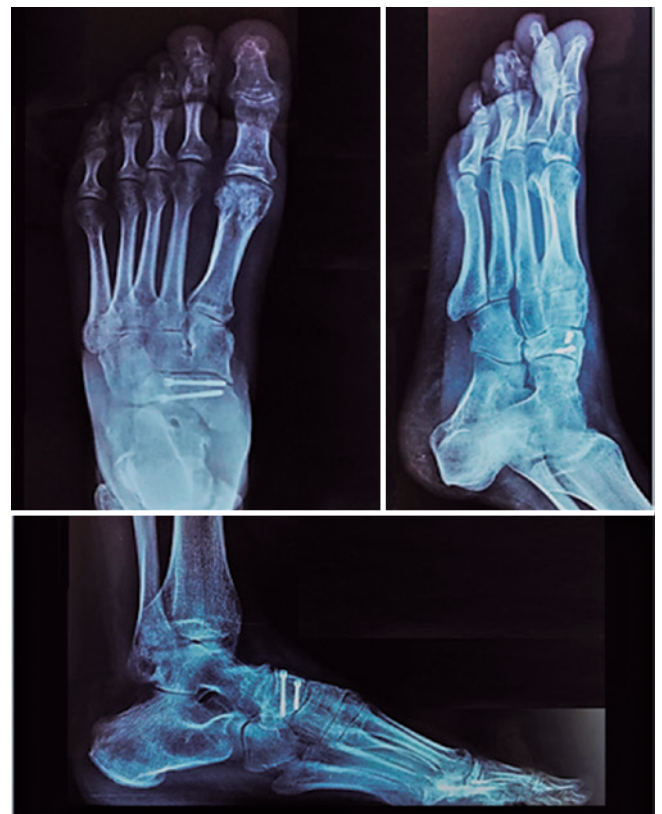

Figure 5. Radiographic views of the foot 10 months following the injury, 6 months after plate removal.

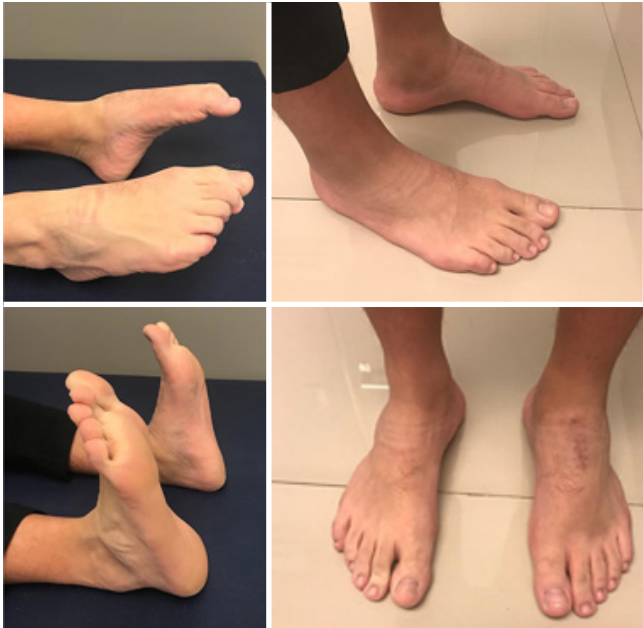

Figure 6. Clinical aspect of the feet and ankle 10 months following the initial trauma and surgery.

8. After the correct positioning of the implants and the reduction of the fracture and joints were confirmed with radioscopy, the wound was irrigated with 0.9% saline and sutured with 2.0 absorbable sutures subcutaneously and 4.0 mononylon sutures on the skin;

9. An occlusive dressing was applied with sterile gauze protecting the surgical incision. The pneumatic tourniquet was released with consequent restoration of normal peripheral perfusion.

10. The limb was immobilized with a removable ankle/foot orthopedic orthosis for 3 weeks, when the suture was removed.

During the first 6 weeks, we recommended avoiding bearing weight on the affected foot, allowing only toe-touch weight-bearing. Stiffness of the talonavicular joint is expected while the bridge plate is present. After week 6, the patient was recommended to progressively bear weight with the orthosis until week 9, when the orthosis was discontinued. At week 16, we confirmed by clinical and radiographic evaluation the presence of fracture healing (Figure 4), preservation of the medial longitudinal arch and joint congruence, and maintenance of the length of the medial column of the foot. At that moment, the patient underwent a second surgical procedure, and the bridge plate was removed. Ten months following the fracture, new radiographs showed a healed navicular fracture with joint congruence and without avascular necrosis. The patient presented with a range of motion similar to the contralateral side, had no complaints of pain, and had resumed sports activities (Figures 5 and 6).

Discussion

Fractures of the tarsal navicular bone are uncommon. Only 5% of foot fractures affect the midfoot, and 35% of those affect the navicular⁽⁵⁾. The most serious fractures may progress with midfoot collapse and/or early osteoarthritis, causing important functional limitations^(1,5,6,8).

In 1989, Sangeorzan et al.⁽⁷⁾ classified fractures of the navicular body into (1) fractures with coronal line without angulation, with dorsal or tuberosity avulsion; (2) body fractures with dorsolateral to plantar-medial line with loss of the medial arch (most common type); and (3) navicular body fractures with central or lateral comminution. The classification system was based on the direction of the fracture line, the direction of displacement of the foot, and the pattern of disruption of the surrounding joints, and was intended to assist in the surgical treatment of fractures^(1,7). Type 3 fractures are challenging injuries because a large amount of energy usually promotes joint fragmentation and displacement. The treatment aims to restore the medial longitudinal arch and the anatomical relationship between the hindfoot and the forefoot, promoting stability of the midfoot⁽¹⁾. In this injury pattern with small-sized comminuted fragments, conventional fixation techniques may not be feasible or sufficiently stable^(1,3,5,9). Kirschner wires may not provide sufficient stability to maintain the length and shape of the medial midfoot arch, and plate and screw systems may cause excessive vascular damage⁽⁹⁻¹¹⁾. Furthermore, late complications and poor outcomes have been associated with comminuted navicular fractures, including avascular necrosis, delayed union, osteoarthritis, joint stiffness, and chronic pain, especially when the medial column is not restored^(3,10,11). Therefore, some authors recommend the association of an external fixator with primary osteosynthesis or primary arthrodesis as a salvage procedure^(1,5,12).

For comminuted fracture patterns, surgical attempts to obtain optimal open anatomical reduction and compression fixation may be counterproductive if the vascular bone supply is not respected and when multiple small fragments are present. Important fundamentals are to carefully plan surgical approaches, use indirect reduction techniques when possible, and consider biologic fixation⁽⁶⁾. For example, in a series⁽¹¹⁾ of 10 types 2 and 3 navicular fractures treated with a navicular locking plate, the authors reported the presence of healed fractures in all patients and overall good functional outcomes of the feet after 20 months of follow-up. However, one patient had a compartment syndrome requiring fasciotomy, and another developed partial necrosis of the navicular⁽¹¹⁾.


Bridge plating has been used more recently in traumatic foot injuries, mainly in severe and comminuted fractures associated with subluxation and bone shortening or impaction. Biomechanical cadaveric studies⁽¹³⁾ and case series studies⁽¹⁴⁾ have suggested that outcomes following surgical Lisfranc joint injuries might be superior when fixed with dorsal bridge plating compared with screw fixation only. A previous study⁽¹⁰⁾ reported the outcomes of 7 patients with comminuted and displaced type 3 fractures of the navicular treated surgically with bridge plating. The authors used a 2.7-mm re-

construction plate with 8 to 10 holes at the medial column of the foot, from the talus to the first metatarsal. The 2 proximal and 2 distal holes were fixed with screws, the distal ones being long enough to reach the lateral column⁽¹⁵⁾. Apostle and Younger⁽¹⁵⁾ described a technique consisting of double bridge plating to the medial and middle cuneiforms. In the current technical report, we performed bridge plating fixation using a 2.7 mm locking plate, inserting two screws into the talus and the medial cuneiform. Therefore, in addition to a single and smaller incision, the Lisfranc joint and the bones of the lateral column were not included in the fixation, avoiding joint stiffness and symptoms in the lateral column.

In our opinion, the bridge plating technique is indicated for severely comminuted navicular fracture-dislocations. In these fractures, the forefoot assumes an abducted position, and comminution of the medial midfoot results in shortening of the medial column, which may lead to a midfoot collapse⁽¹⁾. Direct open reduction and fixation of small bony fragments may not be achieved, in addition to leading to excessive vascular damage. Furthermore, medial column instability may require the addition of an external fixator. In the technique described, the small fragments, especially the plantar ones, which are difficult to achieve, are reduced by ligamentotaxis,

and the medial column is stabilized by the bridge plate, ruling out the need for external fixators and avoiding complications and multiple incisions. A disadvantage of the technique is the need for a new surgery to remove the plate. Previous authors^(10,15) have recommended removal after 4–9 months to allow restoration of function in the transverse tarsal and subtalar joints. Because of the possibility of delaying early osteoarthritis and arthrodesis, we consider the present technique to be a good alternative in selected cases. The case presented to illustrate this technical tip was followed up only for 10 months, which is an important limitation. Therefore, mid- and long-term follow-up studies are warranted to evaluate the maintenance of anatomical alignment, functional scores, and development of post-traumatic osteoarthritis.

In sum, the technique described herein has the following advantages: (a) maintenance of the medial longitudinal column in comminuted navicular fractures; (b) indirect reduction of the small bone fragments; (c) maintenance of the congruence of the talonavicular and naviculocuneiform joints; (d) longer protection in potential cases of vascular damage of the bone tissue or delayed union; and (e) lower morbidity with limited surgical incisions, saving the Lisfranc joint and the lateral column of the foot.

Authors' contributions: Each author contributed individually and significantly to the development of this article: HM *(<https://orcid.org/0000-0001-7527-969X>) Data collection, interpreted the results of the study, wrote the article; LLS *(<https://orcid.org/0000-0003-3006-7831>) Wrote the article; DAM *(<https://orcid.org/0000-0002-3893-0292>) Wrote the article, participated in the review process. All authors read and approved the final manuscript. *ORCID (Open Researcher and Contributor ID) 

References

- Ramadorai MU, Beuchel MW, Sangeorzan BJ. Fractures and dislocations of the tarsal navicular. *J Am Acad Orthop Surg.* 2016;24(6):379-89.
- Burne SG, Mahoney CM, Forster BB, Koehle MS, Taunton JE, Khan KM. Tarsal navicular stress injury: long-term outcome and clinoradiological correlation using both computed tomography and magnetic resonance imaging. *Am J Sports Med.* 2005;33(12):1875-81.
- Schmid T, Krause F, Gebel P, Weber M. Operative treatment of acute fractures of the tarsal navicular body: midterm results with a new classification. *Foot Ankle Int.* 2016;37(5):501-7.
- Pinney SJ, Sangeorzan BJ. Fractures of the tarsal bones. *Orthop Clin North Am.* 2001;32(1):21-33.
- Marshall D, MacFarlane RJ, Molloy A, Mason L. A review of the management and outcomes of tarsal navicular fracture. *Foot Ankle Surg.* 2020;26(5):480-6.
- DiGiovanni CW. Fractures of the navicular. *Foot Ankle Clin.* 2004;9(1):25-63.
- Sangeorzan BJ, Benirschke SK, Mosca V, Mayo KA, Hansen ST Jr. Displaced intra-articular fractures of the tarsal navicular. *J Bone Joint Surg Am.* 1989;71(10):1504-10.
- Coulibaly MO, Jones CB, Sietsema DL, Schildhauer TA. Results and complications of operative and non-operative navicular fracture treatment. *Injury.* 2015;46(8):1669-77.
- Karmali S, Ramos JT, Almeida J, Barros A, Campos P, Costa DS. Tarsal navicular fracture in a parkour practitioner, a rare injury – Case report and literature review. *Rev Bras Ortop.* 2019;54(6):739-45.
- Schildhauer TA, Nork SE, Sangeorzan BJ. Temporary bridge plating of the medial column in severe midfoot injuries. *J Orthop Trauma.* 2003;17(7):513-20.
- Cronier P, Frin JM, Steiger V, Bigorre N, Talha A. Internal fixation of complex fractures of the tarsal navicular with locking plates. A report of 10 cases. *Orthop Traumatol Surg Res.* 2013;99(4 Suppl):S241-9.
- Moreira ET, Andrade CA, Maluf Neto J, Lovisotto LA. Navicular bone comminuted fracture: medial plate fixation. Case report and literature review. *Rev ABTPé.* 2014;8(1):39-44.
- Alberta FG, Aronow MS, Barrero M, Diaz-Doran V, Sullivan RJ, Adams DJ. Ligamentous Lisfranc joint injuries: a biomechanical comparison of dorsal plate and transarticular screw fixation. *Foot Ankle Int.* 2005;26(6):462-73.
- Hu SJ, Chang SM, Li XH, Yu GR. Outcome comparison of Lisfranc injuries treated through dorsal plate fixation versus screw fixation. *Acta Ortop Bras.* 2014;22(6):315-20.
- Apostle KL, Younger AS. Technique tip: open reduction internal fixation of comminuted fractures of the navicular with bridge plating to the medial and middle cuneiforms. *Foot Ankle Int.* 2008;29(7):739-41.