

Original Article

Intra-articular pressure measurement of the first metatarsophalangeal joint of the foot

Jorge Luis Alberto Castellini¹ 

1. Dr. Jorge Castellini Clinic, Buenos Aires, Argentina.

Abstract

Objective: To measure the metatarsophalangeal (MTP) intra-articular pressure of the first ray before surgical intervention for hallux valgus (HV), recurrent HV, and hallux rigidus (HR).

Methods: This is a cross-sectional study including a consecutive sample of patients obtained from 1/1/2009 and 8/30/2015 in a center in Argentina. Measurements were made with a Stryker® pressure gauge, and results were expressed in mmHg. Descriptive and comparative statistics (Mann-Whitney test) were performed.

Results: A total of 166 feet were included, 120 cases with HV, 20 with HR, and 26 with recurrent HV; the sample consisted of men and women aged 15 to 90 years. The greater HV deformity, the higher intra-articular pressure at rest and during maximal dorsiflexion and maximal plantar flexion. Conversely, an inverse situation is observed in HR: the greater the deformity, the lower intra-articular pressure. Median resting intra-articular pressure of the first MTP joint of the foot was 3 mmHg in mild HV, compared to 23 mmHg in early-stage HR ($p=0.001$).

Conclusions: The measurement of intra-articular pressure could be a useful tool to differentiate early stages of joint diseases of the first ray of the foot.

Level of Evidence II; Prognostic Studies; Retrospective Study.

Keywords: Hallux valgus; Hallux rigidus; Osteoarthritis; Recurrence.

Introduction

Medical consultations due to or first metatarsophalangeal joint (MTPJ) pain deformity is very frequent in foot and ankle specialists' offices, requiring an accurate differential disease diagnosis. The conduct will be different whether it is a valgus hallux deformity known as hallux valgus (HV) or a disease presenting with restricted joint movement and deformity mainly at the dorsal level, known as hallux rigidus (HR) or Dorsal bunion⁽¹⁾.

The prevalence varies according to deformity and age. HV is more prevalent in women (2.3:1) and older adults. Nix et al.⁽²⁾, in a systematic review that included 78 studies with 500,000 cases, estimated a prevalence of 7.8% in juveniles, 23% in adults from 18-65 years, and 35.7% in those older than 65 years. Senga et al.⁽³⁾ found a prevalence of 26.7% for HR among 607 feet in Japan.

Several studies about the pathogenesis of HR have been conducted⁽⁴⁻⁶⁾. Lambrinudi⁽⁴⁾ describes a flexion contracture of the metatarsophalangeal of the first ray and consider it a possible etiopathogenic factor of HR, which could explain the difference in the height of the first metatarsal relative to the second metatarsal in weight-bearing profile radiographs.

Several studies were conducted aiming to differentiate HV from HR using radiographic measures^(1,7-9). Bouaicha et al.⁽⁹⁾ in 2010 and Usueli et al.⁽¹⁾ in 2011 propose that metatarsus primus elevatus (MPE) is constant in HR and not in HV; whereas Horton and Meyer did not find conclusive results, because they observed MPE in both diseases^(6,7).

With regard to HR, the biological plausibility of this first metatarsal elevation could be a consequence of reduced excursion of the flexor hallucis longus (FHL) tendon, either due to muscle contracture, plantar plate adhesions, or dorsal

Study performed at the Dr. Jorge Castellini Clinic, Buenos Aires, Argentina.

Correspondence: Jorge Luis Alberto Castellini, Riobamba 972 3°C, CP 1116, Ciudad Autónoma de Buenos Aires, Argentina. **E-mail:** jorgecastellini@gmail.com.
Conflicts of interest: none. **Source of funding:** none. **Date received:** March 12, 2022. **Date accepted:** March 23, 2022. **Online:** April 30, 2022.



osteophytosis⁽¹⁰⁾. This proximal displacement of the FHL could increase tendon strength, causing increased loading on the first MTPJ and first metatarsal, and progressive fibrosis in the musculotendinous junction could result from increased loading or pressure on the MTPJ.

The most currently used surgical techniques consider MPE as the cause of HR and aim to descend the first metatarsal head and shorten the first metatarsal to achieve normal MTPJ range of motion⁽¹¹⁻¹⁴⁾. Voss⁽¹⁵⁾ proposed that joint decompression tenotomies would reduce primary and idiopathic increase in intra-articular pressure on hip joint. In a cadaveric study, Kim et al.⁽¹⁶⁾ compared intra-articular pressure, measured with digital sensors (in kg/cm²), before and after phalangeal osteotomy, and did not find changes in pressure of the first metatarsal head. However, this work has been questioned due to the absence of FHL during measurements of the cadaveric specimens.

Although there are objective standards to define advanced HV and HR, differentiation in early stages has not been cleared yet, these last account for nearly 90% of cases of HR, with mild deformity or without radiographic signs⁽³⁾.

In light of the foregoing, I hypothesize that HR would present with a primary or idiopathic increase in intra-articular pressure, whereas HV would not. The aim of the present study is to measure intra-articular pressure of the MTPJ of the first ray in a group of patients with different stages of HV and HR, before undergoing surgical intervention.

Methods

This study, which was approved by my institution's ethics committee.

A cross-sectional study was conducted with a consecutive sample obtained from 1/1/2009 to 8/30/2015 and consisting of patients with HV, HR and/or recurrent HV who underwent surgical intervention with techniques performed according to baseline disease. Informed consent was provided by each study participant.

Radiographic classification of HV was based on values of metatarsophalangeal and intermetatarsal angles on frontal or anteroposterior radiograph, and HV was classified into mild, moderate, and severe^(17,18).

Radiographic classification of HR considered parameters such as joint impingement, development of osteophytes, subchondral sclerosis at the first metatarsal base, and osteochondral lesions of the first metatarsal head and the base of phalanx. I used the classification proposed by Hatstrup and Johnson⁽¹⁹⁾, which classifies HR into Grades 1, 2, and 3.

Horton index is measured in weight-bearing profile radiograph of the foot. It is the distance in mm from the cortical dorsal surface of the first metatarsal (M1) to the cortical dorsal surface of the second metatarsal (M2), at the neck of the metatarsal, which is nearly 15 mm proximal to the joint surface. This measurement was conducted in all cases, and Horton index was considered high when there was 3 or more mm of difference between M1 and M2⁽⁶⁾.

Cases of recurrent HV were considered those in which the metatarsophalangeal angle is above 20° on weight-bearing anteroposterior radiograph⁽²⁰⁾.

Patients with neurological or arterial vascular diseases, arthritis rheumatoid, hallux varus were excluded, as well as those with missing measurement data.

Technique for measuring intra-articular pressure

Measurement of intra-articular pressure of first MTPJ was made using a Stryker® pressure gauge, which is usually used to diagnose compartment syndrome in crush injuries of peripheral limbs (upper and lower).

Once regional anesthetic blockade was performed on the ankle, an ultrathin needle is placed on the dorsal MTPJ of the first ray, immediately medial to the extensor hallucis longus tendon, in order to prevent injuries to the dorsomedial collateral branch. This needle is connected to a catheter that is then attached to the pressure gauge.

In the first cases, a fluoroscope was used to ensure intra-articular position, but soon later it was not necessary, due to ease of the procedure with the needle.

Three consecutive measures were taken before surgical intervention. The first one was obtained with the patient in the supine position and the joint in a joint position, in order to assess the so-called baseline or resting pressure. For the second measure, a maximal passive dorsiflexion maneuver was performed, and pressure is shown on the display of the gauge held by an assistant (the pressure gauge is not sterile). Finally, a third measure was obtained placing the hallux in maximal passive plantar flexion (Figures 1, 2, 3 and 4).

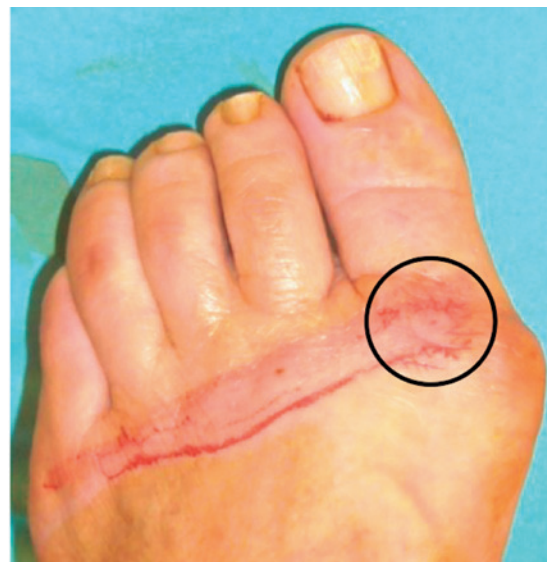

Figure 1. Image obtained before hallux valgus surgery on the left foot and focusing on the insertion site of the needle to assess pressure of the metatarsophalangeal joint of the first ray.

Statistical analysis

For descriptive analysis, continuous variables were expressed as mean and standard deviation (SD) for normally distributed variables and as median and interquartile range (IQR) for abnormally distributed ones. Categorical and ordinal variables were presented as absolute and relative frequencies.

Comparative analysis between mild HV and early-stage HR was performed using the Mann-Whitney test for comparison of medians. Statistical significance was set a p-value of <0.05.



Figure 2. Image showing resting pressure in mmHg before hallux valgus surgery on the left foot.



Figure 3. Image showing pressure during maximal passive dorsiflexion measured in mmHg before hallux valgus surgery on the left foot.



Figure 4. Image showing pressure during maximal passive plantar flexion measured in mmHg before hallux valgus surgery on the left foot.

Results

During the study period, 166 feet were included, 120 cases with HV, 20 with HR, and 26 with recurrent HV; consisting of men and women aged 15 to 90 years (Table 1).

Of the 120 cases with HV, 55 (45.83%) presented with radiographic signs of arthrosis (4 mild, 24 moderate, and 27 severe)⁽²¹⁾.

Pressures values measured in the different groups, dividing the cases of HV into 2 subgroups (with and without signs of arthrosis), recurrent HV, and HR are shown in Table 2.

Pressure values in millimeters of mercury (mmHg) in the different groups divided by disease severity into mild, moderate, and severe HV, Grade 1, 2, and 3 HR, and cases of recurrent HV are presented in Table 3.

Median resting intra-articular pressure in mild HV was significantly lower than that observed in grade 1 HR (3 mmHg vs 23 mmHg respectively; $p=0.001$).

Discussion

Results showed a statistically significant difference in resting intra-articular pressure between HV and early-stage HR. The greater HV deformity, the higher intra-articular pressure at rest and during maximal dorsiflexion and maximal plantar flexion. Conversely, an inverse situation was observed in HR: the greater deformity, the lower intra-articular pressure. The group of patients with recurrent HV presented with values similar to those of moderate and severe HV.

With regard to the etiopathogenic factor for HR described by Lambrinudi⁽⁴⁾, early stage would present with higher pressure, either primary or secondary, and mobility is reduced as deformity increases, which could explain the reduction in intra-articular pressure observed in our study.

Due to the lack of reports in the literature expressing joint pressure in millimeters of mercury, it was not possible to compare our findings with those of other authors. However, the hypothesis of primary and idiopathic hyperpressure of hip joint has been present since 1956⁽¹⁵⁾. In Germany, Voss⁽¹⁵⁾ proposed a treatment consisting of tenotomy of all tendons that cross the hip joint and finally insert into the proximal femur, an operation that he named "floating hip". In 1963 comparative results of these surgeries to reduce hip joint pressure were published, showing 80% of good clinical results, with a 6-month follow-up⁽²²⁾.

With regard to foot surgery, in a congress of the specialty held in early 2000, Fernando Troilo, a surgeon of *Sociedad Argentina de Medicina y Cirugía de Pie y de Pierna* (SAMECIPP) and *Asociación Argentina de Ortopedia y Traumatología* (AAOT), presented a technique to measure intra-articular pressure with a sphygmomanometer similar to that used to measure arterial tension, in patients with recurrent HV, reporting that they presented with an increase in such pressure. Several years later, a French surgeon, during a presentation at a congress of the specialty, stated that the aim of his surgery of first metatarsal shortening osteotomy was reducing pain,

Table 1. Description of demographic characteristics of samples according to diagnostic group

	Hallux valgus (n=120)	Hallux rigidus (n=20)	Recurrent hallux valgus (n=26)
Female sex	115 (95%)	15 (75%)	25 (96.15%)
Age (years)*	54.67±15	53.61±14	58.57±20
High Horton index	80/111 (72.07%)	19/20 (95%)	16/23 (69.57%)
Classification	Mild 15 (12.50%) Moderate 63 (52.50%) Severe 42 (35%)	Grade 1 5 (25%) Grade 2 11 (55%) Grade 3 4 (20%)

*Mean (standard deviation)

Table 2. Pressure values in the different groups, with cases of hallux valgus (HV) divided into 2 subgroups (with and without signs of arthrosis). Values expressed in millimeters of mercury (mmHg)

	HV without arthrosis# (n=65)	HV with arthrosis# (n=55)	Recurrent HV (n=26)	HR (n=20)
At rest (mmHg)*	5 (-4 to 43)	7 (-5 to 73)	8 (-2 to 38)	20 (0 to 70)
Passive dorsiflexion*	37.5 (-2 to 196)	46 (-2 to 162)	38.5 (0 to 185)	40 (-2 to 196)
Passive plantar flexion*	24.5 (-4 to 193)	26 (-6 to 178)	23.5 (-6 to 181)	46 (-1 to 188)

*median (percentile 1% - percentile 99%) #Kellgren-Lawrence classification

Table 3. Pressure values in millimeters of mercury (mmHg) in the different groups: mild, moderate, and severe hallux valgus (HV), Grade 1, 2, and 3 hallux rigidus (HR), and cases of recurrent HV

	At rest*	Passive dorsiflexion*	Passive plantar flexion*
Mild HV (n=15)	3 (-1 to 38)	31 (0 to 163)	28 (-2 to 115)
Moderate HV (n=63)	5 (-4 to 43)	40 (-2 to 196)	21 (-4 to 193)
Severe HV (n=42)	8 (-5 to 73)	41 (0 to 145)	34 (-6 to 178)
Recurrent HV (n=26)	8 (-2 to 38)	38.5 (0 to 185)	23.5 (-6 to 181)
Grade 1 HR (n=5)	23 (0 to 26)	110 (12 to 189)	63 (32 to 130)
Grade 2 HR (n=11)	21 (3 to 70)	83.5 (4 to 199)	39.5 (0 to 188)
Grade 3 HR (n=4)	16.5 (11 to 20)	40 (15 to 53)	23.5 (-1 to 66)

*median (percentile 1% - percentile 99%)

which would derive from increased joint pressure. Although the author did not aim to measure this pressure, he observed that such decompression was able to regenerate damaged joint cartilage in long-term radiographic controls.

In my experience, it was not possible to measure postoperative intra-articular pressure, because patients did not accept a new measurement in the long-term follow-up, except for cases of recurrent or persistent pain. Only in one case, on the surgery on the contralateral foot (after informed consent), I was able to measure intra-articular pressure of the osteotomized (shortened) metatarsal and observed a lower value compared to the first measure (taken prior to the first intervention), and pain had disappeared. Although M1 shortening

seemed exaggerated on the radiograph of this foot patient, she wanted to have the same treatment on the other foot. Other limitation to mention is the number of patients, which prevented the exploration for ages or the stratification of severity subgroups, which could have been interesting, but it was not feasible (reduced sample size would lead to lack of statistical power). Furthermore, since it is a measurement involving an intervention, there is risk of information bias when placing the needle and exerting pressure to perform of dorsal and plantar flexion maneuvers (operator dependent).

It is worth highlighting that, although these findings may be interpreted from a mainly mechanical perspective, biological factors that would interfere with joint degenerative pheno-

mena should also be considered. However, the findings of the present study make it possible to consider measurement of joint pressure as a possible diagnostic tool, particularly in early stages of HR or HV requiring surgical treatment. Objective measures are needed with regard to the surgical technique used (both in soft tissues and in bone tissue) to solve HV and HR, in order to objectively analyze its efficacy and effectiveness. Therefore, new prospective studies are necessary, which include measurement of pressure and long-term results to answer to these questions.

Conclusions

I observed that, the greater HV deformity, the higher intra-articular pressure at rest and during maximal dorsiflexion and maximal plantar flexion. Conversely, an inverse


situation was observed in HR: the greater deformity, the lower intra-articular pressure.

A statistically significant difference was found between HV and early-stage HR in rest intra-articular pressure of the first MTPJ of the foot: 3 mmHg vs 23 mmHg respectively ($p=0.001$).

Thus, measurement of intra-articular pressure could be a useful tool to differentiate early stages of diseases of the first ray of the foot.

Acknowledgment

I especially thank Dr. María Florencia Grande Ratti for conducting statistical analysis and collaborating in the writing of the final report.

Author's contributions: JLAC *(<https://orcid.org/0000-0002-5665-480X>) Conceived and planned the activities that led to the study, interpreted the results of the study, performed the surgeries, data collection, clinical examination, bibliographic review and approved the final version. The author read and approved the final manuscript. *ORCID (Open Researcher and Contributor ID) 

References

- Usuelli F, Palmucci M, Montrasio UA, Malerba F. Radiographic considerations of hallux valgus versus hallux rigidus. *Foot Ankle Int.* 2011;32(8):782-8.
- Nix S, Smith M, Vicenzino B. Prevalence of hallux valgus in the general population: a systematic review and meta-analysis. *J Foot Ankle Res.* 2010;3:21.
- Senga Y, Nishimura A, Ito N, Kitaura Y, Sudo A. Prevalence of and risk factors for hallux rigidus: a cross-sectional study in Japan. *BMC Musculoskelet Disord.* 2021;22(1):786.
- Lambrinudi C. Metatarsus Primus Elevatus. *Proc R Soc Med.* 1938; 31(11):1273.
- McMaster MJ. The pathogenesis of hallux rigidus. *J Bone Joint Surg Br.* 1978;60(1):82-7.
- Horton GA, Park YW, Myerson MS. Role of metatarsus primus elevatus in the pathogenesis of hallux rigidus. *Foot Ankle Int.* 1999;20(12):777-80.
- Meyer JO, Nishon LR, Weiss L, Docks G. Metatarsus primus elevatus and the etiology of hallux rigidus. *J Foot Surg.* 1987;26(3):237-41.
- Bryant A, Tinley P, Singer K. A comparison of radiographic measurements in normal, hallux valgus, and hallux limitus feet. *J Foot Ankle Surg.* 2000;39(1):39-43.
- Bouaicha S, Ehrmann C, Moor BK, Maquieira GJ, Espinosa N. Radiographic analysis of metatarsus primus elevatus and hallux rigidus. *Foot Ankle Int.* 2010;31(9):807-14.
- Kirane YM, Michelson JD, Sharkey NA. Contribution of the flexor hallucis longus to loading of the first metatarsal and first metatarsophalangeal joint. *Foot Ankle Int.* 2008;29(4):367-77.
- Pittman SR, Burns DE. The Wilson bunion procedure modified for improved clinical results. *J Foot Surg.* 1984;23(4):314-20.
- Youngswick FD. Modifications of the Austin bunionectomy for treatment of metatarsus primus elevatus associated with hallux limitus. *J Foot Surg.* 1982;21(2):114-6.
- Davies GF. Plantarflexory base wedge osteotomy in the treatment of functional and structural metatarsus primus elevatus. *Clin Podiatr Med Surg.* 1989;6(1):93-102.
- Feldman KA. The Green-Watermann procedure: geometric analysis and preoperative radiographic template technique. *J Foot Surg.* 1992;31(2):182-5.
- Voss C. [The importance of operative conservation of joint function in bilateral hip processes]. *Minerva Ortop.* 1962;13:534-5.
- Kim PH, Chen X, Hillstrom H, Ellis SJ, Baxter JR, Deland JT. Moberg osteotomy shifts contact pressure plantarily in the first metatarsophalangeal joint in a biomechanical model. *Foot Ankle Int.* 2016;37(1):96-101.
- Smith RW, Reynolds JC, Stewart MJ. Hallux valgus assessment: report of research committee of American Orthopaedic Foot and Ankle Society. *Foot Ankle.* 1984;5(2):92-103.
- Coughlin MJ, Freund E, Roger A. Mann Award . The reliability of angular measurements in hallux valgus deformities. *Foot Ankle Int.* 2001;22(5):369-79.
- Hattrup SJ, Johnson KA. Subjective results of hallux rigidus following treatment with cheilectomy. *Clin Orthop Relat Res.* 1988; (226):182-91.
- Aiyer A, Shub J, Shariff R, Ying L, Myerson M. Radiographic recurrence of deformity after hallux valgus surgery in patients with metatarsus adductus. *Foot Ankle Int.* 2016;37(2):165-71.
- Kellgren JH, Lawrence JS. Radiological assessment of osteo-arthritis. *Ann Rheum Dis.* 1957;16(4):494-502.
- Kollberg G, Lundholm G. The Voss operation in osteoarthritis of the hip. *Acta Orthop Scand.* 1965;36:82-8.