

## Original Article

# Progressive collapsing foot deformity treated by calcaneus osteotomy, flexor digitorum longus transfer, and peroneus brevis-to-longus tenodesis

José Antonio Veiga Sanhudo<sup>1</sup>, Giorgio Marin Canuto<sup>2</sup>

1. Hospital Moinhos de Vento, Porto Alegre, Rio Grande do Sul, Brazil.

2. Hospital de Clínicas de Porto Alegre, Porto Alegre, Rio Grande do Sul, Brazil.

## Abstract

**Objective:** This study presents the results of progressive collapsing foot deformity treatment with calcaneus osteotomy, flexor digitorum longus transfer, and peroneus brevis-to-longus transfer as an adjuvant in the correction of the deformity.

**Methods:** The outcomes of 22 patients with posterior tibial tendon dysfunction who underwent calcaneal osteotomy and flexor digitorum longus transfer combined with peroneus brevis-to-longus transfer (tenodesis) were evaluated retrospectively.

**Results:** According to the Visual Analog Scale, pain scores improved from a mean of 7.1 at baseline to 1.6 after a mean follow-up of 32 months. The mean AOFAS score was 45.3 points preoperatively and 86.3 points at follow-up. Comparison of preoperative and postoperative radiographic parameters was possible in 16 patients (73%), demonstrating significant improvements in Meary's angle and calcaneal pitch.

**Conclusion:** Based on these findings, we conclude that correction of progressive collapsing foot deformity through a combination of calcaneal osteotomy, flexor digitorum longus transfer, and peroneal tenodesis leads to improvement in clinical and radiographic parameters.

**Level of Evidence IV; Therapeutic Studies; Case Series.**

**Keywords:** Posterior tibialis tendon dysfunction; Tendon transfer; Tendon injuries.

## Introduction

Adult-acquired flatfoot deformity, recently renamed progressive collapsing foot deformity, is often associated with dysfunction and consequent insufficiency of the posterior tibial tendon<sup>(1)</sup>. Once the posterior tibial tendon loses its key function of stabilizing the hind- and midfoot, pathological forces begin to act at the site of injury, resulting in collapse of the midtarsal joint and forefoot abduction. The peroneus brevis tendon plays an essential role in the development and worsening of valgus hindfoot deformity and forefoot abduction, considering the weakening of its main antagonist<sup>(2,3)</sup>. This muscle imbalance causes elongation of plantar structures, progressive plantar flexion of the talus, collapse of the medial longitudinal arch, hindfoot valgus, and forefoot supination<sup>(4)</sup>.

The clinical presentation of this disorder includes pain in the medial retromalleolar region of the ankle, valgus hindfoot deformity, and forefoot abduction and supination<sup>(5,6)</sup>. Radiological evaluation of the medial longitudinal arch is usually performed by assessing the alignment of the talus and first metatarsal as measured by Meary's angle and the calcaneal pitch angle. Measurement of talar head coverage by the navicular bone assesses the degree of forefoot abduction, although this measurement's accuracy is not high<sup>(7,8)</sup>.

Conservative management can be attempted initially with orthotics, anti-inflammatory drugs, and exercise<sup>(9-11)</sup>, but is usually unsuccessful due to the poor reparative capacity of the posterior tibial tendon at the site of rupture and perpetuation of the deformity due to biomechanical changes secondary to hindfoot valgus<sup>(12)</sup>. The goals of surgical treatment

Study performed at the Hospital Moinhos de Vento, Porto Alegre, RS, Brazil.

**Correspondence:** José Antônio Veiga Sanhudo. Av. Soledade 569/701, Torre Beta, 90.470-340, Porto Alegre, RS, Brazil. **E-mail:** [josesanhudo@yahoo.com.br](mailto:josesanhudo@yahoo.com.br).  
**Conflicts of Interest:** none. **Source of funding:** none. **Date received:** April 9, 2022. **Date accepted:** April 11, 2022. **Online:** April 30, 2022.

**How to cite this article:** Sanhudo JAV, Canuto GM. Progressive collapsing foot deformity treated by calcaneus osteotomy, flexor digitorum longus transfer, and peroneus brevis-to-longus tenodesis. *J Foot Ankle.* 2022;16(1):46-51.



involve correction of the deformity through osteotomy or arthrodesis, depending on the severity and flexibility of the deformity, and muscle rebalancing through tendon transfers<sup>(13,14)</sup>.

Flexor digitorum longus (FDL) transfer to the navicular bone to replace the diseased posterior tibial tendon (PTT) is part of the surgical armamentarium, as primarily described by Goldner et al.<sup>(15)</sup>. However, the fact that the FDL is physiologically weaker than the PTT<sup>(16)</sup> is a cause of concern. Interestingly, some studies have demonstrated an absence of fallen arch in patients with neurological damage who underwent dorsal transposition of the PTT to strengthen ankle dorsiflexion<sup>(17,18)</sup>. The absence of this expected deformity was credited to the fact that these patients have no peroneus brevis muscle function due to their neurological injury, demonstrating that hindfoot valgus deformity and arch fallen is due to muscle imbalance rather than PTT insufficiency<sup>(19-21)</sup>. Based on the principle of muscle balance, the authors hypothesized that peroneus brevis-to-longus transfer would be beneficial in patients with PTT dysfunction, rebalancing forces in the hindfoot, reducing valgus and abduction stress, increasing plantarflexion of the first ray, improving the medial longitudinal arch, and correcting forefoot supination<sup>(22,23)</sup>. Initially used by the authors to correct flexible forefoot supination, peroneus brevis-to-longus transfer (tenodesis) is now routinely used in patients with PTT dysfunction and flexible deformity to rebalance tendon forces and improve correction of the deformity<sup>(23)</sup>.

In this context, the present study evaluated the clinical outcomes of patients who underwent correction of flexible progressive collapsing foot deformity through calcaneal osteotomy, FDL transfer to the navicular bone, and peroneus brevis-to-longus tenodesis. Subjective clinical analysis was performed by comparing pre- vs postoperative AOFAS scores and Visual Analog Scale pain scores. Radiographic analysis of deformity correction was performed by comparing pre- vs postoperative measures of Meary's angle and calcaneal pitch (Figure 1A-B). Our hypothesis was that adding peroneus brevis-to-longus transfer to conventional surgical flatfoot correction would contribute to muscle rebalancing at the level of the hindfoot and ankle, with subsequent improvement in clinical and radiographic parameters.

## Methods

The study was approved by the hospital's institutional research ethics committee. We included patients with progressive collapsing foot deformity and PTT dysfunction who underwent FDL transfer to the navicular bone, calcaneal osteotomy, and peroneus brevis-to-longus tenodesis between May 2016 and March 2020. Twenty-two patients were included in the study and were assessed using a functional pain Visual Analog Scale and the American Orthopedic Foot and Ankle Society (AOFAS) scale before surgery and at the last clinical assessment. Radiographic correction, assessed by comparing pre- and postoperative Meary's angle and calcaneal pitch angles (Figure 1A-B), was possible in 16 (73%) of

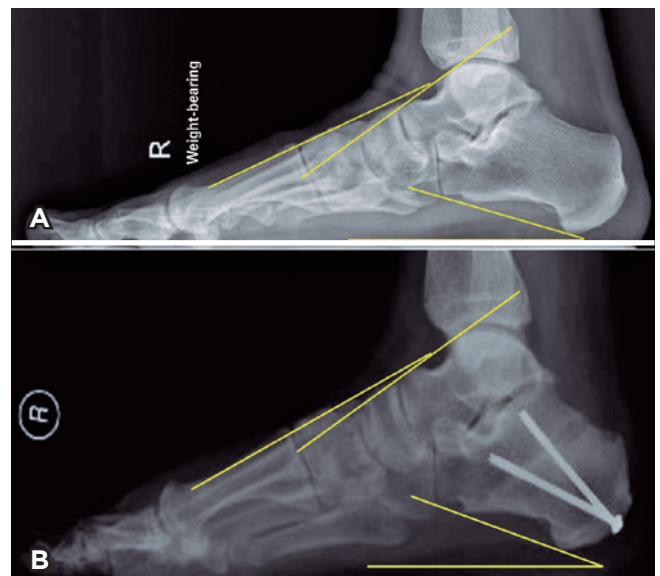
the 22 patients. The mean patient age at the time of surgery was 62.7 years. The mean duration of follow-up was 32 months (minimum 12 months).

Fifteen of the 22 patients underwent additional procedures during the surgical stage. Directly related to the valgus deformity, a pants-over-vest suture of the spring ligament lesion was performed in 5 patients, while proximal release of the medial gastrocnemius was performed in 6 patients who had positive Silfverskiöld test results in preoperative evaluation. In patients with more significant shortening of the posterior chain (3 cases), percutaneous Achilles tendon lengthening was performed. In 1 other case, a Strayer procedure was performed. Other procedures performed concurrently but not directly related to the pes planovalgus deformity included hallux valgus correction (5 cases), correction of claw deformity of the lesser toes (1 case), intermetatarsal neuroma removal (2 cases), and tarsometatarsal arthrodesis of the central rays (1 case).

## Operative technique

After spinal anesthesia, epidural anesthesia, or popliteal blockade with sedation, an Esmarch bandage and tourniquet was placed on the thigh or above the ankle, depending on the anesthetic technique. All patients received antibiotic prophylaxis with cephalosporin for 24 hours, with the first dose given 1 hour before the procedure.

With the patient in the supine position, a medial incision was made above the longitudinal arch that extended approximately 5 cm proximally to the level of insertion of the PTT in the navicular bone. The flexor retinaculum was opened longitudinally, exposing the PTT, which was inspected for degenerati-



**Figure 1.** A-B. Pre- and postoperative x-ray with measurement of Meary's angle and calcaneal pitch.

ve changes and displaced plantarly to allow inspection of the spring ligament. Regardless of the degree of involvement, the PTT was not sutured; repairable spring ligament tears were prepared for direct suturing at the end of the procedure. The FDL was approached deep below the navicular bone, taking care to preserve local neurovascular structures, and was sectioned as distally as possible. The posterior region of the PTT sheath in the medial retromalleolar region was opened, exposing the FDL. A tag suture was made at the end of the FDL with 2-0 Vicryl and a transverse tunnel was drilled with a 4.5 mm bit in a dorsal to plantar direction in the medial portion of the navicular bone for subsequent fixation of the FDL.

Before FDL transfer, the calcaneus was accessed through a mini-L-shaped lateral approach to the hindfoot, leaving the skin, subcutaneous tissue, and sural nerve in a dorsal flap. An osteotomy was performed and the tuberosity was displaced 10 mm medially and fixated with 3 cannulated screws (diameter 4.5 mm, length 45–60 mm). After correct positioning of the screws was confirmed through control radiographs, the calcaneus incision was closed with 2-0 Vicryl, 3-0 Vicryl, and 4-0 Vicryl Rapid.

Through a 2 cm-long lateral retromalleolar longitudinal incision at the ankle joint level, the peroneal retinaculum was opened, exposing the peroneal tendons. A tag suture was made on the peroneus brevis (Figure 2A), which was then tenotomized immediately distal to this suture, advanced distally 10 mm, and sutured onto the peroneus longus tendon immediately behind it (Figure 2B). The retinaculum and subcutaneous tissue were closed with 3-0 Vicryl, while the skin was closed with 4-0 Vicryl Rapid. Finally, the spring ligament was sutured when possible, the FDL was passed through the plantar-to-dorsal tunnel in the navicular bone and was sutured to itself and onto the distal insertional portion of the PTT. This third incision was closed in layers (retinaculum, subcutaneous tissue, and skin), with 2-0 Vicryl, 3-0 Vicryl, and 4-0 Vicryl Rapid, respectively. The leg was then immobilized with a plaster splint in a slight equinovarus position.

### Postoperative protocol

All patients were discharged the day after surgery, with no weight-bearing on the affected limb until the first postoperative visit at 10–14 days, when the splint was replaced with a synthetic cast with the foot in the plantigrade position, with weight-bearing allowed as tolerated by the patient. Six weeks after surgery, the cast was removed, and the patient was referred for rehabilitation.

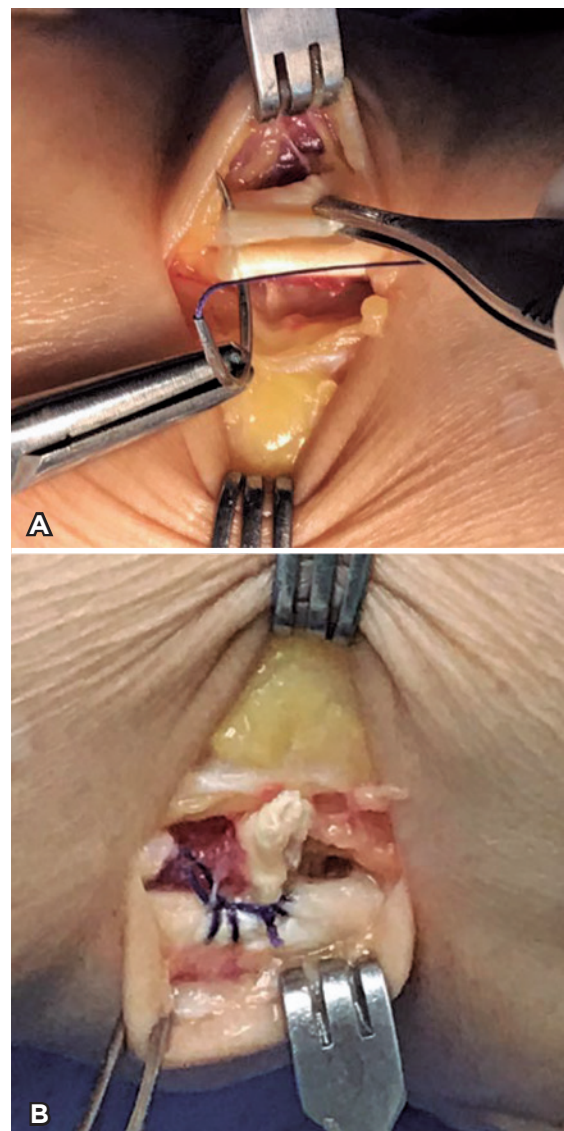
### Statistical analysis

The data are presented as frequency and percentage, mean  $\pm$  standard deviation, median (interquartile range) or mean (95% confidence interval). The normality of the distribution was assessed with the Shapiro-Wilk test. Continuous variables were compared with the Wilcoxon test. In all cases,  $P < 0.05$  was considered statistically significant. All statistical analyses were performed in SPSS version 22 (IBM, Chicago, IL, USA).

## Results

The mean Visual Analog Scale pain score decreased from 7.1 at baseline to 1.6 at follow-up, while the mean AOFAS score was 45.3 preoperatively and 86.3 in follow-up.

Pre- and postoperative radiographic comparison was not possible in 6 of 22 patients due to lack of preoperative (3 patients), postoperative (2 patients), or any radiographs (1 patient). In the remaining 16 patients, for whom adequate image documentation was available, Meary's angle and calcaneal pitch improved from preoperative means of  $10.3^\circ$  and



**Figure 2.** Transoperative image of peroneus brevis-to-longus transfer. A) tag suture of the peroneus brevis. B) peroneus brevis-to-longus tenodesis after distal traction of 10 mm.

11.7° to postoperative means of 6.9° and 17.2°, respectively, at follow-up, an improvement of 3.4° and 5.5°, respectively. Of the 22 patients, 15 were fully satisfied with the outcome, 6 were satisfied with some reservations, and 1 was dissatisfied. The dissatisfied patient had the shortest follow-up (12 months) and had not undergone any rehabilitation due to the COVID-19 pandemic, which may have contributed to the unsatisfactory clinical outcome, especially because the radiographic correction was considered adequate. In this patient, Meary's angle and the calcaneal pitch were 24° and 5° preoperatively and 19° and 9° at follow-up, respectively.

No patient complained about the peroneus brevis area, such as pain at the incision site, sural nerve injury, or reports of ankle sprain during the follow-up period. There were no cases of infection, deep vein thrombosis, or need for reintervention of any kind.

## Discussion

The most common surgical treatment to correct progressive collapsing foot deformity involves calcaneus osteotomy and FDL transfer to the navicular bone<sup>(24)</sup>. Myerson et al.<sup>(20)</sup> reported pain relief in 97% of 129 patients who underwent correction of grade II PTT dysfunction through this technique; radiologically, a mean improvement of 12° in Meary's angle was observed. Marks et al.<sup>(25)</sup> observed a mean improvement of 1° in Meary's angle and 5° in calcaneal pitch in 14 patients who underwent calcaneal osteotomy and FDL tendon transfer after a mean follow-up of 23 months. Niki et al.<sup>(26)</sup> also observed improvement in Meary's angle, which had a mean of 23.7° preoperatively and 14° at the first weight-bearing radiograph (3 months after surgery). The mean calcaneal pitch was 13.3° preoperatively and 16.9° at the first weight-bearing radiograph, a difference the authors considered non-significant<sup>(26)</sup>. In a study of 48 patients, Chadwick et al.<sup>(27)</sup> observed mean AOFAS score improvement from 48.4 preoperatively to 90.3 after a minimum follow-up of 11 years. The Visual Analog Scale pain scores improved from a mean of 7.3 preoperatively to 1.3 at follow-up; 87% of patients were pain-free at final assessment.

Peroneus brevis-to-longus transfer was initially recommended to correct flexible forefoot varus, seeking to eliminate the bone procedure on the first ray, more specifically, first metatarsal osteotomies or medial column arthrodesis<sup>(4,12)</sup>. First-ray procedures are associated with a risk of nonunion or malunion (up to 12%) or complications involving the presence of the hardware itself (approximately 10%)<sup>(28,29)</sup>.

Peroneus brevis transfer to treat flatfoot has already been described, but only as reinforcement in cases where the FDL or the flexor hallucis longus tendon were considered insufficient, too thin, or required revision surgery<sup>(30)</sup>. Peroneus longus-to-brevis transfer to elevate the first metatarsal has been described in cavovarus foot treatment<sup>(30,31)</sup>. Analogous to this procedure, peroneus brevis-to-longus transfer aims to relieve hindfoot valgus tension and forefoot abduction and verticalize the first ray, thus enhancing the medial longitudinal

arch. The technique has been described in combination with lateral column lengthening in the treatment of child flatfoot and in adult diabetic patients undergoing transmetatarsal amputation to correct midfoot supination<sup>(32,33)</sup>. Hansen described peroneus brevis-to-longus tenodesis to treat flatfoot, but did not describe the results<sup>(34)</sup>. Geaney et al.<sup>(35)</sup> described this technique as an adjuvant to flatfoot treatment as well, also without reporting clinical or radiographic outcomes. Because one of the main actions of the peroneus longus is plantarflexion of the first ray, reinforcement of this structure by peroneus brevis tenodesis aims to enhance its function, increasing first ray plantarflexion, increasing the medial longitudinal arch, and correcting forefoot varus<sup>(36)</sup>.


Sanhudo<sup>(23)</sup> described a peroneal tenodesis technique to correct the forefoot varus component of flatfoot deformities. The technique eliminates the risk of nonunion, malunion, or irritation due to the presence of hardware, all of which are associated with medial column osteotomy and first ray arthrodesis<sup>(37)</sup>. Mizel et al.<sup>(4)</sup> reported that patients with peroneal nerve palsy who undergo PTT transfer to the dorsum of the foot did not develop the typical deformities associated with loss of PTT function because they also lacked functioning peroneal tendons. They suggested that procedures which weaken the hindfoot valgus and midfoot abduction forces theoretically limit flatfoot progression and might relieve demand on the repaired or replaced PTT<sup>(4)</sup>. As hypothetical advantages, peroneus brevis release decreases midfoot abduction and valgus tension on the hindfoot, protecting the FDL transfer, while the peroneus brevis-to-longus tenodesis decreases abduction forces on the forefoot and strengthens the plantarflexion force of the first ray, thus helping correct forefoot varus and hindfoot valgus<sup>(23)</sup>.

In all patients in the present series, the peroneal tendons were approached through an additional incision, with calcaneus osteotomy performed through a mini-L-shaped incision<sup>(38)</sup>. The peroneal tendons can be accessed with this same approach when transverse incision is used, although the sural nerve would be at higher risk of lesion.

This is the first study to evaluate the clinical and radiographic outcomes of patients who underwent correction of PTT dysfunction that included peroneal tenodesis. Study limitations include the small number of patients, the possibility of intraobserver error in radiographic parameter measurement, the short duration of follow-up, and the absence of a control group. Longer follow-up in a larger sample is needed for a more accurate assessment of the intervention's long-term utility for these patients.

## Conclusion

Combining calcaneal osteotomy, FDL transfer, and peroneus brevis-to-longus tenodesis promoted significant clinical and radiographic improvement in the parameters of interest, with no need for reintervention due to loss of correction or persistent symptoms.

**Authors' contributions:** Each author contributed individually and significantly to the development of this article: JAVS \*(<https://orcid.org/000-0002-4259-0358>) Conceived and planned the activities that led to the study, clinical examination, survey of the medical records and approved the final version; GMC \*(<https://orcid.org/0000-0002-2712-9491>) Participated in the review process, bibliographic review and formatting of the article. All authors read and approved the final manuscript. \*ORCID (Open Researcher and Contributor ID) 

## References

1. Myerson MS, Thordarson DB, Johnson JE, Hintermann B, Sangeorzan BJ, Deland JT, et al. Classification and nomenclature: progressive collapsing foot deformity. *Foot Ankle Int.* 2020; 41(10):1271-6.
2. Smyth NA, Aiyer AA, Kaplan JR, Carmody CA, Kadakia AR. Adult-acquired flatfoot deformity. *Eur J Orthop Surg Traumatol.* 2017;27(4):433-9.
3. Gomes MDR, Pinto AP, Fabian AA, Gomes TJM, Navarro A, Oliva XM. Insertional anatomy of peroneal brevis and longus tendon - A cadaveric study. *Foot Ankle Surg.* 2019;25(5):636-9.
4. Mizel MS, Temple HT, Scranton PE Jr, Gellman RE, Hecht PJ, Horton GA, et al. Role of the peroneal tendons in the production of the deformed foot with posterior tibial tendon deficiency. *Foot Ankle Int.* 1999;20(5):285-9.
5. Abousayed MM, Tartaglione JP, Rosenbaum AJ, Dipreta JA. Classifications in brief: Johnson and Strom classification of adult-acquired flatfoot deformity. *Clin Orthop Relat Res.* 2016;474(2): 588-93.
6. de Cesar Netto C, Roberts L, Kunas G, Marinescu A, Soukup D, Ellis S. Hindfoot alignment in stage II adult acquired flatfoot deformity: can clinical evaluation predict radiographic measurements? *Foot Ankle Orthop.* 2018;3:2473011418S00205.
7. Shibuya N, Kitterman RT, LaFontaine J, Jupiter DC. Demographic, physical, and radiographic factors associated with functional flatfoot deformity. *J Foot Ankle Surg.* 2014;53(2):168-72.
8. Sensiba PR, Coffey MJ, Williams NE, Mariscalco M, Laughlin RT. Inter- and intraobserver reliability in the radiographic evaluation of adult flatfoot deformity. *Foot Ankle Int.* 2010;31(2):141-5.
9. Aronow MS. Tendon transfer options in managing the adult flexible flatfoot. *Foot Ankle Clin.* 2012;17(2):205-26.
10. Piraino JA, Theodoulou MH, Ortiz J, Peterson K, Lundquist A, Hollawell S, et al. American College of Foot and Ankle Surgeons Clinical Consensus Statement: appropriate clinical management of adult-acquired flatfoot deformity. *J Foot Ankle Surg.* 2020; 59(2):347-55.
11. Deland JT. Adult-acquired flatfoot deformity. *J Am Acad Orthop Surg.* 2008;16(7):399-406.
12. Alvarez RG, Marini A, Schmitt C, Saltzman CL. Stage I and II posterior tibial tendon dysfunction treated by a structured nonoperative management protocol: an orthosis and exercise program. *Foot Ankle Int.* 2006;27(1):2-8.
13. Zanolli DH, Glisson RR, Nunley JA 2nd, Easley ME. Biomechanical assessment of flexible flatfoot correction: comparison of techniques in a cadaver model. *J Bone Joint Surg Am.* 2014;96(6):e45.
14. Backus JD, McCormick JJ. Tendon transfers in the treatment of the adult flatfoot. *Foot Ankle Clin.* 2014;19(1):29-48.
15. Goldner JL, Keats PK, Bassett FH 3rd, Clippinger FW. Progressive talipes equinovagum due to trauma or degeneration of the posterior tibial tendon and medial plantar ligaments. *Orthop Clin North Am.* 1974;5(1):39-51.
16. Bluman EM, Dowd T. The basics and science of tendon transfers. *Foot Ankle Clin.* 2011;16(3):385-99.
17. Sturbois-Nachef N, Allart E, Grauwin MY, Rousseaux M, Thevenon A, Fontaine C. Tibialis posterior transfer for foot drop due to central causes: Long-term hindfoot alignment. *Orthop Traumatol Surg Res.* 2019;105(1):153-8.
18. Gasq D, Molinier F, Reina N, Dupui P, Chiron P, Marque P. Posterior tibial tendon transfer in the spastic brain-damaged adult does not lead to valgus flatfoot. *Foot Ankle Surg.* 2013;19(3):182-7.
19. Helliwell TR, Tynan M, Hayward M, Klenerman L, Whitehouse G, Edwards RH. The pathology of the lower leg muscles in pure forefoot pes cavus. *Acta Neuropathol.* 1995;89(6):552-9.
20. Myerson MS, Badekas A, Schon LC. Treatment of stage II posterior tibial tendon deficiency with flexor digitorum longus tendon transfer and calcaneal osteotomy. *Foot Ankle Int.* 2004;25(7):445-50.
21. Den Hartog BD. Flexor digitorum longus transfer with medial displacement calcaneal osteotomy. Biomechanical rationale. *Foot Ankle Clin.* 2001;6(1):67-76.
22. Akimau P, Flowers M. Medium term outcomes of planovalgus foot correction in children using a lateral column lengthening approach with additional procedures 'a la carte'. *Foot Ankle Surg.* 2014;20(1):26-9.
23. Sanhudo JAV. Dynamic correction for forefoot varus in stage II-A adult flatfoot: Technique tip. *Foot Ankle Surg.* 2019;25(5):698-700.
24. Hiller L, Pinney SJ. Surgical treatment of acquired flatfoot deformity: what is the state of practice among academic foot and ankle surgeons in 2002? *Foot Ankle Int.* 2003;24(9):701-5.
25. Marks RM, Long JT, Ness ME, Khazzam M, Harris GF. Surgical reconstruction of posterior tibial tendon dysfunction: prospective comparison of flexor digitorum longus substitution combined with lateral column lengthening or medial displacement calcaneal osteotomy. *Gait Posture.* 2009;29(1):17-22.
26. Niki H, Hirano T, Okada H, Beppu M. Outcome of medial displacement calcaneal osteotomy for correction of adult-acquired flatfoot. *Foot Ankle Int.* 2012;33(11):940-6.
27. Chadwick C, Whitehouse SL, Saxby TS. Long-term follow-up of flexor digitorum longus transfer and calcaneal osteotomy for stage II posterior tibial tendon dysfunction. *Bone Joint J.* 2015;97-B(3):346-52.
28. Boffeli TJ, Schnell KR. Cotton osteotomy in flatfoot reconstruction: a review of consecutive cases. *J Foot Ankle Surg.* 2017;56(5):990-5.
29. Choi JY, Cha SM, Yeom JW, Suh JS. Effect of the additional first ray osteotomy on hindfoot alignment after calcaneal osteotomy for the correction of mild-to-moderate adult type pes plano-valgus. *J Orthop Surg (Hong Kong).* 2017;25(1):2309499016684747.
30. Song SJ, Deland JT. Outcome following addition of peroneus brevis tendon transfer to treatment of acquired posterior tibial tendon insufficiency. *Foot Ankle Int.* 2001;22(4):301-4.

31. Boffeli TJ, Abben KW. Complete fifth ray amputation with peroneal tendon transfer--a staged surgical protocol. *J Foot Ankle Surg.* 2012;51(5):696-701.
32. Hamel J. [Corrective procedures and indications for cavovarus foot deformities in children and adolescents]. *Oper Orthop Traumatol.* 2017;29(6):473-82.
33. Schweinberger MH, Roukis TS. Balancing of the transmetatarsal amputation with peroneus brevis to peroneus longus tendon transfer. *J Foot Ankle Surg.* 2007;46(6):510-4.
34. Cohen JC, de Freitas Cabral E. Peroneus longus transfer for drop foot in Hansen disease. *Foot Ankle Clin.* 2012;17(3):425-36.
35. Geaney LE, Myerson MS. Management of posterior tibial tendon rupture with allograft reconstruction, osteotomy, and peroneus brevis-to-longus transfer. *Tech Foot Ankle Surg.* 2015;14:112-9.
36. Otis JC, Deland JT, Lee S, Gordon J. Peroneus brevis is a more effective evolver than peroneus longus. *Foot Ankle Int.* 2004;25(4):242-6.
37. Ajis A, Geary N. Surgical technique, fusion rates, and planovalgus foot deformity correction with naviculocuneiform fusion. *Foot Ankle Int.* 2014;35(3):232-7.
38. Sanhudo JA. Mini L-shaped incision for calcaneal osteotomy: clinical tip. *Foot Ankle Int.* 2006;27(5):380-1.