

## Original Article

# Weight-bearing CT Hounsfield unit algorithm assessment of calcaneal osteotomy healing. A prospective study comparing metallic and bio-integrative screws

Nacime Salomão Barbachan Mansur<sup>1,2</sup>, Tutku Tazegul<sup>1</sup>, Kepler Alencar Mendes de Carvalho<sup>1</sup>, Ki Chu Kim<sup>1,3</sup>, Kevin Dibbern<sup>1</sup>, Matthieu Lalevee<sup>1,4</sup>, César de César Netto<sup>1</sup>

1. Department of Orthopaedics and Rehabilitation, University of Iowa, Carver College of Medicine, Iowa City, IA, USA.

2. Federal University of Sao Paulo, Department of Orthopedics and Traumatology, Sao Paulo, SP, Brazil.

3. Seoul Medical Center, Seoul, South Korea.

4. Department of Orthopedic Surgery, Rouen University Hospital, Rouen, France.

## Abstract

**Objective:** To investigate the capability of biointegrative screws to achieve similar radiographical healing outcomes to metallic screws, measured using Hounsfield Unit (HU) algorithms, in medial displacement calcaneus osteotomies (MDCO). Our main hypothesis is that both implant methods would demonstrate comparable results.

**Methods:** In this prospective comparative study, patients undergoing MDCO were allocated to either a biointegrative or a metallic group. Surgeon, primary diagnosis, technique, and displacement were the same for both groups. Patients were assessed using weight-bearing computed tomography preoperatively and at weeks 2, 6, and 12 postoperatively. A 40x40x40 mm cube was centered on the osteotomy site, defining a volume of interest (VOI). Image intensity (Hounsfield Units) profiles along lines perpendicular to the osteotomy line and crossing it were recorded. Graphical plots of the HU distributions were generated for each line and then used to calculate the HU contrast.

**Results:** Three patients were allocated to the metallic group (age: 50.66; BMI: 27.78) and three to the biointegrative group (age: 47.33; BMI: 39.35). At two weeks, mean HU intensity was lower in the metallic group on the center (403.25 vs. 416.28;  $p=0.312$ ) and superior lines (438.97 vs. 497.92), but not on the inferior line (513.24 vs. 386.57;  $p<0.001$ ). At six weeks, the mean HU intensity was higher in the biointegrative group on the center line ( $p<0.001$ ) and the superior line ( $p=0.018$ ). At 12 weeks, the metallic group presented lower HU values on the center ( $p<0.001$ ) and inferior ( $p<0.001$ ) lines, but higher values on the superior line ( $p=0.010$ ). Contrast was higher in the metallic group patients in the second ( $p=0.034$ ) and 12th weeks ( $p=0.049$ ).

**Conclusion:** Bone healing radiographical status results were similar for metallic and bio-integrative screws. Maximum HU values were equivalent, indicating comparable results at the osteotomy sites. However, the biointegrative group had lower contrast, portraying lower variability of bone density over the area.

**Level of Evidence II; Prospective Comparative Study.**

**Keywords:** Absorbable implants; Biocompatible materials; Calcaneus; Fracture healing; Orthopedic fixation devices; Osteotomy.

Study performed at the Department of Orthopaedics and Rehabilitation, University of Iowa, Iowa City, IA, USA.

**Correspondence:** Nacime Salomao Barbachan Mansur. Department of Orthopedics and Rehabilitation, University of Iowa. 200 Hawkins Dr, John Pappajohn Pavillion (JPP). Room 01066, Lower Level. Iowa City, IA, 52242. United States. **E-mail:** [nacime-mansur@uiowa.edu](mailto:nacime-mansur@uiowa.edu). **Conflicts of Interest:** **Nacime Salomao Barbachan Mansur:** Brazilian Foot and Ankle Society: Board or committee member. American Orthopaedic Foot and Ankle Society: Board or committee member. **César de César Netto:** American Orthopaedic Foot and Ankle Society: Board or committee member. Editor in Chief Foot and Ankle Clinics. CurveBeam: Paid consultant; Stock or stock Options. Foot and Ankle International: Editorial or governing board. Nextremity: Paid consultant. Ossio: Paid consultant. Paragon 28: IP royalties; Paid consultant. Weightbearing CT International Study Group: Board or committee member. Zimmer: Paid consultant. **Source of funding:** none. **Date received:** April 19, 2022. **Date accepted:** April 20, 2022. **Online:** April 30, 2022.

**How to cite this article:** Mansur NSB, Tazegul T, Carvalho KAM, Kim KC, Dibbern K, Lalevee M, et al. Weight-bearing CT Hounsfield unit algorithm assessment of calcaneal osteotomy healing. A prospective study comparing metallic and bio-integrative screws. *J Foot Ankle.* 2022;16(1):52-8.

## Introduction

Use of biointegrative implants in orthopedic surgery is increasing exponentially<sup>(1-3)</sup> due to prospective benefits such as adequate bone healing, lower rates of removal, and diminished implant-related artifacts in imaging studies when compared to metallic implants<sup>(4,5)</sup>. While many biomechanical and histological studies have been able to demonstrate their structural and biological properties, few reports are available to support their potential clinical advantages<sup>(1,6,7)</sup>. Evolution of material priorities over the last years have aimed at total product integration and reduction of possible complications such as cysts, foreign body reaction, and breakage<sup>(2,4)</sup>. Still, there is no direct comparison between the gold-standard metallic and the new biointegrative implants.

Data from weight-bearing computed tomography (WBCT) imaging can provide an objective assessment of bone density and joint space width<sup>(8,9)</sup>. A numerical calculation of the bone density within specific volumetric regions can be performed using imaging data measured in Hounsfield Units (HU)<sup>(6)</sup>. This method might be helpful for identifying stages of bone healing in specific regions more objectively than the current assessment, which relies on subjective evaluation of bone interfaces on non weight-bearing computed tomography (CT)<sup>(10,11)</sup>. For the current assessment, readers must come up with a consolidation percentage using a trabecular crossing estimate based on observations in multiple CT slices<sup>(12,13)</sup>. This evaluation can be drastically hampered by imaging artifacts from implants such as plates or screws<sup>(6)</sup>. Various thresholds have been proposed for determining bone healing (from 25 to 70%), but an appropriate number has not yet been defined<sup>(13,14)</sup>.

Calcaneal osteotomies are one of the most common procedures in orthopedic surgery, demonstrating high healing rates and few complications<sup>(15,16)</sup>. Since many of the external variables can be controlled when assessing displacement calcaneal osteotomies, they constitute suitable procedures for comparison of implants or techniques. Therefore, this study aims to use HU data from WBCT to compare radiographic outcomes associated with healing of medial displacement calcaneal osteotomies (MDCO) using biointegrative or metallic screws. Our hypothesis is that both types of implants would present similar radiographic results.

## Methods

### Design

This was a prospective comparative study conducted at a single center, the Orthopedic Functional Imaging Research Laboratory at the University of Iowa. The research complied with the Declaration of Helsinki and the Health Insurance Portability and Accountability Act (HIPAA). It was approved by the Institutional Review Board (#201912144) before initiation and did not receive any financial support for its execution.

### Sample

Adult patients (18 to 75 years old) with a clinical and radiographic diagnosis of Progressive Collapsing Foot Deformity (PCFD) undergoing an MDCO between September 2021 and January 2022 were recruited. Patients were excluded if they were found to have a rigid deformity at physical examination, any prior PCFD surgery, or metallic implants in the foot or ankle. Patients with non-traditional calcaneus osteotomies or wedge calcaneus resection, patients with history or documented evidence of peripheral neuropathy, patients with systemic inflammatory disease, and patients unwilling or unable to sign the informed consent form were also excluded.

### Allocation

Patients were allocated to metallic or biointegrative groups at a 1:1 ratio in a sequential, non-randomized, and unblinded fashion. The first patient was placed in the metallic group and the second in the biointegrative group. Subsequent patients were then placed in alternating groups appropriately. Subjects were evaluated independently. The intervention was the same for both groups, with identical arrangements and screw positionings, only diverging in the type of screw used. They were assessed at pre-intervention, then at 2, 6, and 12 weeks after the surgery.

### Interventions

All surgeries were performed by a single fellowship-trained orthopedic foot and ankle surgeon with more than 10 years of experience. Patients in both groups were operated with the same technique and put on the same postoperative protocol, only diverging in the screw material implanted. A traditional MDCO was performed<sup>(17,18)</sup>.

Patients were placed in a supine position after general anesthesia and peripheral block. A 5cm oblique lateral incision was performed over the posterior calcaneus tuberosity, centered on the bone safe zone. Dissection was accomplished, avoiding injury to the sural nerve and the peroneal tendons. After proper saw placement (confirmed by fluoroscopy), a perpendicular cut to the lateral wall of the calcaneus was executed until the far cortex was completely freed up<sup>(19)</sup>. A 10 mm translation of the posterior tuberosity was carried and stabilized with two 1.5 mm Kirschner wires. The wires crossed the osteotomy perpendicular to the cut, one dorsal and the other plantar to the center of the calcaneus. Proper displacement and guide-wire placement was confirmed with fluoroscopy. A 3.2 mm drill was used through the guides, and a 4 mm tap with countersink completed tunnel preparations.

Patients in the metallic group received two metallic headless 4.0 mm titanium cannulated screws (Paragon28®, Denver, CO, USA). Patients in the biointegrative group received two 4.0 mm fiber cannulated screws (Ossio®, Caesarea, Israel). The implants were inserted using hand screwdrivers until entirely inside the bone. Corrections and positions were checked using fluoroscopy. The incision was then sutured in layers, and the patients were placed in a below-knee postoperative

ve splint. They remained non-weight-bearing for six weeks and then were transitioned to a walking boot. The boot was worn until the eighth week, and sports activities were allowed three months after surgery.

## Outcomes

Bone healing was assessed using HU imaging data on WBCT recorded preoperatively, then at 2, 6, and 12 weeks postoperatively<sup>(6)</sup>. WBCT scans were performed with a cone-beam CT lower extremity scanner (HiRise; CurveBeam, LLC, Warrington, PA, USA). Raw multiplanar data were converted into sagittal, coronal, and axial plane images. Using dedicated software (CurveBeam LLC, Warrington, PA, USA), a 40x40x40 mm cube was centered on the osteotomy site, defining a volume of interest (VOI) (Figure 1). Within the VOI, initial computational analysis focused on image intensity (Hounsfield Units) profiles along lines perpendicular to the osteotomy line and to the osteotomy screws, crossing the osteotomy line and spanning approximately 8 mm on either side. Three perpendicular lines were placed for each ankle, with one located directly between the osteotomy screws, one superior to both screws, and one inferior to both screws. The HU intensity profiles were recorded and graphical plots of the HU distributions were generated for each line (Figure 1). The plots were then used to assess the mean, minimum, and maximum HU intensity values for each line, and trends over time for each ankle. The HU contrast, a proxy for bone healing at the osteotomy site, was also calculated.

## Statistical Analysis

Normality of distribution was tested for continuous variables using the Kolmogorov-Smirnov test. Comparisons were

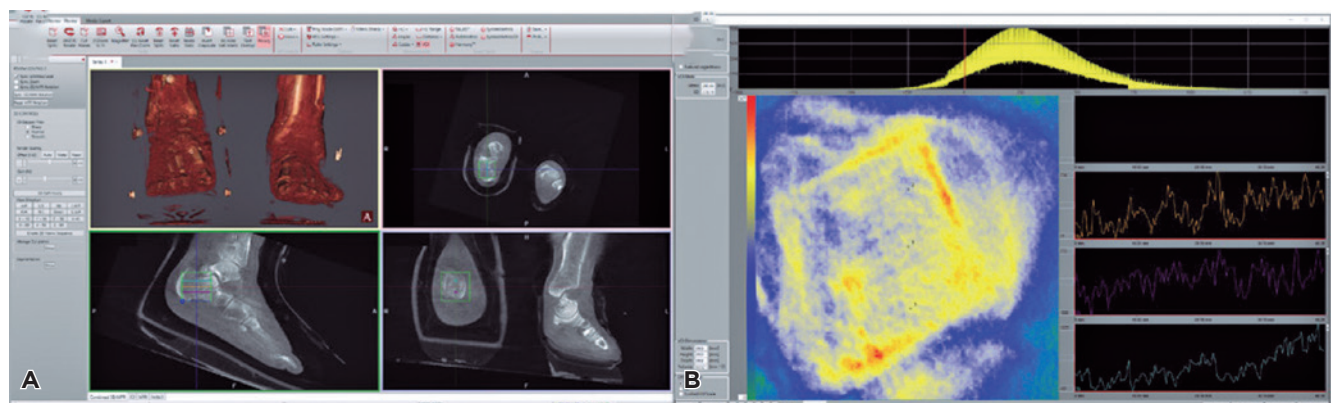
performed using paired *t* tests and chi-square tests. Cohen's *d* and Hedges corrections were utilized. Analyses were performed with SPSS® V20 and Minitab® 16 software. The level of statistical significance was set at 5%, with a 95% confidence interval.

## Results

After assessment of 10 subjects between September 2021 and January 2022, 6 patients were found eligible, included in the study, and allocated. Three patients were assigned to the metallic group (mean age: 50.66, max 65, min 29; mean BMI: 27.78, SD: 6.18) and three were assigned to the biointegrative group (mean age: 47.33, min 26, max 61; mean BMI: 39.35, SD: 7.74). No patients were excluded during follow-up. The groups were similar in age ( $p=0.66$ ), but not in body mass index (BMI) ( $p<0.05$ ).

Preoperative HU calcaneus assessment mean values were different between groups for center (metal: -45.78, SD 108.68 vs bio: 149.54, SD 180.85;  $p<0.001$ ), inferior (metal: -51.30, SD 133.60 vs. bio: 190.64, SD 159.17;  $p<0.001$ ), and superior (metal: 136.61, SD 154.51 vs. bio: 281.53, SD 240.73;  $p<0.001$ ) lines. The minimum and maximum HU values were similar (Table 1). At 2 weeks, mean HU intensities in the metallic and bio-integrative were respectively 403.25 (SD: 398.06) and 416.28 (SD:176.78) at the center line ( $p=0.312$ ), 513.24 (SD: 250.62) and 386.57 (SD: 151.86) at the inferior line ( $p<0.001$ ), and 438.97 (SD: 338.95) and 497.92 (SD: 226.05) at the superior line ( $p=0.020$ ).

Evaluation at 6 weeks demonstrated mean HU intensities of 318.40 (SD: 281.03) and 414.22 (186.12) at the center ( $p<0.001$ ), 340.41 (SD: 212.98) and 356.86 (179.82) ( $p=0.315$ ) at the inferior, and 401.72 (SD: 225.55) and 449.88 (SD: 236.87) at the superior ( $p=0.018$ ) lines. At 12 weeks, HU intensities of -85.01



**Figure 1.** Hounsfield Unit (HU) assessment method for bone intensity. Using the dedicated software (A), the 40x40x40 mm cube was placed centralized on the calcaneal osteotomy in all planes, utilizing the rotation tools. Three 16 mm (8 mm either side of the osteotomy) lines were created. The first line (1) was centered between the two screws, the second (2) inferior to the plantar screw and the third (3) superior to the dorsal screw. Graphical plots (B) of the HU distributions were generated for each line. The plots were then used to calculate the HU contrast, a representation of bone healing at the osteotomy site.

**Table 1.** Values obtained for all variables assessed over the study timeline

Statistics	preop_metal_inter	preop_bio_inter	preop_metal_inf	preop_bio_inf	preop_metal_sup	preop_bio_sup	metal_2_weeks_inter	bio_2_weeks_inter	metal_2_weeks_inf	bio_2_weeks_inf	metal_2_weeks_sup	bio_2_weeks_sup
N	3	3	3	3	3	3	3	3	3	3	3	3
Mean	-45,784	149,546	-51,303	190,647	136,619	281,537	403,235	416,683	513,243	386,571	438,246	497,925
SD	108,683	180,853	133,606	159,172	154,520	240,734	398,069	176,789	250,624	151,863	338,954	226,052
Range	795	949	855	944	1068	1300	2025	973	1292	1002	1864	1283
Minimum	-254	-277	-319	-143	-126	-163	-294	-39	-19	-55	-215	-33
Maximum	541	672	536	801	942	1137	1731	934	1273	947	1649	1250

	metal_6_weeks_inter	bio_6_weeks_inter	metal_6_weeks_inf	bio_6_weeks_inf	metal_6_weeks_sup	bio_6_weeks_sup	metal_12_weeks_inter	bio_12_weeks_inter	metal_12_weeks_inf	bio_12_weeks_inf	metal_12_weeks_sup	bio_12_weeks_sup
N	3	3	3	3	3	3	3	3	3	3	3	3
Mean	318,5	414,228	340,414	356,862	401,728	449,881	-85,014	64,592	-111,367	139,193	225,959	166,055
SD	281,033	186,129	212,988	179,825	222,553	236,873	192,209	142,775	172,773	173,762	209,459	215,689
Range	1309	894	1085	1062	1191	1394	793	624	1085	1048	918	1076
Minimum	-129	-17	-144	-268	-95	-113	-458	-216	-422	-310	-140	-283
Maximum	1180	877	941	794	1096	1281	335	408	663	738	778	793

N: number of patients. SD: standard deviation. Metal: metallic group. Bio: biointegrative group. Inter: intermediate line. Inf: inferior line. Sup: superior line.

(SD: 192.20) and 64.59 (SD: 142.77) were found at the center ( $p < 0.001$ ), -111.36 (SD: 172.77) and 139.19 (SD: 173.76) at the inferior ( $p < 0.001$ ), and 225.95 (209.45) and 166.05 (215.68) at the superior lines respectively ( $p = 0.010$ ) (Table 2). Overall, HU units decreased from the second to the 12th week in both groups ( $p < 0.001$ ) (Figure 2). Considering all lines traced, contrast was higher in the metallic patients in the second week (0.42 to 0.25;  $p = 0.034$ ) and in the 12th week (1.06 to 0.45;  $p = 0.049$ ), but not in the sixth postoperative week (0.48 to 0.30;  $p = 0.064$ ).

## Discussion

This study intended to compare radiographic bone healing in calcaneal osteotomies performed with metallic or bio-integrative implants using HU imaging data. We found higher overall mean HU values in the bio-integrative group for most variables and similar maximum HU values between implants. These results could be translated as similar bone intensity signals when comparing groups. Lower contrast was also observed in the bio-integrative group, showing lower signal variability with this implant. The data presented suggest that our primary outcomes support our main hypothesis.

Use of HU values to assess bone quality is not original and has been described as a valuable tool when studying bony architecture<sup>(20,21)</sup>. Soft tissues and air present lower and negative Hounsfield Units while bone, particularly cortical bone, has higher values<sup>(22)</sup>. Positive correlations between HU values and bone density scans have also been reported, supporting their use in clinical practice<sup>(20)</sup>. However, it wasn't until re-

cently that algorithms to predict joint width space and bone healing were created using data from WBCT<sup>(8,23)</sup>. By incorporating the same rationale, we were able to attest higher bone intensity values in our study when comparing bio-integrative and metallic implants ( $p < 0.01$ ) in most of the crossed lines. Intensities were similar at the intermediate line at 2 weeks ( $p = 0.312$ ) and at the inferior line at 6 weeks. The metallic group had higher HU intensities at the inferior line at 2 weeks ( $p < 0.001$ ) and at the superior line at 6 weeks ( $p < 0.005$ ). The fact that the metallic screws were not superior to the bio-integrative screws suggests that both implants have similar capacity to produce bone intensity signals compatible with healing. Previous studies, using different type of implants, have tried to compare bone healing in unique scenarios. Plaass et al.<sup>(6)</sup> compared magnesium absorbable screws with metallic screws for hallux valgus osteotomies. Using magnetic resonance imaging, these authors could not find differences in bone healing with a 3-year follow-up<sup>(6)</sup>. Leno et al.<sup>(24)</sup> also observed no dissimilarities between absorbable and titanium plates for mandibular fracture union. On the other hand, Noh et al.<sup>(25)</sup> compared metallic and biodegradable plates for ankle fractures, demonstrating shorter time to healing in the metallic group (15.8 vs. 17.6 weeks).

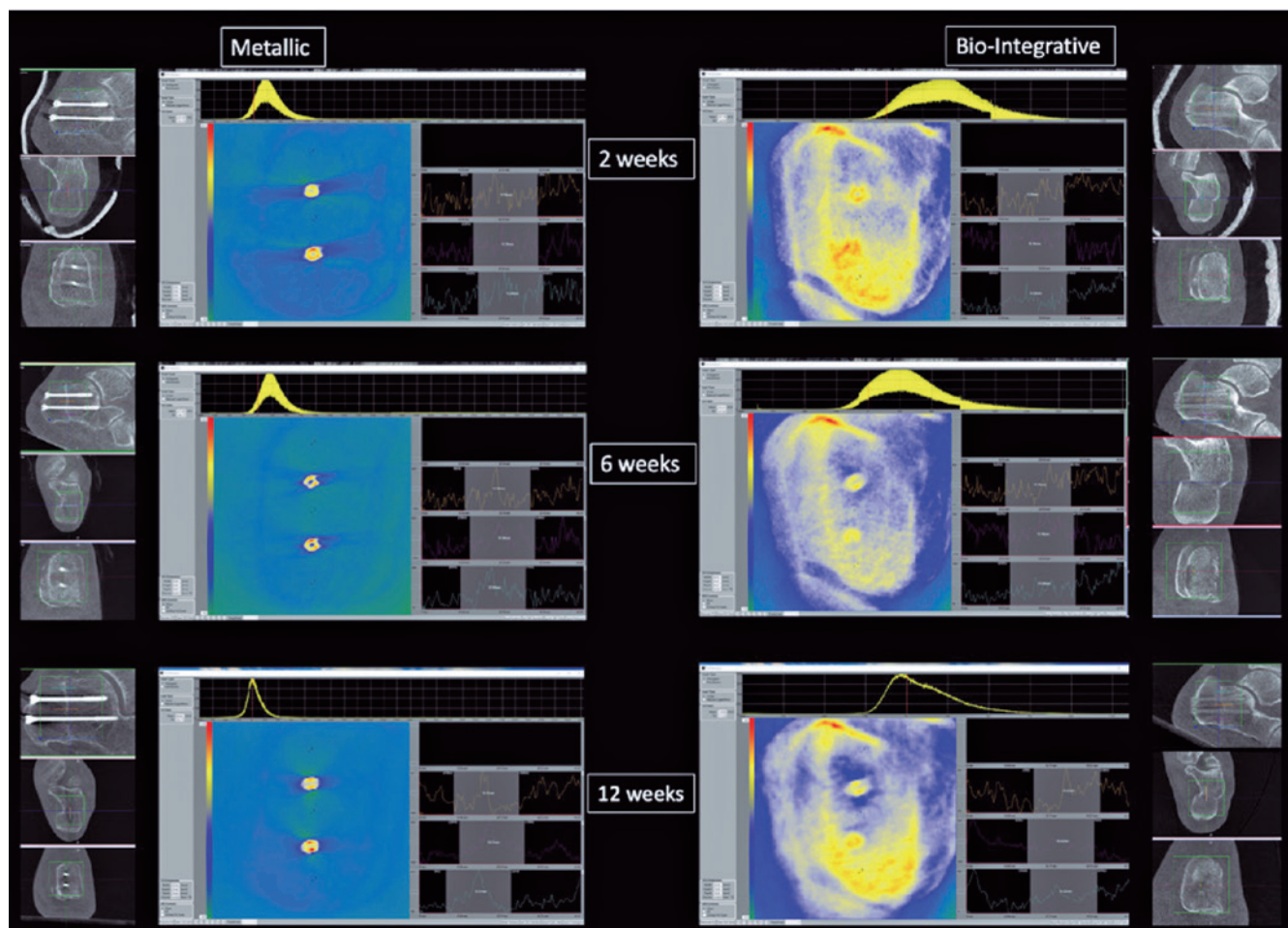
Contrast measures differences in image intensity and, when applied to HU, can translate the variability of a specific anatomical area, such as an articular space or bone-to-bone interface. Our study was able to demonstrate lower mean contrast values for the bio-integrative group at the second (0.42 to 0.25;  $p = 0.034$ ) and 12th weeks (1.06 to 0.45;  $p = 0.049$ ) by evaluating all three lines together. Since this variable is deter-



**Table 2.** Pairwise comparisons of groups along specific timelines. Positive mean difference indicates a higher mean value in the metallic group. Negative mean difference indicates a higher mean value in the biointegrative group. Significant differences are highlighted in bold

		Paired Differences				
		Mean	SD	95% CI Lower	95% CI Upper	p value
Pair 1	preop_metallic_inter - preop_bio_int	-195,33028	201,65913	-222,24975	-168,4108	<b>&lt;.001</b>
Pair 2	preop_metal_inf - preop_bio_inf	-241,94954	182,14296	-266,26381	-217,63528	<b>&lt;.001</b>
Pair 3	preop_metal_sup - preop_bio_sup	-144,91743	288,80731	-183,47032	-106,36454	<b>&lt;.001</b>
Pair 4	metal_2weeks_inter - bio_2weeks_inter	-13,44776	449,7527	-67,53908	40,64355	0,312
Pair 5	metal_2weeks_inf - bio_2weeks_inf	126,67164	327,58123	87,27377	166,06951	<b>&lt;.001</b>
Pair 6	metal_2weeks_sup - bio_2weeks_sup	-59,6791	416,33452	-109,75125	-9,60696	<b>0,01</b>
Pair 7	metal_6weeks_inter - bio_6weeks_inter	-95,72761	311,08541	-133,14155	-58,31368	<b>&lt;.001</b>
Pair 8	metal_6weeks_inf - bio_6weeks_inf	-16,44776	267,39959	-48,60765	15,71212	0,157
Pair 9	metal_6weeks_sup - bio_6weeks_sup	-48,15299	330,41255	-87,89138	-8,41459	<b>0,009</b>
Pair 10	metal_12weeks_inter - bio_12weeks_inter	-149,6055	265,8428	-185,09286	-114,11815	<b>&lt;.001</b>
Pair 11	metal_12weeks_inf - bio_12weeks_inf	-250,55963	245,26333	-283,29984	-217,81943	<b>&lt;.001</b>
Pair 12	metal_12weeks_sup - bio_12weeks_sup	59,90367	341,44234	14,32453	105,48281	<b>0,005</b>

SD: standard deviation, 95%CI: confidence interval of 95%. Metal: metallic group. Bio: biointegrative group. Inter: intermediate line. Inf: inferior line. Sup: superior line.



**Figure 2.** Representation of the analysis over time for one patient from the metallic screw group and one from the biointegrative group. Plots and slices on the left represent the metallic example and those on the right represent the biointegrative example.

mined by the ratio of the difference in maximum and background intensities to the background intensity, lower contrast values may suggest more uniform bone formation (smaller increase in signal over background). Decreased HU (air, soft tissue, or poor bone density) could also be attributed to degenerative joint disease with a diminished articular space or to a higher bone and bone interface compatible with bone healing. Since the sixth week evaluation showed no differences (0.48 to 0.30;  $p=0.064$ ) between groups, we can state that the biointegrative implant was not inferior to the metallic implant when considering bone healing by HU contrast. Moreover, absence of valleys on the graphical plots at 2 weeks postoperatively, which would indicate presence of contiguous low HU values, could be a direct sign of osteotomy compression (Figure 2).


The increased contrast and the abundant presence of negative HU values in some areas of the metallic group (especially the center lines) might be due to a shielding effect associated with metallic screws. A beam hardening effect concentrates HU contiguous to metal, shielding the adjacent cancellous bone<sup>(9)</sup>. This might jeopardize assessment in the daily clinical scenario, requiring artifact reduction sequences that may not normalize the findings completely<sup>(26,27)</sup>. This would be a major confounding factor in our study had the lines not been placed in different locations and assessed independently. Another interesting finding was the diminished overall HU intensity over time during the study, potentially demonstrating the negative effect of the non-weight bearing regime on bone density.

There are several limitations to this study that need to be discussed. First, baseline characteristics differed for BMI,

which might explain the disparities in overall HU values on preoperative WBCT scans. Further, bone healing was only evaluated using one novel imaging method, with no clinical or other radiographical assessment for comparison. No sample calculation or power analysis was performed. We evaluated a small number of subjects over a short follow-up period. Nevertheless, this pilot study was intended to attest the noninferiority of one group in relation to another by utilizing an objective and measurable tool to evaluate bone healing. The same surgeon performed all the surgeries and only one type of metallic and one type of biointegrative screw was used, which could undermine reproducibility of the methods. Finally, the HU algorithm is a novel technique that might not be universally accessible.

## Conclusion

Comparison of bone healing between metallic and bio-integrative screws using our HU algorithm found similar results. Maximum HU intensity values were similar, indicating equivalent results at the osteotomy sites, a finding compatible with consolidation. Contrast was lower in the biointegrative group, indicating lower variability of bone density across the topography studied. Presence of metallic implants across the osteotomy site hampered evaluation of both HU intensity and contrast, presenting a challenge when calculating bone healing through indirect and direct assessments. Larger prospective comparative studies with longer follow-up are needed to endorse these results.

**Authors' contributions:** Each author contributed individually and significantly to the development of this article: NSBM \*(<https://orcid.org/0000-0003-1067-727X>) Conceived and planned the activity that led to the study, data collection, interpreted the results of the study, bibliographic review, formatting of the article, wrote the article; TT \*(<https://orcid.org/0000-0002-3802-3422>) Bibliographic review, wrote the article, data collection, conceived and planned the activity that led to the study; KAMC \*(<https://orcid.org/0000-0003-1082-6490>) Bibliographic review, wrote the article; KCK \*(<https://orcid.org/0000-0002-3731-8448>) Bibliographic review, wrote the article; KD \*(<https://orcid.org/0000-0001-5404-2132>) Bibliographic review, wrote the article; ML \*(<https://orcid.org/0000-0001-5058-8867>) Data collection, wrote the article; CCN \*(<https://orcid.org/0000-0001-6037-0685>) Bibliographic review, wrote the article, formatting of the article. All authors read and approved the final manuscript. \*ORCID (Open Researcher and Contributor ID) 

## References

- Partio N, Mattila VM, Mäenpää H. Bioabsorbable vs. titanium screws for first tarsometatarsal joint arthrodesis: an in-vitro study. *J Clin Orthop Trauma*. 2020;11(3):448-52.
- Daghino W, Bistolfi A, Aprato A, Massè A. Bioabsorbable implants in foot trauma surgery. *Injury*. 2019;50 Suppl 4:S47-s55.
- Debieux P, Franciozi CE, Lenza M, Tamaoki MJ, Magnussen RA, Faloppa F, et al. Bioabsorbable versus metallic interference screws for graft fixation in anterior cruciate ligament reconstruction. *Cochrane Database Syst Rev*. 2016;7(7):Cd009772.
- Clanton TO, Betech AA, Bott AM, Matheny LM, Hartline B, Hanson TW, et al. Complications after tendon transfers in the foot and ankle using bioabsorbable screws. *Foot Ankle Int*. 2013;34(4):486-90.
- Cicchinelli LD, Štalc J, Richter M, Miller S. Prospective, multicenter, clinical and radiographic evaluation of a biointegrative, fiber-reinforced implant for proximal interphalangeal joint arthrodesis. *Foot Ankle Orthop*. 2020;5(4):247301142096631.
- Plaass C, von Falck C, Ettinger S, Sonnow L, Calderone F, Weizbauer A, et al. Bioabsorbable magnesium versus standard titanium compression screws for fixation of distal metatarsal osteotomies - 3 year results of a randomized clinical trial. *J Orthop Sci*. 2018;23(2):321-7.
- Park S, Kim JH, Kim IH, Lee M, Heo S, Kim H, et al. Evaluation of poly(lactic-co-glycolic acid) plate and screw system for bone fixation. *J Craniofac Surg*. 2013;24(3):1021-5.

8. Vandellune C, Tazegul T, J Ahrenholz S, Iehl C, Vivtcharenko V, Schmidt E, et al. Implant-related artifacts around metallic and bio-integrative screws: a CT scan 3D Hounsfield unit assessment. *J Foot Ankle.* 2021;15(2):95-9.
9. Panchbhavi VK, Boutris N, Patel K, Molina D, Andersen CR. CT density analysis of the medial cuneiform. *Foot Ankle Int.* 2013;34(11):1596-9.
10. Coughlin MJ, Grimes JS, Traugber PD, Jones CP. Comparison of radiographs and ct scans in the prospective evaluation of the fusion of hindfoot arthrodesis. *Foot Ankle Int.* 2006;27(10):780-7.
11. Cerrato RA, Aiyer AA, Campbell J, Jeng CL, Myerson MS. Reproducibility of computed tomography to evaluate ankle and hindfoot fusions. *Foot Ankle Int.* 2014;35(11):1176-80.
12. Jones CP, Coughlin MJ, Shurnas PS. Prospective CT scan evaluation of hindfoot nonunions treated with revision surgery and low-intensity ultrasound stimulation. *Foot Ankle Int.* 2006;27(4):229-35.
13. Glazebrook M, Beasley W, Daniels T, Evangelista PT, Donahue R, Younger A, et al. Establishing the relationship between clinical outcome and extent of osseous bridging between computed tomography assessment in isolated hindfoot and ankle fusions. *Foot Ankle Int.* 2013;34(12):1612-8.
14. Dorsey ML, Liu PT, Roberts CC, Kile TA. Correlation of arthrodesis stability with degree of joint fusion on MDCT. *Am J Roentgenol.* 2009;192(2):496-9.
15. Schon LC, de Cesar Netto C, Day J, Deland JT, Hintermann B, Johnson JE, et al. Consensus for the indication of a medializing displacement calcaneal osteotomy in the treatment of progressive collapsing foot deformity. *Foot Ankle Int.* 2020;41(10):1282-5.
16. Kendal AR, Khalid A, Ball T, Rogers M, Cooke P, Sharp R. Complications of minimally invasive calcaneal osteotomy versus open osteotomy. *Foot Ankle Int.* 2015;36(6):685-90.
17. Guha AR, Perera AM. Calcaneal osteotomy in the treatment of adult acquired flatfoot deformity. *Foot Ankle Clin.* 2012;17(2):247-58.
18. Talusan PG, Cata E, Tan EW, Parks BG, Guyton GP. Safe zone for neural structures in medial displacement calcaneal osteotomy: a cadaveric and radiographic investigation. *Foot Ankle Int.* 2015;36(12):1493-8.
19. Sherman TI, Guyton GP. Minimal Incision/Minimally Invasive medializing displacement calcaneal osteotomy. *Foot Ankle Int.* 2018;39(1):119-28.
20. Han K, You ST, Lee HJ, Kim IS, Hong JT, Sung JH. Hounsfield unit measurement method and related factors that most appropriately reflect bone mineral density on cervical spine computed tomography. *Skeletal Radiol.* 2022. doi: 10.1007/s00256-022-04050-4.
21. Silva IMDCC, Freitas DQD, Ambrosano GMB, Bóscolo FN, Almeida SM. Bone density: comparative evaluation of Hounsfield units in multislice and cone-beam computed tomography. *Braz Oral Res.* 2012;26(6):550-6.
22. Willner M, Fior G, Marschner M, Birnbacher L, Schock J, Braun C, et al. Phase-contrast hounsfield units of fixated and non-fixated soft-tissue samples. *PLOS ONE.* 2015;10(8):e0137016.
23. Lintz F, Welck MJ, Buedts K, Fernando C, Netto CDC, Bernasconi A. Distribution of bone mineral density in the ankle joint: correlation with hindfoot alignment. *Foot Ankle Orthop.* 2022;7(1):2473011421S0032.
24. Leno MB, Liu SY, Chen C-T, Liao HT. Comparison of functional outcomes and patient-reported satisfaction between titanium and absorbable plates and screws for fixation of mandibular fractures: a one-year prospective study. *J Craniomaxillofac Surg.* 2017;45(5):704-9.
25. Noh JH, Roh YH, Yang BG, Kim SW, Lee JS, Oh MK. Outcomes of operative treatment of unstable ankle fractures: a comparison of metallic and biodegradable implants. *J Bone Joint Surg Am.* 2012;94(22):e166.
26. Bolstad K, Flatabø S, Aadnevik D, Dalehaug I, Vetti N. Metal artifact reduction in CT, a phantom study: subjective and objective evaluation of four commercial metal artifact reduction algorithms when used on three different orthopedic metal implants. *Acta Radiol.* 2018;59(9):1110-8.
27. Giantsoudi D, De Man B, Verburg J, Trofimov A, Jin Y, Wang G, et al. Metal artifacts in computed tomography for radiation therapy planning: dosimetric effects and impact of metal artifact reduction. *Phys Med Biol.* 2017;62(8):R49-R80.