

Original Article

Distal Metatarsal Metaphyseal Osteotomy (DMMO) for lesser toe metatarsalgia: a case series of 195 osteotomies

Gabriel Ferraz Ferreira^{1,3,5} , Hussein Nasser Fares² , Vinícius Oliveira² , Gustavo Araujo Nunes³ , Augusto César Bravin⁴ , Miguel Viana Pereira Filho^{1,5} 

1. Foot and Ankle Surgery Group, Orthopaedics and Traumatology Unit, Prevent Senior, São Paulo, SP, Brazil.

2. Department of Orthopaedics and Traumatology, Prevent Senior, São Paulo, SP, Brazil.

3. MIFAS by GRECMIP (Minimally Invasive Foot and Ankle Society), Merignac, France.

4. Orthopaedics and Traumatology Unit, Hospital do Coração (HCOR), São Paulo, SP, Brazil.

5. Instituto Vita, São Paulo, SP, Brazil.

Abstract

Objective: The aim of the study was to radiographically evaluate the result of this minimally invasive technique for the surgical treatment of metatarsalgia.

Methods: Radiographic images of 195 osteotomies in 48 patients (65 feet) who were exclusively submitted to the Distal Metatarsal Metaphyseal Osteotomy (DMMO) technique in the central rays (second, third, and fourth metatarsals) with a minimum follow-up of six months were analyzed. Bone healing, metatarsal shortening, and bone healing positioning (central, lateral, or medial) were evaluated. All statistical analysis was performed using the R software, and Wilcoxon statistical tests and Student's *t*-test paired for continuous variables were used.

Results: The mean length of the second metatarsal reduced 7.0mm ($p < 0.001$), the third 6.8mm ($p < 0.001$), and the fourth 6.6mm ($p < 0.001$). In only one case, there was no bone consolidation (second metatarsal). Most osteotomies were consolidated in a central position of the distal fragment.

Conclusion: DMMO showed a high rate of bone healing (99.5%), metatarsal shortening, and consolidation in the central position of the distal fragment when performed in the surgical treatment of metatarsalgia.

Level of Evidence IV; Case Series.

Keywords: Forefoot, human/injuries; Metatarsalgia; Metatarsal bones; Minimally invasive surgical procedures; Osteotomy.

Introduction

Primary metatarsalgia is caused by an anatomical imbalance due to the relative length of the metatarsal bones^(1,2). Without this, harmony can create an unequal mechanical overload, resulting in callosities, pain, and plantar plate rupture⁽³⁾. Therefore, initial treatment is conservative with modification of shoes, symptomatic medication, and physiotherapy. When this approach is unsuccessful, surgical procedures are indicated⁽²⁾.

The surgical procedure aims to shorten and elevate the metatarsal head to relieve pressure in the plantar region of the forefoot and restore optimal harmony to the metatarsal parabola. Some open osteotomies have been described, and one of the most used is Weil osteotomy⁽⁴⁾. Although it has been considered an effective, safe procedure and used by several surgeons, the osteotomy described by Weil has been associated with some complications, such as the so-called floating toe, transfer metatarsalgia, and stiffness⁽⁵⁾.

Study performed at the Orthopaedics and Traumatology Unit, Prevent Senior, São Paulo, SP, Brazil.

Correspondence: Miguel Viana Pereira Filho. Rua Casa do Ator, 1060 - Vila Olímpia - São Paulo, SP, Brazil, 04546-004. **E-mail:** miguel.viana.filho@gmail.com.

Conflicts of interest: none. **Source of funding:** none. **Date received:** June 17, 2022. **Date accepted:** July 26, 2022. **Online:** August 31, 2022.



In the development of minimally invasive techniques for foot and ankle surgery, Redfern and Vernois⁽⁶⁾ described a percutaneous metatarsal osteotomy described as Distal Metatarsal Metaphyseal Osteotomy (DMMO).

The advantages surrounding this minimally invasive osteotomy include the reduced time of surgery with less soft tissue dissection. Furthermore, the technique showed fewer scars while maintaining a range of motion and faster recovery due to immediate weight-bearing in the postoperative period^(1,3).

Although the pioneers of the technique claim that DMMO can be used to correct metatarsophalangeal dislocations requiring up to 5mm of metatarsal shortening⁽⁷⁾, others concluded that due to the limitation in restoring the ideal foot morphology, this procedure should not be indicated in cases of metatarsophalangeal dislocation⁽⁸⁾.

Thus, measuring the length of shortening and the position of metatarsal consolidation after the osteotomy is important, as DMMO is not performed with fixation.

The aim of the study is to radiographically evaluate the result of this minimally invasive DMMO technique for the surgical procedures of metatarsalgia through the outcomes of bone non-union rate, shortening of the metatarsals, and the position of osteotomy consolidation.

Methods

The study was approved by the local ethics committee (CAEE: 32875620.8.0000.5474) and followed the Declaration of Helsinki and the Guidelines for Good Clinical Practice.

The radiographic images of 48 patients diagnosed with metatarsalgia submitted to surgical correction using the DMMO technique were retrospectively evaluated, totaling 65 feet, between December 2017 and December 2019.

All patients were operated on at two orthopedic centers and always by the same team of experienced surgeons specialized in the foot, ankle, and percutaneous surgery.

Inclusion and exclusion criteria

The study included patients with metatarsalgia (pain with callosities in the plantar region of the forefoot or metatarsophalangeal instability) submitted to conservative treatment without improvement for at least six months and undergoing surgical treatment using the DMMO technique. The radiographs included in the study were the preoperative and the last available in the system.

The exclusion criteria were: 1) DMMO associated with metatarsal osteotomies for hallux valgus correction; 2) Inappropriate radiographs; 3) Radiographs not taken at the research centers; 4) The last radiograph less than six months after the surgical procedure; 5) Patient under 18 years of age.

Radiographic evaluation

Four authors performed the radiographic evaluation (HNF, VO, GAN and ACB) after the senior researcher reached a con-

sensus and agreed with the evaluation (MVPF). The analysis was performed digitally using the Centricity® Universal Viewer Zero Footprint software system (GE Healthcare, Barrington, IL, USA). All radiographs were taken in a weight-bearing, standing position.

Radiographs were the method to define bone union and the position of the distal fragment (lateral, central, or medial). It was considered lateral or medial deviation if the cortex of the distal fragment exceeds the center of the diaphysis of the proximal fragment, either laterally or medially. The bone union was defined as the formation of bridging calluses in two radiographic views.

The length of second, third and fourth metatarsals (pre-/postoperative) was also measured digitally, from the center of the base to the center of the head. Follow-up period was defined as the difference between the surgical procedure and the last radiograph.

Surgical technique and postoperative care

The surgical procedure was performed in the supine position with the feet at the end of the table, without a tourniquet, and submitted to spinal anesthesia as an institutional protocol. The technique followed the description in the study by Redfern and Vernois⁽⁶⁾.

A 2.0mm Shannon-type burr, a scalpel blade for percutaneous surgery and an image intensifier was used to locate the osteotomy and the final check. First, the incision was performed using a specific scalpel blade and located with an image intensifier. Then, the periosteum detacher is used for the soft tissue dissection and the metatarsal. Finally, the DMMO was performed in the distal metaphysis in a plane of 45 degrees to the metatarsal axis in the sagittal plane and ending at 90 degrees. The procedure is performed through a rotational movement with supination of the wrist.

After the osteotomy, local cleaning was performed with saline solution and skin suture with 4-0 nylon. Next, the dressing was prepared with sterile gauze and then finished with an elastic bandage.

Postoperative care recommended early ambulation with a stiff soled sandal and full load as tolerated, weekly dressing change, and control radiographs after six weeks.

Statistical Analysis

The statistical analysis was performed using the R software⁽⁹⁾ (The R Foundation, Vienna, Austria). Mean, standard deviation (SD), maximum and minimum were calculated for numerical variables, and descriptive statistics for nominal variables. The Shapiro test was used to assess the distribution of the continuous variables, the paired Student's *t*-test⁽¹⁰⁾ for variables with parametric distribution, and the Wilcoxon⁽¹¹⁾ signed-rank test for non-parametric variables. The $p \leq 0.05$ value was adopted as the level of statistical evidence.

Results

DMMO was performed in 195 metatarsals, 65 feet, in 48 patients. The mean age was 65.9 years, and the SD was 10.1 years. Patients were predominantly female (89.5%), and the left was the most common side (50.8%). The mean follow-up period was 18.2 months (SD 8.3).

Bone union was individually assessed by metatarsal, and only one case of bone non-union was found representing 0.5% (second metatarsal). All third and fourth metatarsals had bone union. Table 1 shows the metatarsal head deviation.

The mean length of the second metatarsal reduced 7.0mm ($p < 0.001$), the third 6.8mm ($p < 0.001$), and the fourth 6.6mm ($p < 0.001$). Figure 1 shows the length distribution.

Discussion

DMMO is an extra-articular metatarsal osteotomy performed percutaneously without any fixation, in which metatarsal lengths are automatically adjusted upon weight-bearing through the interaction of soft tissue structures⁽¹⁾. On the other hand, DMMO has been accompanied by swelling, longer consolidation time, limitation in recreating the ideal foot morphology, and greater metatarsal shortening^(3,8).

Our study presented one case of metatarsal bone non-union among 195 osteotomies performed, representing a union rate of 99.5%. This complication was smaller when compared to Weil's open technique, described in around 3%⁽¹²⁾.

In the study by McMurrich et al.⁽¹³⁾, the authors performed the DMMO with bone consolidation in all osteotomies and

were evaluated by radiographic images. Haque et al.⁽¹⁾ performed DMMO in a total sample of 30 patients and had one case of bone non-union.

Bone non-union or delayed union may be a complication with clinical repercussions such as pain and swelling. Although this study did not perform the patients' clinical evaluation, the only case with bone non-union was not submitted to surgical revision, inferring the probable fibrous union, as described by Ferreira et al.⁽¹⁴⁾, in the percutaneous oblique distal osteotomy of the fifth metatarsal.

After the DMMO, there was an expected shortening of the metatarsals: the second metatarsal represented the greatest reduction, followed by the third and fourth. This shortening differs from the McMurrich et al.⁽¹³⁾ study, where the third represented the greatest difference, followed by the fourth and second metatarsal.

In addition, the mean shortening was higher in our study. Still, the comparison with other studies may show a measurement bias due to the absence of the pattern of radiographic images and different digital software.

The position of bone consolidation of the distal fragment was classified as central in most osteotomies. This result could be due to the non-inclusion of cases in which osteotomies were performed to correct the hallux valgus because the distal fragment tends to be displaced to the lateral region, for example, in the Percutaneous Chevron-Akin technique⁽¹⁵⁾. Weight-bearing computed tomography would be ideal for performing these measurements, but availability is still very limited.

Table 1. Postoperative radiographic results

Outcome	Second metatarsal	Third metatarsal	Fourth metatarsal
Position of the Distal Fragment	Central = 80.0% Medial = 0% Lateral = 20.0%	Central = 75.4% Medial = 3.1% Lateral = 21.5%	Central = 81.5% Medial = 12.3% Lateral = 6.2%
Bone Union	98.5%	100%	100%

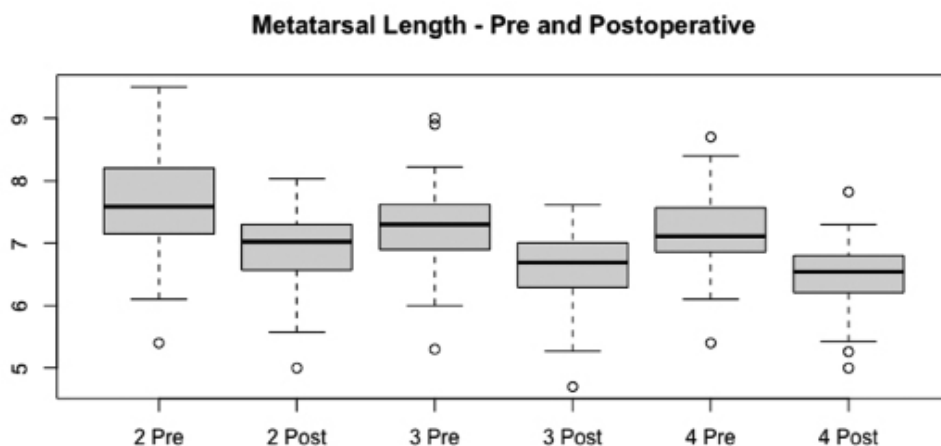


Figure 1. Distribution of metatarsal length before and after the surgical procedure.


The results suggest that the DMMO technique has a high rate of bone union in osteotomies and that the surgeon often must wait at least six months in cases where there is a delay in the bone union process.

Our study has some limitations. First, clinical and functional analyses were not included. Second, radiographic measurements show intra- and inter-examiner variations. Third, the study did not assess bone union time. Finally, the study would

have more strength if weight-bearing computed tomography was used for pre-/postoperative evaluation.

Conclusion

DMMO showed a high rate of bone healing (99.5%), metatarsal shortening, and consolidation in the central position of the distal fragment when performed in the surgical treatment of metatarsalgia.

Author's contributions: Each author contributed individually and significantly to the development of this article: GFF *(<https://orcid.org/0000-0001-8032-3077>) Performed the surgeries, wrote the article, participated in the review process, bibliographic review, formatting of the article, interpreted the results of the study, statistical analysis and collected the data; HNF *(<https://orcid.org/0000-0002-9261-3757>) Wrote the article, participated in the review process, bibliographic review, formatting of the article, interpreted the results of the study and collected the data; VO *(<https://orcid.org/0000-0002-1087-046X>) Wrote the article, participated in the review process, bibliographic review, formatting of the article, interpreted the results of the study and collected the data; GAN *(<https://orcid.org/0000-0003-4431-5576>) Wrote the article, participated in the review process, bibliographic review, formatting of the article, interpreted the results of the study; ACB *(<https://orcid.org/0000-0002-2894-9715>) Wrote the article, participated in the review process, bibliographic review, formatting of the article, interpreted the results of the study; MVPF *(<https://orcid.org/0000-0002-2320-9769>) Performed the surgeries, wrote the article, participated in the review process, bibliographic review, formatting of the article, interpreted the results of the study, statistical analysis and collected the data. All authors read and approved the final manuscript. *ORCID (Open Researcher and Contributor ID) 

References

1. Haque S, Kakwani R, Chadwick C, Davies MB, Blundell CM. Outcome of minimally invasive distal metatarsal metaphyseal osteotomy (DMMO) for lesser toe metatarsalgia. *Foot Ankle Int.* 2016;37(1):58-63.
2. Federer AE, Tainter DM, Adams SB, Schweitzer KM Jr. Conservative management of metatarsalgia and lesser toe deformities. *Foot Ankle Clin.* 2018;23(1):9-20.
3. Malhotra K, Joji N, Mordecai S, Rudge B. Minimally invasive distal metaphyseal metatarsal osteotomy (DMMO) for symptomatic forefoot pathology - Short to medium term outcomes from a retrospective case series. *Foot (Edinb).* 2019;38:43-9.
4. Vandeputte G, Dereymaeker G, Steenwerckx A, Peeraer L. The Weil osteotomy of the lesser metatarsals: a clinical and pedobarographic follow-up study. *Foot Ankle Int.* 2000;21(5):370-4.
5. Trnka HJ, Nyska M, Parks BG, Myerson MS. Dorsiflexion contracture after the Weil osteotomy: results of cadaver study and three-dimensional analysis. *Foot Ankle Int.* 2001;22(1):47-50.
6. Redfern DJ, Vernois J. Percutaneous surgery for metatarsalgia and the lesser toes. *Foot Ankle Clin.* 2016;21(3):527-50.
7. De Prado M, Cuervas-Mons M, Golanó P, Vaquero J. Distal metatarsal minimal invasive osteotomy (DMMO) for the treatment of metatarsalgia. *Tech Foot Ankle Surg* 2016;15(1):12-8.
8. Henry J, Besse JL, Fessy MH; AFCP. Distal osteotomy of the lateral metatarsals: a series of 72 cases comparing the Weil osteotomy and the DMMO percutaneous osteotomy. *OrthopTraumatol Surg Res.* 2011;97(6 Suppl):S57-65.
9. Core Team R (2020). R: A language and environment for statistical computing. In: R Foundation for Statistical Computing, Vienna, Austria. Available from: <https://www.r-project.org/>
10. Kalpić D, Hlupić N, Lovrić M. Student's t-Tests. In: Lovric M, editor. *International encyclopedia of statistical science.* Berlin, Heidelberg: Springer Verlag; 2011. p. 1559-63.
11. Rey D, Neuhäuser M. Wilcoxon-signed-rank Test. In: Lovric M, editor. *International encyclopedia of statistical science.* Berlin, Heidelberg: Springer Verlag; 2011. p. 1658-9.
12. Highlander P, VonHerbulis E, Gonzalez A, Britt J, Buchman J. Complications of the Weil osteotomy. *Foot Ankle Spec.* 2011;4(3):165-70.
13. McMurrich W, Peters A, Ellis M, Shalaby H, Baer G, MacDonald D, et al. MIS Distal Metatarsal Metaphyseal Osteotomy in the treatment of metatarsalgia: MOXFQ patient reported outcomes. *Foot (Edinb).* 2020;43:101661.
14. Ferreira GF, Dos Santos TF, Oksman D, Pereira Filho MV. Percutaneous oblique distal osteotomy of the fifth metatarsal for bunionette correction. *Foot Ankle Int.* 2020;41(7):811-7.
15. Redfern D, Vernois J. Minimally Invasive Chevron Akin (MICA) for correction of hallux valgus. *Tech Foot Ankle Surg.* 2016;15(1):3-11.