

Case Report

Reconstruction of extensive bone loss of the first metatarsal with osteodistraction and homologous graft in an immature skeleton: case report

Pedro Henrique Silva Benevides¹ , Allyson Cândido de Abreu¹ , João Emílio Hanum Paes¹ , Salyme El Kadi¹ ,
Walter de Freitas Junior¹ , Jefferson Soares Martins^{1,2} 

1. Hospital de Urgências de Goiânia, Goiânia, Goiás, Brazil.

2. Hospital das Clínicas da Universidade Federal de Goiás/EBSERH, Goiânia, Goiás, Brazil.

Abstract

Reconstruction of extensive bone loss in the foot requires a set of strategies involving various surgical techniques and orthopedic devices. Semicircular Ilizarov external fixator combined with a structural homologous bone graft may be advantageous in pediatric patients. This case report describes the technique of reconstructing an extensive bone loss of the first metatarsal with osteodistraction and homologous graft in an immature skeleton. The combination of the external fixator and the homologous graft provided sufficient bone volume without recurrent infection, minimal complications, substantial length gain of the metatarsal bone, and improved soft tissue conditions. It is a viable treatment option for severe foot injuries in immature skeletons.

Level of Evidence V; Therapeutic Studies; Expert Opinion.

Keywords: Metatarsus; Foot deformities; Bone transplantation; Child; Growth.

Introduction

Reconstruction of bone loss in the foot requires a set of strategies involving surgical techniques and orthopedic devices. Bone losses between 2 and 4 cm can be treated with an autogenous bone graft^(1,2). Bone grafts have a well-established role in orthopedic surgery, but filling metaphyseal defects is associated with complications that include postoperative pain and morbidity⁽³⁾.

In treating large bone defects, extensive grafts are often required, which is limited to the amount of autologous bone available. Furthermore, in skeletally immature patients, the choice of the autologous graft should consider the risk of damage to the growing physis and the amount of graft available. Thus, a structural homologous bone graft may be advantageous due to biocompatibility, the capacity for bone stock restoration, and potential of ligament reinsertion⁽⁴⁾.

There are a limited number of case reports and scientific articles regarding the reconstruction of bone loss in the foot using osteodistraction and homologous graft in pediatric pa-

tients. The aim of this case report is to describe the technique of reconstructing an extensive bone loss of the first metatarsal with osteodistraction and homologous graft in an immature skeleton for five years of follow-up.

Case Report

The patient and her legal guardian consented to this case report and signed the informed consent form. The study was approved by the Ethics Committee under registration CAAE n. 56135522.5.0000.0033.

A female patient, hit by a car at age five, suffered severe trauma to the left foot, large soft tissue injury, and exposed fracture Gustillo and Anderson IIIB. Returns to the outpatient clinic at the age of 11 to treat the left hallux shortening in the extended position, associated with scar retraction, great functional limitation, ability to walk, and difficulty wearing closed shoes (Figure 1). Reconstruction of bone loss was performed with osteodistraction and homologous graft according to the surgical procedure described below.

Study performed at the Hospital de Urgências de Goiânia, Goiânia, Goiás, Brazil.

Correspondence: Pedro Henrique Silva Benevides. Rua 54, esq. 58, nº 2, Jardim Goiás, Edifício Residencial Caraibas, apto 101. Goiânia, GO, Brazil, 74810220.

E-mail: phsilvabenevides1@gmail.com. **Conflicts of interest:** none. **Source of funding:** none. **Date received:** July 08, 2022. **Date accepted:** August 16, 2022. **Online:** August 31, 2022.



The patient was in dorsal decubitus under spinal anesthesia with a lateral cushion and tourniquet at thigh level. The external fixator Ilizarov semicircular (Figure 2) was placed with a planned assembly of three rings, one in the medial and middle foot wedge, one in the head remnant of the first metatarsal, and one in the proximal and distal phalanx of the hallux, fixed with 4.0mm Schanz pins for bone distraction and soft

tissue elongation and arthrodiastasis. A Z-plasty incision was made to correct the scar retraction and deviation in the hallux extension. It was instructed to proceed with soft tissue elongation and bone 1mm per day, four times of 0.25mm in the two distal half-rings, ten days after surgery, for 60 days. The patient presented superficial soft tissue infection, treated with cefadroxil 500mg every 12 hours for ten days. After 90 days, the circular external fixator was removed, and weak bone regeneration was observed, improving the appearance of soft tissues and scar retraction (Figure 3). The patient was submitted to new surgery with a soft tissue incision, dissection by planes, and preparation of the receiving area (Figure 4). Metatarsophalangeal arthrodesis was performed without joint preparation, only decortication due to the poor quality of the joint, as described below. The tricortical iliac graft was removed from the mother, and the bone loss was filled with two unblocked plates and mini fragments. The patient evolved with a good appearance wound, mild dehiscence treated with dressings, and resolution of the soft part aspect. After six months of follow-up, good bone consolidation, no signs of infection, osteolysis, or loosening of materials were observed through clinical and radiological evaluation (Figure 5). The patient reported high satisfaction with the surgical, aesthetic, and functional results and mild pain⁽²⁾ evaluated through the Visual Analog Pain Scale⁽⁵⁾. In the five years of follow-up (Figure 5) of the initial approach, the patient does not want

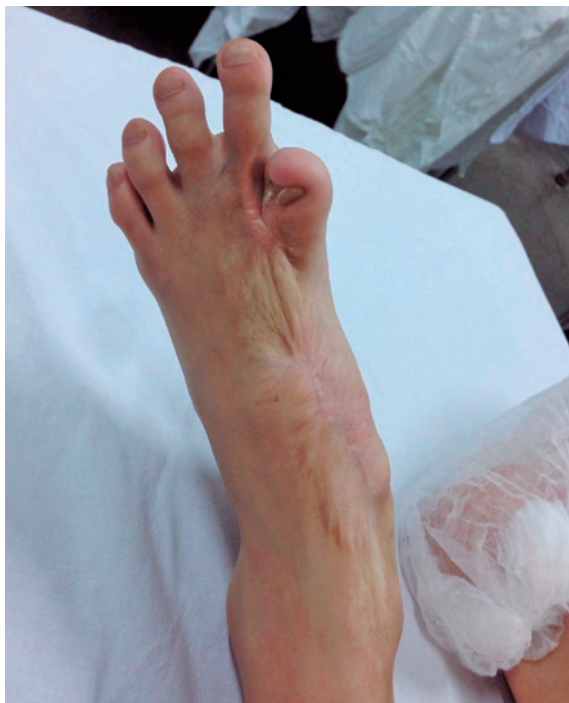

Figure 1. Patient with left hallux shortening.

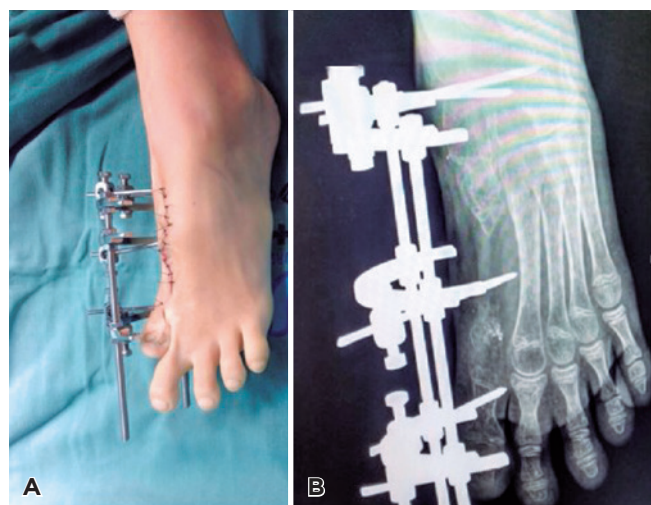


Figure 2. A) Clinical and radiological. B) Postoperative aspects with semicircular Ilizarov external fixator.

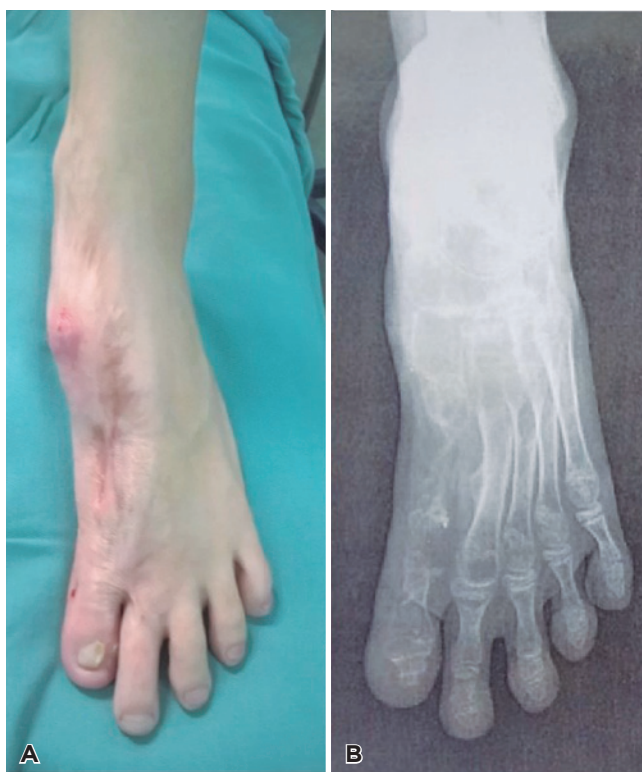

Figure 3. A) Postoperative appearance and radiography. B) After external fixator removal.

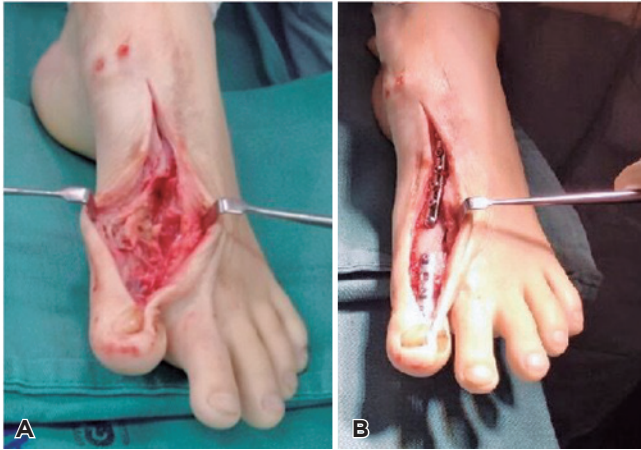

Figure 4. A) Intraoperative after bone elongation and B) Intraoperative after grafting and placement of plates.

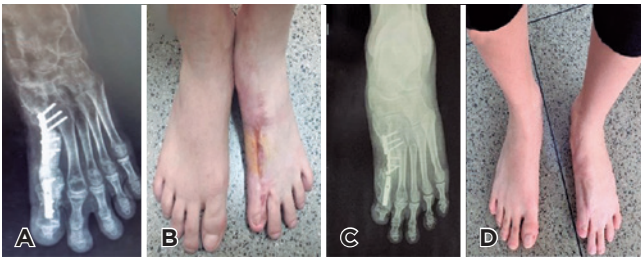

Figure 5. A-B) Radiological and clinical evaluation after six months and C-D) five years of follow-up.

any subsequent surgery, even with functional shortening, reporting being satisfied with this result.

Discussion

In the scientific literature, there are few studies on restoring complex foot injuries in immature skeletons⁽⁶⁾. Osteogenic distraction by the Ilizarov method is one of the most used techniques in treating fractures with bone loss. This method

includes a circular external fixator and the translocation of a bone segment from a healthy donor area to the bone loss region⁽⁷⁾. The combination of osteogenic distraction and zeta-plasty allows the skin and soft tissue elongation to be achieved, avoiding the recurrence of contractures and the use of skin grafts⁽⁸⁾.

In reconstructing bone loss in immature skeletons, the use of iliac bone graft remains the “gold standard”⁽⁹⁾. However, in this case, the skeletal immaturity, the possibility of growing physis involvement, the scarring in the graft donor area, and the limited amount of material were considered negative points in the choice of autologous graft. Thus, the homologous graft was chosen considering the disadvantages presented, the absence of a bone bank available in the region and the possibility of the mother as a donor of the bone graft.


Canzi et al.⁽¹⁰⁾ reported two successful cases of large cranial loss reconstruction using structural homologous bone grafts in pediatric patients. The authors highlighted that the risk of infections was minimal when compared to high quality, biomechanical stability, and absence of evident interference in long-term growth.

In a recent study, Jogani et al.⁽⁶⁾ reported the bone reconstruction of the first metatarsal after severe foot trauma using the external fixator associated with the Masquelet technique in a 62-year-old male patient with injury of the first metatarsal and proximal part of the phalanx, after 24 months postoperatively satisfactory functional results were obtained and the total incorporation of the fibular graft.

In this study, the combination of osteogenic distraction associated with the homologous graft in an immature skeleton presented satisfactory results, without recurrent infection, with minimal complications from external fixators and substantial length gain of the metatarsal bone.

Conclusion

The reconstruction of extensive bone loss of the first metatarsal with osteodistraction and homologous graft in an immature skeleton was able to promote an almost total restoration of bone length and improve soft tissue conditions, being a viable treatment option in severe foot injuries in pediatric patients.

Authors' contributions: Each author contributed individually and significantly to the development of this article: PHSB *(<https://orcid.org/0000-0002-0275-1401>) Conceived and planned the activities that led to the study, participated in the review process, participated in the writing of the article, data collection, approved the final version; ACA *(<https://orcid.org/0000-0002-9983-1888>) Participated in the review process, formatting of the article, participated in the writing of the article, approved the final version; JEHP *(<https://orcid.org/0000-0002-9340-2337>) Participated in the review process, bibliographic review, survey of the medical records, participated in the writing of the article, approved the final version; SEK *(<https://orcid.org/0000-0003-3132-924X>) Participated in the review process, formatting of the article, participated in the writing of the article, approved the final version; WFJ *(<https://orcid.org/0000-0001-7340-870X>) Interpreted the results of the study, participated in the review process, participated in the writing of the article, approved the final version; JSM *(<https://orcid.org/0000-0003-4742-1905>) Interpreted the results of the study, participated in the review process, participated in the writing of the article, approved the final version. All authors read and approved the final manuscript. *ORCID (Open Researcher and Contributor ID) 

References

1. Stafford PR, Norris BL. Reamer-irrigator-aspirator bone graft and bi Masquelet technique for segmental bone defect nonunions: a review of 25 cases. *Injury*. 2010;41 Suppl 2:S72-7.
2. Wiese A, Pape HC. Bone defects caused by high-energy injuries, bone loss, infected nonunions, and nonunions. *Orthop Clin North Am*. 2010;41(1):1-4.
3. Keating JF, McQueen MM. Substitutes for autologous bone graft in orthopaedic trauma. *J Bone Joint Surg Br*. 2001;83(1):3-8. Erratum in: *J Bone Joint Surg Br*. 2001;83(5):777.
4. Pedro LL, Alves BA, Andrade CA, Maluf Neto J, Lovisotto LA. Hallux varus: case report and literature review. *Rev ABTPé*. 2015; 9(2):98-103.
5. Huskisson EC. Measurement of pain. *Lancet*. 1974;2(7889):1127-31.
6. Jogani AD, Garje V, George PK, Rathod T, Bhaladhare SM. Reconstruction of first metatarsal bone loss following osteomyelitis by a modified Masquelet technique: a case report. *J Orthop Case Rep*. 2020;10(9):118-20.
7. Aktuglu K, Erol K, Vahabi A. Ilizarov bone transport and treatment of critical-sized tibial bone defects: a narrative review. *J Orthop Traumatol*. 2019;20(1):22.
8. Müller-Seubert W, Cai A, Arkudas A, Ludolph I, Fritz N, Horch RE. A personalized approach to treat advanced stage severely contracted joints in Dupuytren's disease with a unique skeletal distraction device-utilizing modern imaging tools to enhance safety for the patient. *J Pers Med*. 2022;12(3):378.
9. Hofmann A, Gorbulev S, Guehring T, Schulz AP, Schupfner R, Raschke M, et al. Autologous iliac bone graft compared with biphasic hydroxyapatite and calcium sulfate cement for the treatment of bone defects in tibial plateau fractures: a prospective, randomized, open-label, multicenter study. *J Bone Joint Surg Am*. 2020;102(3):179-93.
10. Canzi G, Talamonti G, Mazzoleni F, Bozzetti A, Sozzi D. Homologous Banked Bone Grafts for the Reconstruction of Large Cranial Defects in Pediatric Patients. *J Craniofac Surg*. 2018;29(8):2038-42.