

Systematic Review

Reconstruction of the extensor hallucis longus with a hamstring tendon autograft: a systematic review

Dov Lagus Rosemberg^{1,2,3,4,5} , Edward S. Hur¹ , Glauca Bordignon^{1,2,3,6} , Daniel D. Bohl¹ 

1. Department of Orthopaedic Surgery, Rush University Medical Center, Chicago, IL, United States.

2. International Research Fellow of Instituto Brasil de Tecnologias da Saúde (IBTS), Rio de Janeiro, RJ, Brazil.

3. International Scholar at the Midwest Orthopedics at Rush (MOR) Chicago, IL, United States.

4. RUSH-IBTS International Fellowship Program.

5. Lab. Prof. Manlio Mario Marco Napoli, Instituto de Ortopedia e Traumatologia, Hospital das Clínicas, Faculdade de Medicina, Universidade de São Paulo, SP, Brazil.

6. Hospital Municipal Universitário de Taubaté, Taubaté, SP, Brazil.

Abstract

Objective: The purpose of this study was to systematically review the literature regarding the use of hamstring tendon (HT) autograft for extensor hallucis longus (EHL) reconstruction.

Methods: A systematic search for studies addressing the use of HT autograft for reconstruction of nonrepairable EHL tendon injuries was performed in December 2021. The databases searched include Embase, Medline, Europe PMC, Cochrane, and Scopus. Predetermined inclusion and exclusion criteria were implemented, and appropriate studies were selected for review.

Results: The database search resulted in one study that met the inclusion and exclusion criteria. Three additional studies met inclusion and exclusion criteria after screening the references of the selected study. A total of four studies were included in the final review. Clinical presentation, surgical technique, postoperative rehabilitation, clinical follow-up, and outcomes were recorded. All four studies reported single cases of EHL tendon reconstruction using a semitendinosus autograft with satisfactory clinical results and no complications. Patients may experience a five degrees decrease in range of motion or minimal decrease in hallux extension strength; however, all patients were asymptomatic and reported no limitations.

Conclusion: Four case reports regarding EHL tendon reconstruction were reviewed and demonstrated using a semitendinosus autograft as a viable option with favorable outcomes and no complications.

Level of Evidence IV; Systematic Review

Keywords: Autograft; Extensor hallucis longus; Hamstring tendons; Tendon injuries.

Introduction

The extensor hallucis longus (EHL) muscle originates along the anterior fibula, travels distally under the extensor retinaculum of the ankle, and courses superficially along the dorsal foot where the distal tendon inserts on the base of the distal phalanx of the hallux⁽¹⁾. The primary function of the EHL is the extension of the hallux interphalangeal (IP) joint, and it works with the extensor hallucis brevis (EHB) to extend the metatarsophalangeal (MP) joint. In addition, it contributes to dorsiflexion of the ankle and inversion of the foot, but other

muscles, such as the tibialis anterior, can also perform these functions.

The overall incidence of EHL rupture has not been well-defined. Anzel et al.⁽²⁾ reviewed 1,014 cases of various muscle and tendon injuries, noting 16 cases (1.5%) were injuries to the toes extensors. Open laceration is the most commonly described injury mechanism for EHL tendon injury⁽³⁾; however, closed traumatic rupture^(4,5), attritional rupture⁽⁶⁾, and iatrogenic injury have also been reported⁷. In addition, a higher prevalence of EHL pathology has been observed in martial

Study performed at the Department of Orthopaedic Surgery, Rush University Medical Center, Chicago, IL, United States.

Correspondence: Dov Lagus Rosemberg, Rush University Medical Center, Midwest Orthopedics at Rush, 1611, West Harrison St, Chicago, IL, United States, 60612. **E-mail:** dr.dovr@gmail.com. **Conflicts of interest:** none. **Source of funding:** none. **Date received:** July 22, 2022. **Date accepted:** November 03, 2022. **Online:** December 20, 2022.

How to cite this article: Rosemberg DL, Hur ES, Bordignon G, Bohl DD. Reconstruction of the extensor hallucis longus with a hamstring tendon autograft: a systematic review. *J Foot Ankle.* 2022;16(3):310-6.



art practitioners compared to the general population⁽⁶⁾. When patients present with an acute tendon rupture, surgical treatment is indicated in the acute setting with direct end-to-end primary repair of the tendon⁽⁹⁻¹¹⁾. These patients have favorable outcomes with restoring function and returning to their previous activity levels^(3,12-15). Nonoperative treatment can be considered in ruptures distal to the extensor expansion, patients with limited activity levels, or patients with medical comorbidities precluding operative intervention^(9,16).

Some patients may present to a medical provider in a delayed fashion with a chronic injury, which cannot undergo direct repair secondary to tendon retraction and scar tissue formation^(9,17,18). For this situation, local tendon transfers or tendon reconstruction procedures using allograft or autograft have been described^(6,17,19-27). The use of hamstring tendon (HT) autograft has been reported for various foot and ankle reconstruction surgeries with minimal donor site morbidity⁽²⁸⁾. The purpose of this study is to perform a systematic literature review regarding EHL tendon reconstruction using HT autograft.

Methods

Database search

A systematic literature search was performed in December 2021 to evaluate the use of HT autograft for EHL reconstruction.

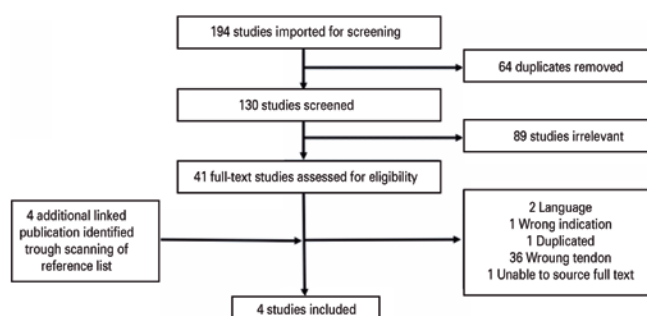


Figure 1. Flow chart of literature search and study selection procedure.

The search was conducted in the following databases: Embase, Medline, Europe PMC, Cochrane, Scopus, and Scielo. The search terms used include ((ankle OR (foot)) AND (autograft) AND (hamstring) AND (tendon reconstruction) NOT (ligament).

Study selection criteria

After performing the database search, duplicate articles were eliminated. The remaining studies were reviewed to be considered in the systematic review. Inclusion criteria were the use of an HT autograft for EHL reconstruction. For this study, the gracilis tendon and semitendinosus tendon were considered. The exclusion criteria include EHL reconstruction with grafts other than HT autograft, use of the HT autograft in other tendons reconstruction, use of HT autograft for ligament reconstruction, absence of the surgical technique description, and articles not available in the authors' primary language. Additionally, the references of the selected studies were screened and included in the final review if inclusion and exclusion criteria were met.

Study review

The selected studies were reviewed. Patient clinical presentation, surgical technique, postoperative protocol, clinical follow-up, and outcomes were recorded.

Results

Study selection

After performing the described database search, 194 articles were identified for review (Figure 1). Sixty-four were duplicates, remaining 130 unique studies for review. After applying the inclusion and exclusion criteria, a single study was selected for full-text analysis. The references from this study were reviewed, and four additional studies were identified for further analysis. Among the additional studies, one full-text was unable to be obtained, and the study was excluded⁽²⁹⁾. For the final review, four studies were included (Table 1)^(7,17,24,30)

Table 1. Details of the selected studies included in the review

Author	Year	Age	Sex	Mechanism of Injury	Chronicity	Follow-up (months)	Outcome
Park et al.	2003	15	Male	Taekwondo	1 year of symptoms, Inability to extend hallux for 2 weeks	6	Slightly decreased extension strength Normal range of motion
Tuncer et al.	2010	40	Male	Iatrogenic	4 months after ankle arthroscopy, 6 weeks after acute rupture	12	No symptoms
Lohrer et al.	2012	32	Female	Sprinting, Roller Skating	3 years of symptoms, 6 previous surgeries for EHL tenosynovitis	19	Full Strength Limited flexion of 5°
Kwapisz et al.	2017	18	Male	Kickboxing	2 years of symptoms, Inability to extend hallux for 10 months	8	Minimal limitation of extension strength Limited extension of 5°

Regarding the study where the full-text article could not be obtained, the abstract was reviewed. The abstract describes a case report regarding a 61-year-old female who presented with a chronic EHL tendon laceration that failed a previous repair and subsequently underwent tendon reconstruction using a gracilis tendon autograft and IP joint arthrodesis⁽²⁹⁾. No surgical technique description, patient follow-up, or postoperative outcomes were available for review. Thus, this study was excluded from the final review.

Clinical Presentations

The studies selected for review include four case reports describing using a semitendinosus autograft for EHL reconstruction. Park et al.⁽²⁴⁾ reported a case of a 15-year-old male who experienced three or four episodes of a painful pop in his foot over one year and presented with an inability to extend his hallux for two weeks. Examination revealed an inability to extend the IP joint of the hallux with associated flexion deformity, but passive range of motion (ROM) was preserved. Ultrasound imaging showed multifocal partial ruptures of the EHL tendon with associated tendon thickening and increased fluid within the tendon sheath.

Tuncer et al.⁽⁷⁾ described a case of iatrogenic injury to the EHL in a 40-year-old male submitted to arthroscopic debridement for early degeneration of the tibiotalar joint where the anterior joint capsule was breached using a radiofrequency probe and the extensor tendons were exposed, but no tendon injury was noted. The patient experienced a painful pop in the anterior ankle ten weeks postoperatively. Clinical examination revealed an inability to extend the first three toes. Rupture of the EHL, second, and third extensor digitorum longus (EDL) tendons was diagnosed. The diagnosis was confirmed with magnetic resonance imaging (MRI). The patient initially deferred surgical treatment, but he ultimately underwent EHL reconstruction with a semitendinosus graft and direct repair of the EDL tendons six weeks later.

Lohrer and Nauck.⁽³⁰⁾ presented a case of a 32-year-old female who was a former world champion in roller skating with a history of six prior surgeries in the previous three years for EHL tenosynovitis. The patient experienced a painful pop in the foot when sprinting two days before evaluation. Physical examination revealed a flexion deformity of the hallux, an inability to extend the IP joint of the hallux, and normal passive ROM. No advanced imaging was reported for further evaluation of the injury.

Kwapisz et al.⁽¹⁷⁾ reported a case of an 18-year-old male kickboxer who experienced two years of pain over the dorsum of his foot and ten months of inability to extend the hallux. Exam revealed an inability to extend the IP joint of the hallux and weakness with extension at the MP joint. Normal passive ROM was observed. The diagnosis of EHL tendon rupture was confirmed with ultrasound and MRI.

Surgical Technique

Three authors described using a two-incision technique to isolate the EHL tendon stumps^(7,24,30), while Kwapisz et al.⁽¹⁷⁾

did not describe the incisions used. In general, a longitudinal incision over the dorsal aspect of the hallux IP joint is used to identify the distal stump of the EHL tendon. The second incision is used to identify the proximal stump of the EHL tendon and is based on the proximal aspect of the anterior ankle to expose the extensor retinaculum and associated tendons. Once the tendon stumps were identified proximally and distally, areas of obvious nonviable and degenerative tendons were debrided^(7,17). A description of semitendinosus autograft harvest was not reported in any of the studies.

After identification of the tendon stumps, the semitendinosus autograft was passed between the two incisions for reconstruction. Kwapisz et al.⁽¹⁷⁾ established tension of the EHL tendon reconstruction with the ankle in a neutral position and the hallux joints in dorsiflexion, then performed an end-to-end suturing technique for graft fixation distally and circumferential repair to the stump proximally. Lohrer and Nauck.⁽³⁰⁾ defined the tension of the tendon reconstruction with both the ankle and hallux held in dorsiflexion. Distal fixation of the HT autograft was performed using a transosseous technique at the hallux's distal phalanx, and proximal fixation was performed with a side-to-side anastomosis to the proximal EHL stump. In addition, the position of the hallux IP joint was held with temporary Kirschner wire fixation that was removed at four weeks postoperatively. The remaining two studies did not provide details regarding setting tension of the reconstruction, and both opted to perform the Pulvertaft suture technique proximally and distally for fixation^(7,24).

In our practice, a single longitudinal incision over the anterior ankle and dorsal aspect of the foot is performed to evaluate the entirety of the tendon and identify the zone of injury (Figures 2A and 2B). Next, tendon stumps are isolated and held within the surgical field using hypodermic needles while the ankle and first MP joint are held in maximal dorsiflexion, and the nonviable tissue is debrided (Figures 2C and 2D). Once debridement was completed, a braided absorbable suture was placed in a continuous locking loop configuration in both the proximal and distal stumps to bridge the resulting tendon gap (Figures 3A and 3B). The harvested semitendinosus tendon autograft is prepared in a triple-bundle fashion to increase the maximal load of graft failure. The prepared graft is then used to reconstruct the EHL using a Pulvertaft technique for fixation into the proximal and distal tendon stumps (Figures 3C and 3D).

Post-Operative Protocol

Two studies used a short leg splint for postoperative immobilization^(7,24). In addition to the splint, Park et al.⁽²⁴⁾ used a hook over the nail of the hallux, which was attached to a rubber string fixed to the upper portion of the ankle to allow passive extension and limit tension across the reconstruction. Tuncer et al.⁽⁷⁾ immobilized the patient in a neutral position in a short leg splint with the ankle and toes. Kwapisz et al.⁽¹⁷⁾ used a short leg cast for immobilization with plantar support beneath the hallux. Lohrer and Nauck⁽³⁰⁾ also used a short leg cast fitted with plantar support beneath the hallux but also

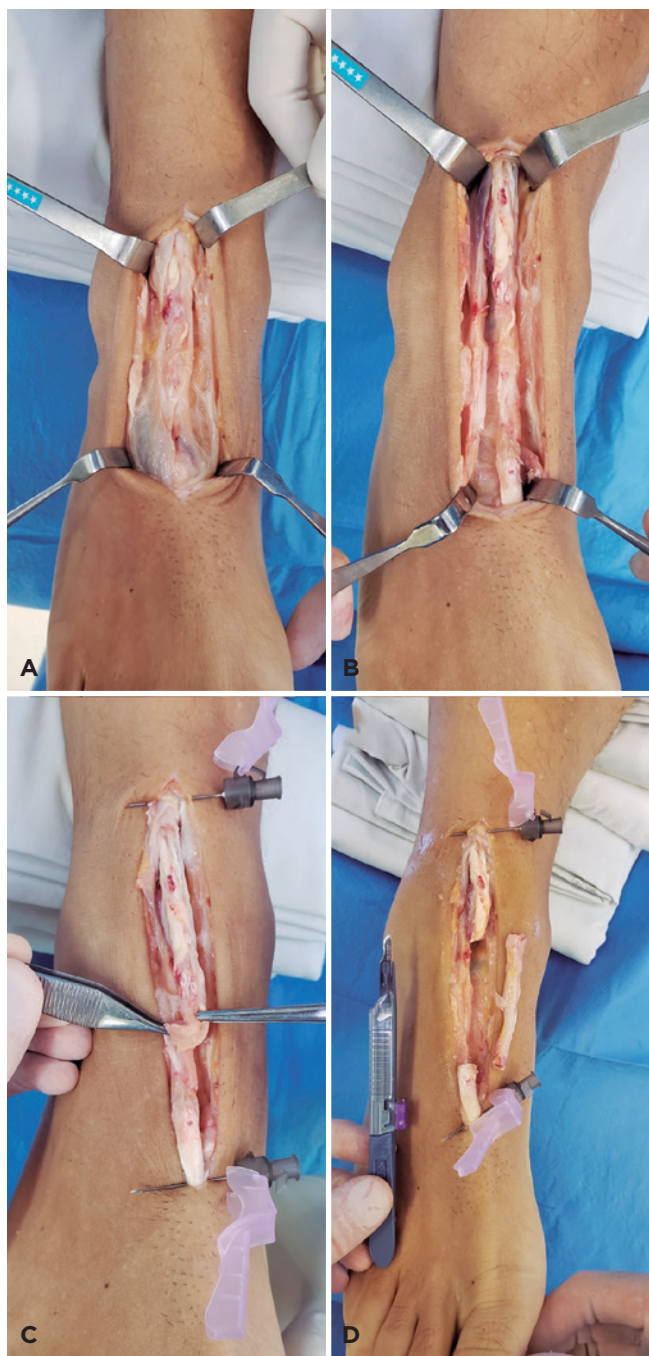


Figure 2. (A) Incision on the anterior ankle and dorsal aspect of the foot showing the diseased extensor hallucis longus (EHL). (B) Further exposure of the EHL tendon to identify the extent of pathology. (C) Viable tendon is identified proximally and distally and pinned in place using hypodermic needles with the ankle and first metatarsophalangeal joint in maximal dorsiflexion. The viable tendon is held in maximum tension, which also demonstrates the redundancy and poor quality of the chronic EHL tendon injury. (D) Nonviable tissue is debrided and the tendon stumps are seen with the resulting tendon gap.

used a hallux suspension sling and temporary Kirschner wire fixed across the hallux IP joint to maintain a dorsiflexed position.

Park et al.⁽²⁴⁾ allowed for passive extension and active flexion of the hallux within the splint during the first six weeks, then transitioned to active extension and flexion exercises

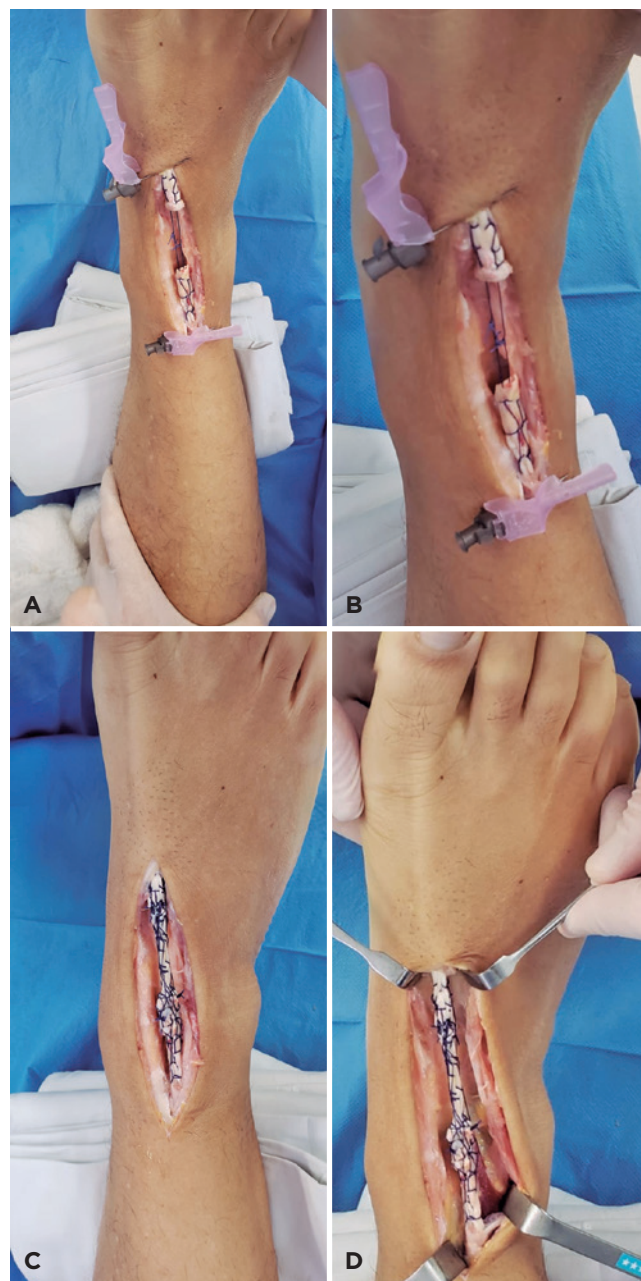

Figure 3. (A and B) Suture bridge between the proximal and distal stumps creating a pathway to put the autograft. (C and D) Fixation of the autograft in the tendon defect and final reconstruction.

out of the splint. Kwapisz et al.⁽¹⁷⁾ transitioned patients out of the cast into a boot with plantar support postoperatively for six weeks while remaining non-weight bearing. Passive ROM was initiated at three weeks. Active ROM and free ambulation were allowed starting in the seventh week. Tuncer et al.⁽⁷⁾ also allowed for passive ROM at three weeks in a removable splint and transitioned to active extension at 12 weeks postoperatively. Lohrer and Nauck⁽³⁰⁾ restricted weight-bearing for seven weeks, and the patient was transitioned to a walking boot with a 30-degree plantar wedge for the hallux. The wedge was weaned and removed at 14 weeks postoperatively. A night splint was utilized until five months, jogging was allowed at seven months, and release to full sports was achieved at nine months postoperatively.

Follow-up and outcomes

Park et al.⁽²⁴⁾ reported the shortest follow-up period of six months. The patient was doing well, with no discomfort during activities. Examination revealed normal ROM and a slight decrease in extension strength compared to the contralateral side.

Kwapisz et al.⁽¹⁷⁾ reported eight months of follow-up where the patient had full function without pain. Examination revealed minimal limitation in extension strength and five degrees of limited extension at the MP joint compared to ROM of the contralateral side. In addition, a dynamic ultrasound was obtained that showed smooth gliding of the reconstructed EHL tendon, and pedobarography revealed symmetric pressure distributions.

Lohrer and Nauck⁽³⁰⁾ reported 19 months of follow-up where the patient had postoperative improvement in Foot Function Index and American Orthopedic Foot and Ankle Society Hallux metatarsophalangeal-interphalangeal joint scores when compared to preoperative state. Examination demonstrated full strength and five degrees of limited plantar flexion.

Tuncer et al.⁽⁷⁾ reported the absence of any symptoms at one year of follow-up, but no postoperative examination was reported.

Discussion

While there appears to be a consensus regarding treating acute EHL tendon rupture with direct primary repair, there is limited evidence regarding the best method for the treatment of nonrepairable EHL tendon injuries⁽⁹⁻¹¹⁾. The current study performed a systematic literature review and presented four cases of EHL tendon reconstruction using a semitendinosus autograft. All patients are reported to have satisfactory outcome with no complications. However, there may be a minimal decrease in hallux extension strength or a decrease in overall ROM of approximately five degrees^(17,24,30). These findings may not be clinically relevant as each patient reported no symptoms or limitations.

Indications for pursuing an EHL reconstruction have not been established. When possible, direct end-to-end primary

repair of an acute EHL tendon rupture yields satisfactory results^(3,12-15). However, chronic rupture of greater than six weeks may result in tendon retraction and scar tissue formation^(9,18). In addition, patients with antecedent symptoms before rupture or previous failed primary repair may require extensive tendon debridement during the surgical intervention^(7,17,25,29,30). These historical factors may indicate an injury resulting in a large tendon gap that cannot be directly repaired. Clinical examination of an EHL tendon rupture will often demonstrate a lack of extension at the IP joint of the hallux with an associated flexion deformity and normal passive ROM. Plain radiographs should be obtained to exclude the possibility of an osseous avulsion injury. Further evaluation with advanced imaging, such as ultrasound or MRI can be used to confirm the rupture, evaluate for concomitant injuries, define the size of the tendon gap, and evaluate the quality of the tissue that remains^(7,17,24).

When indicated, an HT autograft for EHL reconstruction appears to be a viable treatment option. The major disadvantage of using an autograft for tendon reconstruction is donor site morbidity. Cody et al.⁽²⁸⁾ demonstrated minimal donor site morbidity when using HT autograft for various foot and ankle reconstructive procedures. Also, many autograft choices are available and have been described for EHL reconstruction, including the EDL^(3,25), EHB⁽²⁰⁾, extensor hallucis capsularis⁽²²⁾, split peroneal longus⁽¹⁸⁾, and palmaris tendons⁽¹²⁾. It is unknown what the best choice for EHL reconstruction is, but some argue that the semitendinosus autograft better matches the caliber of the EHL tendon and provides substantial length to reconstruct large defects^(7,17,24).

In addition to autograft EHL reconstruction, the allograft is another treatment option. EHL reconstruction using a tensor fascia lata allograft in combination with IP joint arthrodesis has been reported and resulted in weakness with minimal active extension of the hallux at ten months⁽²⁶⁾. The major advantages of allograft reconstruction are the ability to avoid donor site morbidity and reduce surgical times. The possible disadvantages of allograft include limited graft availability, increased costs, immunologic reaction to the graft, sterilization process affecting graft integrity, and risk of disease transmission⁽³¹⁻³⁴⁾.

If tendon reconstruction is not desired or unable to be performed, a tendon transfer or side-to-side tenodesis to the neighboring EDL tendon has been described for treating nonrepairable EHL injuries^(6,19,21,23). Tendon transfers most commonly use the EDL tendon^(19,23), but a transfer of the peroneus tertius has also been reported⁽⁴⁾. These procedures can be used routinely but may be particularly useful in scenarios where the proximal tendon stump cannot be identified for reconstruction. In addition, some small tendon defects may be amenable to lengthening the healthy EHL tendon stump to bridge the defect for repair⁽³⁵⁾, similar to techniques described for tibialis anterior ruptures⁽³⁶⁾. However, this repair may require augmentation with additional material, such as an acellular dermal scaffold⁽²⁷⁾. Lastly, IP joint arthrodesis may have a role in treating nonrepairable EHL injuries, but there is a lack of evidence regarding indications and outcomes of this procedure for nonrepairable EHL injuries^(17,26,29,30).

Regarding tendon fixation strategies, it is important to distinguish the need for a direct tendon repair versus a tendon reconstruction procedure. A direct tendon repair is often performed as an end-to-end repair as there is minimal tendon retraction resulting in acceptable tension at the repair site; however, increased strength is often needed when performing a tendon reconstruction with a graft such as side-to-side or Pulvertaft weave techniques, which allows increased suture fixation between the tendons⁽³⁷⁾. However, there is concern that an increased suture can compromise the vascular supply to the tendon and limit healing⁽²⁵⁾. Gabuza et al. compared the Pulvertaft weave to the side-to-side technique and found that the weave technique has greater resistance, which increases with the number of weaves⁽³⁸⁾. Conversely, other investigations have found no difference between these two techniques, while others have demonstrated greater repair strength with the side-to-side method. Wagner et al.⁽³⁹⁾ analyzed the strength of various side-to-side tenorrhaphy configurations using porcine flexor digitorum longus tendons and found a significantly lower failure load with a vertical mattress configuration compared to a running locked, eight simple, and pulley suture configurations. While the Pulvertaft weave is our preferred method, a side-to-side repair is another viable option.


The decision between using a tendon transfer, tendon tenodesis, reconstruction with autograft, or reconstruction with allograft is controversial. However, if tendon reconstruction is performed, the postoperative protocol and rehabilitation are critical for optimization of outcomes. Initial use of plantar support to prevent flexion of the hallux and limit tension on the reconstruction is recommended. If immobilization is prolonged, formation of adhesions and scar tissue may develop. It results in limited tendon excursion, decreased ROM,

and possible need for tenolysis. To combat adhesion and scar formation, rehabilitation principles from the upper extremity have been adopted, including early passive ROM⁽⁴⁰⁾. The use of a dynamic splint for the hallux following EHL tendon repair or reconstruction to provide an early passive extension to prevent scarring and adhesions has been described^(15,24).

The main limitation of the present study is the lack of data available on this clinical topic. Only four case reports could be obtained for evaluating EHL reconstruction using an HT autograft. The differences in preoperative evaluation, surgical technique, postoperative rehabilitation, and reporting of outcomes created a heterogeneous sample of patients making it difficult to evaluate these reports collectively. In addition, there are no comparison studies evaluating outcomes and complications between the available procedures for a non-repairable EHL injury. This limits our ability to make recommendations regarding indications for the various treatment options or to assess treatment superiority. The major strength of the study is the consolidation of the available case reports regarding EHL reconstruction using HT autograft to evaluate the efficacy of this treatment modality.

Conclusion

There is limited evidence to guide the treatment of non-repairable EHL tendon ruptures. A systematic review was performed to evaluate the use of HT autograft for EHL reconstruction. Four cases of EHL tendon reconstruction using a semitendinosus autograft were reviewed, and it appears to be a viable treatment with satisfactory outcomes and no complications reported. Further investigation is needed to determine the indications and efficacy of the various treatment modalities for non-repairable EHL injuries.

Author's contributions: Each author contributed individually and significantly to the development of this article: DLR* (<https://orcid.org/0000-0003-0183-8641>) Conceived and planned the activities that led to the study, data collection, statistical analysis, wrote the article; ESH* (<https://orcid.org/0000-0002-6261-3617>) Conceived and planned the activities that led to the study, data collection, statistical analysis, wrote the article; GB* (<https://orcid.org/0000-0001-5273-4303>) Conceived and planned the activities that led to the study, data collection, statistical analysis; DDB* (<https://orcid.org/0000-0002-7599-4244>) Participated in review process. All authors read and approved the final manuscript. *ORCID (Open Researcher and Contributor ID) 

References

- Lezak B, Summers S. Anatomy, Bony Pelvis and Lower Limb, Extensor Hallucis Longus Muscle. [Updated 2021 Oct 7]. In: StatPearls [Internet]. Treasure Island (FL): StatPearls Publishing; 2022 Jan-. Available from: <https://www.ncbi.nlm.nih.gov/books/NBK539875/>
- Anzel SH, Covey KW, Weiner AD, Lipscomb PR. Disruption of muscles and tendons; an analysis of 1, 014 cases. *Surgery*. 1959;45(3):406-14.
- Wong JC, Daniel JN, Raikin SM. Repair of acute extensor hallucis longus tendon injuries: a retrospective review. *Foot Ankle Spec*. 2014;7(1):45-51.
- Menz P, Nettle WJ. Closed rupture of the musculotendinous junction of extensor hallucis longus. *Injury*. 1989;20(6):378-81.
- Tadros AM, Al-Shaeel RA. Closed traumatic rupture of the extensor hallucis longus muscle. *J Foot Ankle Surg*. 2013;52(2):212-4.
- Fadel GE, Alipour F. Rupture of the extensor hallucis longus tendon caused by talar neck osteophyte. *Foot Ankle Surg*. 2008;14(2):100-2.
- Tuncer S, Aksu N, Isiklar U. Delayed rupture of the extensor hallucis longus and extensor digitorum communis tendons after breaching the anterior capsule with a radiofrequency probe during ankle arthroscopy: a case report. *J Foot Ankle Surg*. 2010;49(5):490.e1-3.

8. Lee KT, Choi YS, Lee YK, Lee JP, Young KW, Park SY. Extensor hallucis longus tendon injury in taekwondo athletes. *Phys Ther Sport.* 2009;10(3):101-4.
9. Kass JC, Palumbo F, Mehl S, Camarinos N. Extensor hallucis longus tendon injury: an in-depth analysis and treatment protocol. *J Foot Ankle Surg.* 1997;36(1):24-7.
10. Scaduto AA, Cracchiolo A 3rd. Lacerations and ruptures of the flexor and extensor hallucis longus tendons. *Foot Ankle Clin.* 2000;5(3):725-36.
11. Thordarson DB, Shean CJ. Nerve and tendon lacerations about the foot and ankle. *J Am Acad Orthop Surg.* 2005;13(3):186-96.
12. Al-Qattan MM. Surgical treatment and results in 17 cases of open lacerations of the extensor hallucis longus tendon. *J Plast Reconstr Aesthet Surg.* 2007;60(4):360-7.
13. Mowlavi A, Schall J, Wilhelmi BJ. Extensor hallucis longus tenorrhaphy by using the Massachusetts General Hospital repair. *J Foot Ankle Surg.* 2004;43(6):412-8.
14. Pedrazzini A, Valenti PG, Bertoni N, Pedrabissi B, Simo HY, Bisaschi R, et al. Traumatic extensor tendons injuries of the foot in childhood: a case report. *Acta Biomed.* 2019;90(12-S):202-6.
15. Skoff H. Dynamic splinting after extensor hallucis longus tendon repair. *Acase report.* *Phys Ther.* 1988;68(1):75-6.
16. Jaffe D. Restoration of Extension of the Great Toe After an Untreated, Retracted Extensor Hallucis Longus Rupture: A Case Report. *J Bone Joint Surg Am.* 2019;94(4):e0348.
17. Kwapisz S, Szałaj T, Boszczyk A, Rammelt S. Reconstruction of subcutaneous chronic rupture of extensor hallucis longus tendon with semitendinosus autograft. *Fuß Sprunggelenk.* 2017;15(2):120-125.
18. So E, Black TE, Mehl B. Split Peroneus Longus Free Tendon Autograft Transplantation for the Treatment of Neglected Extensor Hallucis Longus Tendon Laceration: A Case Report. *J Foot Ankle Surg.* 2018;57(1):210-14.
19. Bastías GF, Cuchacovich N, Schiff A, Carcuro G, Pellegrini MJ. Technique tip: EDL-to-EHL double loop transfer for extensor hallucis longus reconstruction. *Foot Ankle Surg.* 2019;25(3):272-7.
20. Berens TA. Autogenous graft repair of an extensor hallucis longus laceration. *J Foot Surg.* 1990;29(2):179-82.
21. Chun DI, Lee JH, Cho J. Rupture of the Extensor Hallucis Longus Muscle Secondary to Repetitive Overuse in a Taekwondo Athlete: A Case Report. *J Am Podiatr Med Assoc.* 2017;107(5):446-9.
22. Kurashige T. Chronic extensor hallucis longus tendon rupture treated with double-bundle autograft of extensor hallucis capsularis: A case report. *SAGE Open Med Case Rep.* 2019;7:2050313X19841962.
23. Leung YF, Ip SP, Chung OM. A new method of functional tendon transfer for the dysfunction of extensor hallucis longus. *Foot Ankle Int.* 2002;23(12):1124-5.
24. Park HG, Lee BK, Sim JA. Autogenous graft repair using semitendinous tendon for a chronic multifocal rupture of the extensor hallucis longus tendon: a case report. *Foot Ankle Int.* 2003;24(6):506-8.
25. Tuennermann L, Jordan MC, Paul MM, Jansen H, Meffert RH, Hoelscher-Doht S. Local Autograft and Strong Pulvertaft Fixation Technique for Reconstruction of a Rupture of the Extensor Hallucis Longus Tendon: A Case Report. *J Foot Ankle Surg.* 2019;58(6):1276-80.
26. Zielaskowski LA, Pontious J. Extensor hallucis longus tendon rupture repair using a fascia lata allograft. *J Am Podiatr Med Assoc.* 2002;92(8):467-70.
27. Joseph RM, Barhorst J. Surgical reconstruction and mobilization therapy for a retracted extensor hallucis longus laceration and tendon defect repaired by split extensor hallucis longus tendon lengthening and dermal scaffold augmentation. *J Foot Ankle Surg.* 2012;51(4):509-16.
28. Cody EA, Karnovsky SC, DeSandis B, Tychanski P, Papon A, Deland JT, et al. Hamstring Autograft for Foot and Ankle Applications. *Foot Ankle Int.* 2018;39(2):189-95.
29. Smith B, Coughlin M. Reconstruction of a chronic extensor hallucis longus tendon laceration with a gracilis tendon autograft. *Orthopedics.* 2008;31(10):orthosupersite.com/view.asp?rID=31525.
30. Lohrer H, Nauck T. Subcutaneous extensor hallucis longus tendon rupture: case report and literature review. *Foot Ankle Int.* 2012;33(10):905-11.
31. Strickland SM, MacGillivray JD, Warren RF. Anterior cruciate ligament reconstruction with allograft tendons. *Orthop Clin North Am.* 2003;34(1):41-7.
32. Nagda SH, Altobelli GG, Bowdry KA, Brewster CE, Lombardo SJ. Cost analysis of outpatient anterior cruciate ligament reconstruction: autograft versus allograft. *Clin Orthop Relat Res.* 2010;468(5):1418-22.
33. Barrera Oro F, Sikka RS, Wolters B, Graver R, Boyd JL, Nelson B, et al. Autograft versus allograft: an economic cost comparison of anterior cruciate ligament reconstruction. *Arthroscopy.* 2011;27(9):1219-25.
34. Xu X, Hu M, Liu J, Zhu Y, Wang B. Minimally invasive reconstruction of the lateral ankle ligaments using semitendinosus autograft or tendon allograft. *Foot Ankle Int.* 2014;35(10):1015-21.
35. Coughlin MJ. Hallux valgus in men: effect of the distal metatarsal articular angle on hallux valgus correction. *Foot Ankle Int.* 1997;18(8):463-70.
36. Chen J, Kadakia R, Akoh CC, Schweitzer KM Jr. Management of Anterior Tibialis Tendon Ruptures. *J Am Acad Orthop Surg.* 2021;29(16):691-701.
37. Fuchs SP, Walbeehm ET, Hovius SE. Biomechanical evaluation of the Pulvertaft versus the 'wrap around' tendon suture technique. *J Hand Surg Eur Vol.* 2011;36(6):461-6.
38. Gabuzda GM, Lovallo JL, Nowak MD. Tensile strength of the end-weave flexor tendon repair. An in vitro biomechanical study. *J Hand Surg Br.* 1994;19(3):397-400.
39. Wagner E, Ortiz C, Wagner P, Guzman R, Ahumada X, Maffulli N. Biomechanical evaluation of various suture configurations in side-to-side tenorrhaphy. *J Bone Joint Surg Am.* 2014;96(3):232-6.
40. Coady-Fariborzian L, Mueller B. Application of Hand Therapy Extensor Tendon Protocol to Toe Extensor Tendon Rehabilitation. *Fed Pract.* 2020;37(1):33-7.