

Systematic Review

Minimally invasive surgery for pedal digital deformity: a systematic review

Steven Richard Edwards¹ , Madeleine Grace Murray² , Mark Francis Gilheany¹ 

1. Australasian College of Podiatric Surgeons, Melbourne, Victoria, Australia.

2. La Trobe University, Melbourne, Victoria, Australia.

Abstract

Objective: The interest and application of minimally invasive surgery (MIS) in treating lesser toe deformities have increased worldwide. The symptoms are often attributed to callosities and localized pressure. Conservative treatment may improve comfort, but its success largely depends on the level of deformity. When conservative treatment fails, surgery may be indicated. This study explores the available evidence and reviews in the literature seeking to examine the efficacy of MIS in lesser toe pathology.

Methods: A systematic review was performed, and the search included the following databases: Cochrane Library, CINAHL, MEDLINE®, PUBMED, Science Direct, and other relevant peer-reviewed sources between September 2019 and June 2022. In addition, a manual search was conducted in Australian, American, British, and European orthopedic and podiatric scientific data for relevant studies.

Results: The search for potentially eligible information for this systematic review yielded 92 unique studies. All studies identified were obtained and reviewed. An updated search was performed in July 2022, resulting in no additional studies that satisfied the inclusion criteria. After considering all potentially eligible studies, five (5.4%) met the inclusion criteria. One thousand one hundred eighty-six lesser toe procedures (500 patients) were included. The overwhelming majority of patients were female (80.5%). The patient's mean age was 56.9 (range 18-91) years, and the mean follow-up was 19.6 (range 6-33) months. All of the studies included early mobilization in the postoperative protocol.

Conclusion: There is a need for more research using a combination of validated patient-reported outcomes to evaluate the effectiveness of MIS procedures in treating lesser toe deformities alongside the development of validated and tested treatment algorithms to guide surgical decision-making.

Level of Evidence III; Therapeutic Studies; Systematic Review.

Keywords: Minimally invasive surgery; Hammer toe syndrome; Systematic review.

Introduction

The interest and application of minimally invasive foot surgery (MIS) continue to grow worldwide, yet the most appropriate surgical treatment for lesser toe deformities is controversial⁽¹⁻⁸⁾. MIS has been defined as surgery performed through small portals without direct visualization of anatomical structures. Its use has increased due to the belief that it reduces soft-tissue damage, smaller scars, shorter surgery time and hospital stay, lower postoperative pain, and reduces infection risk. However, there is limited evidence to support these assertions⁽⁹⁾.

The aim of lesser toe surgery is to correct the deformity and preserve the foot biomechanics. There is no consensus regarding the best surgical approach⁽⁹⁾. Surgeons have historically focused on anatomical structures and contractures to guide their decision-making⁽¹⁰⁾. The ambiguous definitions and treatment options for diagnosing and managing lesser toe deformities have been well documented and may further confound the confusion surrounding appropriate surgical approaches⁽¹¹⁾.

The symptoms of lesser toe deformities are often attributed to callosities and localized pressure⁽³⁾. Conservative treatment

Study performed at the Australasian College of Podiatric Surgeons, Victoria, Australia.

Correspondence: Steven R Edwards. 110 Bay Street Brighton, 2186, Victoria, Australia. **E-mail:** s6edwards@gmail.com. **Conflicts of interest:** none. **Source of funding:** none. **Date received:** July 31, 2022. **Date accepted:** September 25, 2022. **Online:** December 20, 2022.

How to cite this article: Edwards SR, Murray MG, Gilheany MF. Minimally invasive surgery for pedal digital deformity: a systematic review. *J Foot Ankle.* 2022;16(3):306-9.



may improve comfort, but its success depends on the level of deformity. Orthoses, special footwear, protective devices, and various injection techniques have been employed as non-operative management⁽¹²⁾. When conservative treatment fails, surgery may be indicated. The aim of this systematic review is to determine whether MIS approaches for the correction of lesser toe deformities provide a safe and reproducible approach.

Methods

A systematic review was performed, and the search included the following databases: Cochrane Library, CINAHL, MEDLINE®, PUBMED, Science Direct, and other relevant peer-reviewed sources between September 2019 and June 2022. In addition, a manual search was conducted in Australian, American, British, and European orthopedic and podiatric scientific data for relevant studies, including but not limited to the Journal of Foot & Ankle Research, the Journal of Foot & Ankle Surgery, the Journal of the American Podiatric Medical Association, the American Journal of Sports Medicine, the British Journal of Sports Medicine, Foot and Ankle International, the Journal of Bone and Joint Surgery, and International Orthopaedics.

The abstract of each study was assessed to ensure it met the inclusion criteria outlined in Table 1. The hierarchy of evidence was considered for this review; however, given the small number of studies concerning the treatment and informing MIS decision-making, narrative reviews were included despite their low standing due to the mention of surgical algorithms.

Given MIS for lesser toe deformities is a relatively modern field of practice, few filters and limitations were applied to ensure the largest pool of research articles. Boolean operators searched for specific terms and established associations between keywords. A PRISMA flow chart is outlined in Figure 1.

Results

The search for potentially eligible information for this systematic review yielded 92 unique studies. All studies identified were obtained and reviewed. An updated search was performed in July 2022, resulting in no additional studies that satisfied the inclusion criteria. After considering all potentially eligible studies, five (5.4%) met the inclusion criteria. One thousand one hundred eighty-six lesser toe procedures (500 patients) were included (Table 2). The overwhelming majority of patients were female (80.5%). The patient’s mean age was 56.9 (range 18-91) years, and the mean follow-up was 19.6 (range 6-33) months. All of the studies included early mobilization in the postoperative protocol.

Favorable postoperative results using MIS for lesser toe deformities were seen across all studies, irrespective of the postoperative outcome measures used. A prospective cohort study by Yassin et al.⁽¹³⁾ reported a postoperative Visual Analog Scale (VAS) score of 1.9 for MIS compared to 3.5 for open Kirschner wire (K-wire) fixation.

Table 1. The inclusion and exclusion criteria

Inclusion Criteria	Exclusion Criteria
Empirical research	Concomitant hallux valgus surgery
Minimally invasive techniques	Traditional open
- Lesser toe deformities	
- Toe and Deformity	
- Guidelines or Algorithms	
Research using patient-reported outcome measures	
Research completed between 2008-2021	
Studies examining MIS in patients with existing medical conditions	
Narrative reviews	

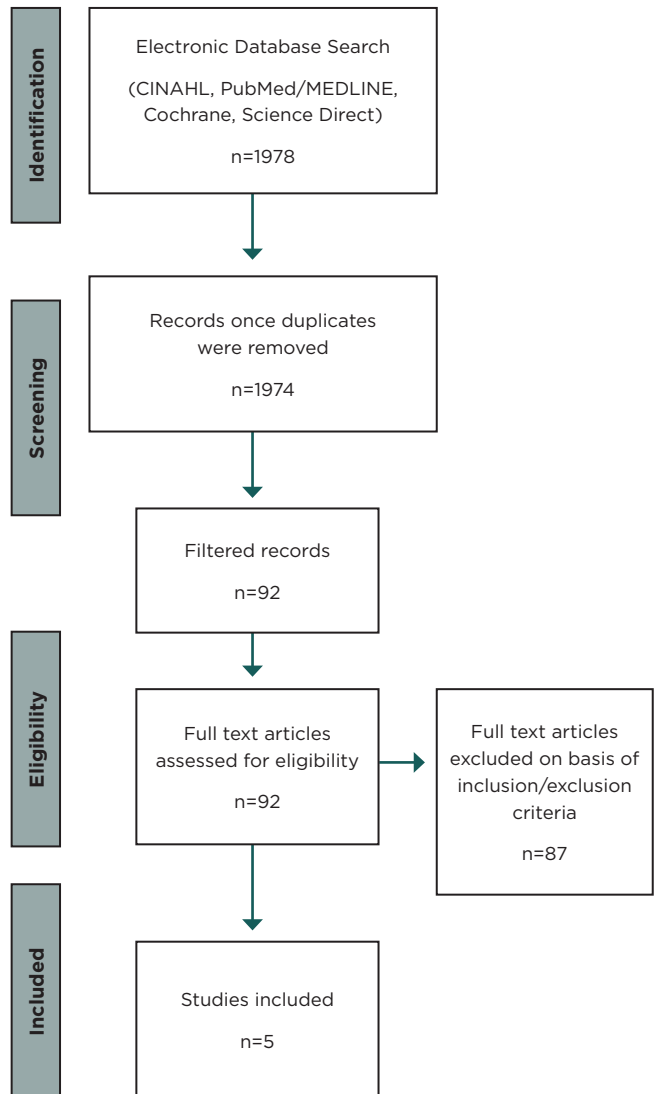


Figure 1. A PRISMA Flow chart of the included studies.

Table 2. Characteristics of the included studies

Author	Sample size	No. of procedures	Level of evidence	Surgical technique	Outcome measure	Follow-up
Nieto-Garcia et al. ⁽¹⁴⁾	223	723	III	Incomplete phalangeal osteotomies with or without tenotomies for lesser toe deformities alongside HAV surgery	AOFAS pre- and postoperatively	6, 12 months
Yassin et al. ⁽¹³⁾	87 (MIS), 265 (Open)	221 (MIS), 454 (Open)	III	Open K-wire fixation compared to percutaneous fixation	Radiographic assessment ASEPSIS score VAS	2, 3 months
Malhotra et al. ⁽¹¹⁾	N/A	N/A	V	N/A	N/A	N/A
Gilheany et al. ⁽⁹⁾	179	299	III	Simple deformity: MIS phalangeal osteotomies and/or ostectomy with/without lengthening/release to flexor/extensor tendons and capsular releases as required. Complex deformity: MIS reconstructive procedures of the MTPJ	An audit of complications using national benchmark indicators	12 months
Lui ⁽¹⁵⁾	11	13	III	MIS combined plantar plate tenodesis and EDB transfer	Radiological assessment	33 months

*HAV: Hallux abductus valgus; AOFAS: American Orthopaedic Foot & Ankle scale; MIS: Minimally invasive surgery; K-wire: Kirschner wire; ASEPSIS: Additional treatment, the presence of Serous discharge, Erythema, Purulent exudate, and Separation of the deep tissues, the Isolation of bacteria, and the duration of inpatient Stay; VAS: Visual Analog Scale; MTPJ: Metatarsophalangeal joint; EDB: Extensor digitorum brevis.

Four studies^(9,13-15) provide commentary on postoperative complications in their respective studies. Gilheany et al.⁽⁹⁾ reported low complication rates when performing MIS on pedal deformities through tenotomies, capsular releases, and osteotomies, with an observed infection rate of 0.53% and under correction of 0.67%. This complication rate contrasts with Nieto-Garcia et al.⁽¹⁴⁾, who found significantly higher postoperative complication rates when comparing the impact of tenotomies on the outcome of incomplete osteotomies. They reported a complication rate of 13.9% following an incomplete phalangeal osteotomy which increased to 38.6% when a tenotomy was performed concurrently. Yassin et al.⁽¹³⁾ found an increase in abnormal wound healing following MIS (20.7%) compared with open K-wire fixation (7.1%). However, a high number of co-morbid patients diagnosed with peripheral vascular disease in the MIS could impact the validity of their findings and explain the increase in postoperative complications.

Discussion

The aim of this systematic review was to evaluate the effectiveness of MIS procedures in treating lesser toe deformities. All studies included aimed to assess the effectiveness and management of MIS for lesser toe deformities; however, several different MIS techniques and lesser toe deformities were evaluated. Nieto-Garcia et al.⁽¹⁴⁾ and Yassin et al.⁽¹³⁾ approached this through comparative studies, with the latter comparing MIS to open surgery. Gilheany et al.⁽⁹⁾ assessed the surgical and medical complication rates associated with MIS for pedal toe deformities. Results were then compared against national benchmark indicators to determine whether MIS could prove advantageous or com-

parable to traditional open surgery. The final study by Lui⁽¹⁵⁾ examined the lateral and dorsal metatarsal phalangeal angles pre- and postoperatively through plain radiographs to assess the effectiveness of MIS in correcting cross-over toe deformity.

The study by Nieto-Garcia et al.⁽¹⁴⁾ was the largest, including 723 procedures performed on 223 patients. The study with the smallest sample size was conducted by Lui⁽¹⁵⁾ with 11 patients and 13 percutaneous procedures for lesser toe deformities. It is expected that a larger sample size would provide a better representation of a population, whereas small sample sizes may not capture the full range of results.

Gilheany et al.⁽⁹⁾ focused on postoperative complication rates where a longer-term follow-up may be considered advantageous when assessing deformity reoccurrence. This is in contrast to studies that compared pre- and postoperative pain scores where shorter follow-up periods focused on how pain levels change following the surgical intervention. Given the vast variation in postoperative follow-up periods recorded, direct comparisons between the studies included in this review may be invalid.


All studies included in this review concluded that their respective results favor using MIS in treating lesser toe deformities. However, it is difficult to draw direct conclusions due to the variance and limitations across the methods, data collection, and analysis.

Several complications were described across the studies identified, with all studies describing MIS as providing low complication rates. The variance was observed across all studies regarding the methodologies and patient-reported outcome measures used to identify adverse events. Nieto-Garcia et al.⁽¹⁴⁾ assessed the effectiveness of incomplete osteotomies using MIS techniques. Complications were higher

when the osteotomies were used alongside tenotomies, specifically those of delayed union, hypertrophic callous, and postoperative phalangeal fractures. Yassin et al.⁽¹³⁾ compared MIS osteotomies to traditional K-wire fixation. Adverse events were lower in the percutaneous group than those treated with traditional K-wire fixation.

Conclusion

There is a need for more research using a combination of validated patient-reported outcomes to evaluate the effectiveness of MIS procedures in treating lesser toe deformities alongside the development of validated and tested treatment algorithms to guide surgical decision-making.

Authors' contributions: Each author contributed individually and significantly to the development of this article: SRE *(<https://orcid.org/0000-0002-9866-0327>) Interpreted the results of the study, designed and wrote the manuscript, participated in the review process and approved the final version; MGM *(<https://orcid.org/0000-0001-9533-7797>) Conceived and planned the activities that led to the study, approved the final version; MFG *(<https://orcid.org/0000-0002-8179-7992>) Performed the surgeries, data collection and approved the final version. All authors read and approved the final manuscript. *ORCID (Open Researcher and Contributor ID) 

References

1. Fanous RN, Ridgers S, Sott AH. Minimally invasive arthrodesis of the first metatarsophalangeal joint for hallux rigidus. *Foot Ankle Surg.* 2014;20(3):170–3.
2. Van Enoo RE, Cane EM. Minimal incision surgery. A plastic technique or a cover-up? *Clin Podiatr Med Surg.* 1986;3(2):321–35.
3. Maffuli N, Easley M, editors. Minimally invasive surgery of the foot and ankle. London: Springer-Verlag; 2011.
4. Roukis TS, Schade VL. Minimum-incision metatarsal osteotomies. *Clin Podiatr Med Surg.* 2008;25(4):587–607.
5. Dhukaram V, Chapman AP, Upadhyay PK. Minimally invasive forefoot surgery: a cadaveric study. *Foot Ankle Int.* 2012;33(12):1139–44.
6. White DL. Minimal incision approach to osteotomies of the lesser metatarsals. For treatment of intractable keratosis, metatarsalgia, and tailor's bunions. *Clin Podiatr Med Surg.* 1991;8(1):25–39.
7. Legenstein R, Bonomo J, Huber W, Boesch P. Correction of tailor's bunions with the Boesch technique: a retrospective study. *Foot Ankle Int.* 2007;28(7):799–803.
8. de Prado M, Ripoll LP, Golano P. Minimally invasive foot surgery: surgical techniques, indications and anatomical basis. Barcelona, Spain: About Your Health Publishers; 2009.
9. Gilheany M, Baarini O, Samaras D. Minimally invasive surgery for pedal digital deformity: an audit of complications using national benchmark indicators. *J Foot Ankle Res.* 2015;8:17.
10. Schrier JC, Louwerens JW, Verheyen CC. Opinions on lesser toe deformities among Dutch orthopaedic departments. *Foot Ankle Int.* 2007;28(12):1265–70.
11. Malhotra K, Davda K, Singh D. The pathology and management of lesser toe deformities. *EFORT Open Rev.* 2017;1(11):409–19.
12. NHS Health Research Authority – Accessing Study Support and advice services. Available from: <http://www.hra.nhs.uk/resources/before-you-apply/is-it-research/>
13. Yassin M, Garti A, Heller E, Robinson D. Hammertoe correction with k-wire fixation compared with percutaneous correction. *Foot Ankle Spec.* 2017;10(5):421–7.
14. Nieto-García E, Ferrer-Torregrosa J, Ramírez-Andrés L, Nieto-González E, Martínez-Nova A, Barrios C. The impact of associated tenotomies on the outcome of incomplete phalangeal osteotomies for lesser toe deformities. *J Orthop Surg Res.* 2019;14(1):308.
15. Lui TH. Correction of crossover deformity of second toe by combined plantar plate tenodesis and extensor digitorum brevis transfer: a minimally invasive approach. *Arch Orthop Trauma Surg.* 2011;131(9):1247–52.