

Original Article

Foot and ankle offset in the setting of severe rotational foot and ankle deformities

Ryan Jasper¹ , Hannah Stebral¹ , Vineel Mallavarapu¹ , Grayson Talaski¹ , Eli Schmidt¹ , Aly Fayed¹ , Ki Chun Kim^{1,3} , Kepler Alencar Mendes de Carvalho¹ , Nacime Salomão Barbachan Mansur^{1,2} , César de César Netto¹ 

1. Department of Orthopedics and Rehabilitation, Carver College of Medicine, University of Iowa, Iowa City, IA, USA.

2. Department of Orthopedics and Traumatology, Paulista School of Medicine. Federal University of Sao Paulo, São Paulo, SP, Brazil.

3. Department of Orthopedic Surgery, Seoul Medical Center, Jungnang-gu, Seoul, South Korea.

Abstract

Objective: The goal of this paper was to evaluate the validity of foot and ankle offset (FAO) measurements in the setting of severe foot and ankle deformities.

Methods: This study included 57 feet (36 patients) that had a history of severe cavovarus deformity. Each participant received a weight-bearing computed tomography (WBCT) scan that was then used to measure FAO. This measurement was performed once using the traditional measurement technique and two additional times using a modified technique that allows for rotational correction of the images to align the talus.

Results: Traditional FAO (TFAO) and modified FAO (MFAO) were found to have a significant correlation with one another ($r(54)=0.92$, $p<0.001$). There was a high positive correlation between the variables of the two techniques ($r=0.92$) with the intraobserver reliabilities ($ICC=0.95$) for FAO measurements. The agreement between TFAO and Modified foot and ankle offset (MFAO) measurements was also considered excellent ($ICC=0.99$).

Conclusion: The MFAO method provides statistically similar FAO measurements compared to the TFAO method in this population. Thus, the TFAO method could potentially expand its patient population to provide surgeons with a reliable tool for assessing more severe deformities.

Level of Evidence IV; Retrospective Study.

Keywords: Ankle joint; Foot deformities; Tomography, x-ray computed; Weight-bearing.

Introduction

Foot and ankle offset (FAO) is a three-dimensional (3D) measurement for overall foot and ankle alignment assessment. It is characterized by the relation between the weight-bearing tripod of the foot and the center of the ankle joint⁽¹⁻³⁾. The most plantar voxel of the heads of the fifth and first meta-

tarsal and the calcaneal tuberosity make up the tripod of the foot, while the most proximal and central points of the talus represents the center of the ankle. Foot and ankle offset characterizes the normalized percentage of the shortest distance between the center of the ankle joint and a bisecting line of the foot tripod⁽¹⁾.

Study performed at the UIOWA Orthopedic Functional Imaging Research Laboratory (OFIRL). University of Iowa, Carver College of Medicine, Department of Orthopedics and Rehabilitation, Iowa City, IA, USA.

Correspondence: Ryan Jasper. Carver College of Medicine, Department of Orthopedics and Rehabilitation University of Iowa, 200, 52242-0000, Hawkins Dr. John Pappa/John Pavillion (JPP), Iowa City, IA, USA. **E-mail:** ryan-jasper@uiowa.edu. **Conflicts of interest:** César de César Netto: CurveBeam: Paid consultant; Stock or stock Options; Foot and Ankle International: Editorial or governing board; Editor in Chief Foot and Ankle Clinics; Nextremity: Paid consultant; Ossio: Paid consultant; Paragon 28: IP royalties; Paid consultant; Weightbearing CT; International Study Group: Board or committee member; Zimmer: Paid consultant. **Nacime Salomao Barbachan Mansur:** Brazilian Foot and Ankle Society: Board or committee member; American Orthopaedic Foot and Ankle Society: Board or committee member. **Source of funding:** none. **Date received:** December 9, 2022. **Date accepted:** December 11, 2022. **Online:** December 20, 2022.



How to cite this article: Jasper R, Stebral H, Mallavarapu V, Talaski G, Schmidt E, Fayed A, et al. Foot and ankle offset in the setting of severe rotational foot and ankle deformities. *J Foot Ankle.* 2022;16(3):215-21.

The FAO is clinically relevant due to its ability to produce an objective value portraying the foot alignment⁽³⁻⁵⁾. In addition, it represents a measurement of the offset between the body weight vector and the ground reaction force vector, thus making it a biomechanically relevant measurement. Foot and ankle offset has been found to be reliable in assessing preoperative deformity and postoperative correction in adult-acquired flatfoot deformity^(6,7). It has also been shown to be an effective way to discriminate clinically normal feet from varus and valgus hindfoot alignment with excellent interobserver and intraobserver reliability, 0.99 and 0.96, respectively^(2,8).

Patients were divided into three groups based on their foot and ankle alignment. Normal alignment was defined as an FAO of $2.3\% \pm 2.9\%$ ⁽²⁾. Negative values show varus alignment for FAO, $-11.6\% \pm 6.9\%$ (95% CI, $-13.9\% - 9.4\%$)⁽²⁾, demonstrating that the ankle joint is positioned laterally relative to the bisecting line of the foot tripod⁽⁹⁾. Valgus alignment was defined as having an FAO of $11.4\% \pm 5.7\%$ (95% CI, $9.6\% - 13.3\%$), demonstrating that the center of the ankle joint is located medial to the bisecting line of the center of the ankle joint⁽²⁾. While measurements in the varus and valgus alignment setting are reliable, FAO measurements' reliability has not been shown in the setting of severe foot and ankle deformities.

In cases with severe dysplasia and rotation of the talus, consistent and reliable measurements of the established anatomical landmarks might be challenging. The first and fifth metatarsals, the calcaneus, and mostly the talus may be difficult to identify if the axes of the semi-automatic software are not adjusted. Therefore, the objective of this study is to compare FAO measurements in patients with severe rotational deformities of the foot and ankle by using the traditional measurement method with a modified one consisting of an axis-based determination. We hypothesized that by adjusting to the use of the bimalleolar axis when identifying the center of the ankle voxel, FAO values would change in cases of severe foot and ankle deformities.

Methods

This is a retrospective comparative study performed at the Orthopedic Functional Imaging Laboratory (OFIRL), Carver College of Medicine, University of Iowa. The study obtained an Institutional Review Board approval (#202012422), complying with the Health Insurance Portability and Accountability Act (HIPAA) and the Declaration of Helsinki.

Design

Weight-bearing computed tomography (WBCT) scans of patients with a history of severe cavovarus performed between January 2015 and July 2020 were analyzed. Foot and ankle offset was measured three times per foot, once using the traditional measurement method and twice using a novel modified method. This can be visualized in the corresponding flow chart (Figure 1).

The three measurements were taken to assess the ability of the traditional measurement technique to identify the most central and proximal points of the talus and validate the intraobserver reliability and consistency of using the rotation method for measurement. These measurements were done using the semi-automatic TALAS™ instrument (CubeVue, CurveBeam®, Hatfield, PA, USA) measurement tool^(4,10).

Subjects

A total of 57 feet (36 patients) with a history of severe cavovarus were analyzed in this study. Inclusion criteria included patients over 18 years with a clinical and radiographic diagnosis of the deformity. Patients with metallic implants deterring visualization of the first and fifth rays and patients with isolated ankle WBCT acquisitions without the forefoot were not included in this study.

Weight-bearing computed tomography imaging

Weight-bearing computed tomography studies were performed with a cone-beam computed tomography extremity scanner (HiRise®, LLC, Warrington, PA, USA). Patients were instructed to place their feet aiming frontward, shoulder width apart from one another, distributing their body weight evenly between their lower limbs, and bearing weight in a physiological straight position.

Foot and ankle offset measurements

Foot and ankle offset measurements were performed using TALAS™. In all measurements, the 3D coordinates (X, Y, Z) of the calcaneal tuberosity, the head of the first metatarsal, and the head of the fifth metatarsal were manually selected on multiplanar reconstruction (MPR) views and used to represent the tripod of the foot⁽⁹⁾. For the one measurement per foot that was done using the traditional FAO (TFAO) technique, the most central and proximal points of the talus were identified using both sagittal and coronal views. In the coronal view, a distance line with a demarcated midpoint was placed on the medial and lateral end points of the talar dome. This was done to identify the most proximal point of the talar dome in the sagittal view, which was then manually selected and used to calculate the FAO (Figure 2).

The modified FAO (MFAO) measurement was done using the bimalleolar axis, and the foot and ankle tripod was marked using the same procedure described above. Before identifying the most central and proximal points of the talus, specific rotations of the axes were performed. First in the axial view, the talus was brought into focus where both the medial and lateral malleoli were visible (Figure 2). Then using the same view, the intersection point of the X and Y axes was placed in the middle of the talus. Next, rotation about the Z-axis was done to have the most medial point of the medial malleolus and the most lateral points of the lateral malleolus intersected by the X-axis. Then using the coronal view, the Y and Z axes were rotated about the X-axis so that the

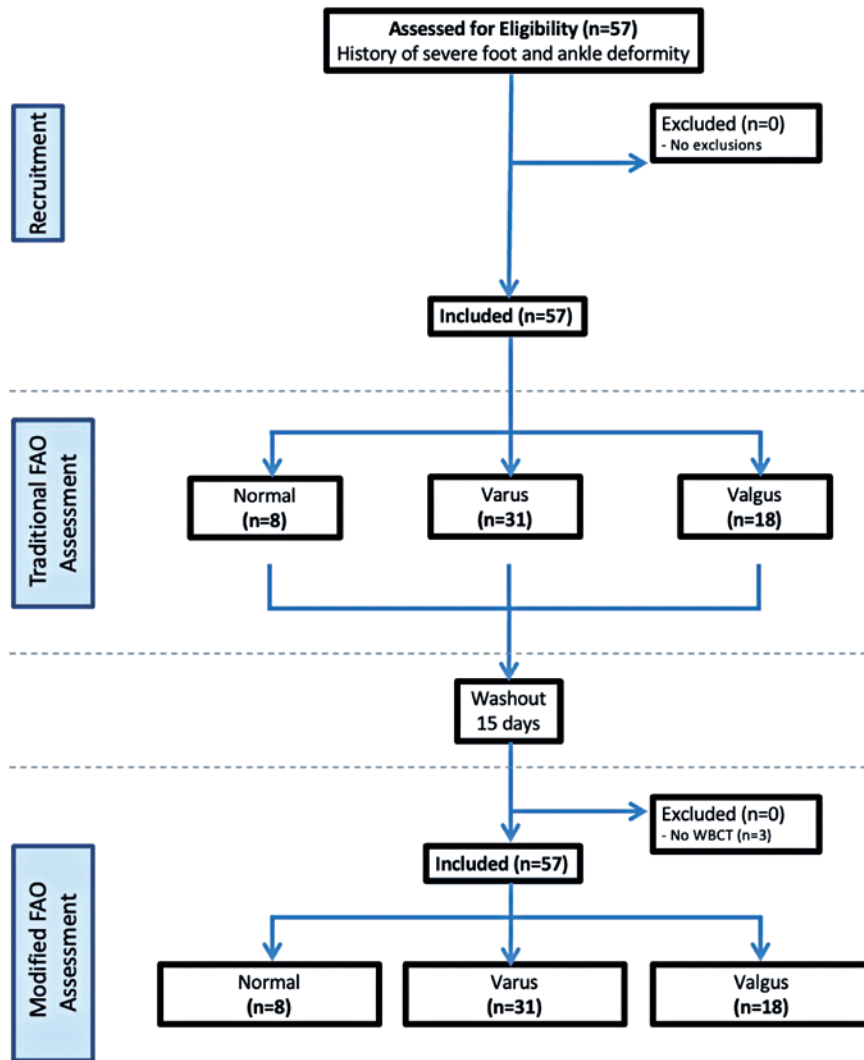


Figure 1. Flow chart depicting the steps taken during this study, including a 15-day washout period between the traditional and modified FAO measurements.

Z-axis would parallel the talar dome. After this, a midpoint line was placed across the talar dome in a similar process to that described for the standard technique. Next, the intersection points of the Y and Z axes, as seen in the coronal view, were placed at the midpoint marking of this line. Finally, using the sagittal view, the intersection of the X and Z axes was placed on the most central and most proximal points of the talus. This point was then selected, and its coordinates were used to calculate the FAO using the same semi-automatic technology as before (Figure 3). This measurement technique was repeated for every foot after a washout 15-day period to assess the modified method's intraobserver reliability.

Statistical Analysis

Intraobserver reliability was assessed by Intraclass Correlation Coefficient (ICC). Traditional and modified FAO mea-

surements were assessed for normality by the Shapiro-Wilk test. Inter-method agreement between techniques' measurements was assessed by Spearman's correlation (ρ). One-way ANOVA and Wilcoxon tests were used for comparison among groups. P-values under 0.05 were considered significant, and confidence intervals of 95% were presented. The analyses were performed by the software SPSS® V20 (IBM Corp., Armonk, New York, USA), R software (The R Foundation, Indianapolis, Indiana, USA), and Minitab® 16 (Minitab, LLC, State College, PA, USA).

Results

The intraobserver reliabilities (ICC=0.95) for FAO measurements were excellent. The agreement between TFAO and MFAO measurements was also considered excellent (ICC=0.99) (Table 1).

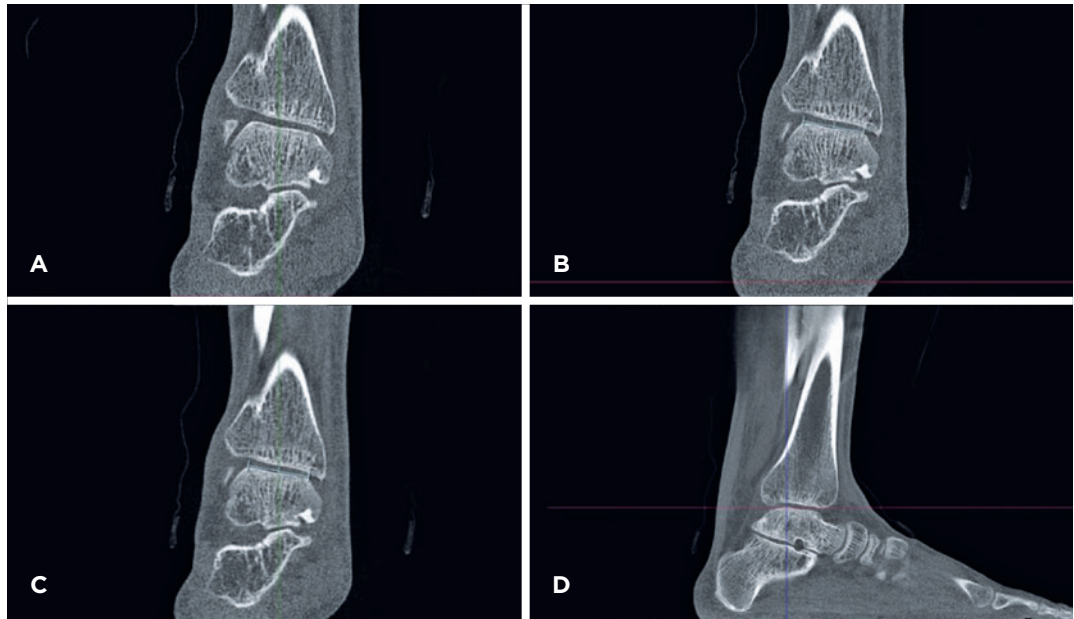


Figure 2. The traditional method of identifying the most central and proximal points of the talus for FAO is by sagittal and coronal planes. (A) In the coronal plane, the talus is clearly visualized, where a line with a midpoint marker is then placed across the dome of the talus in the same view (B) The Y-axis is then positioned at the midpoint of the line placed (C) Visualization of the most proximal and central points of the talus, which is identified by placing the X and Z axes intersection on that point (D) This along with the foot tripod coordinates is used to calculate the FAO.

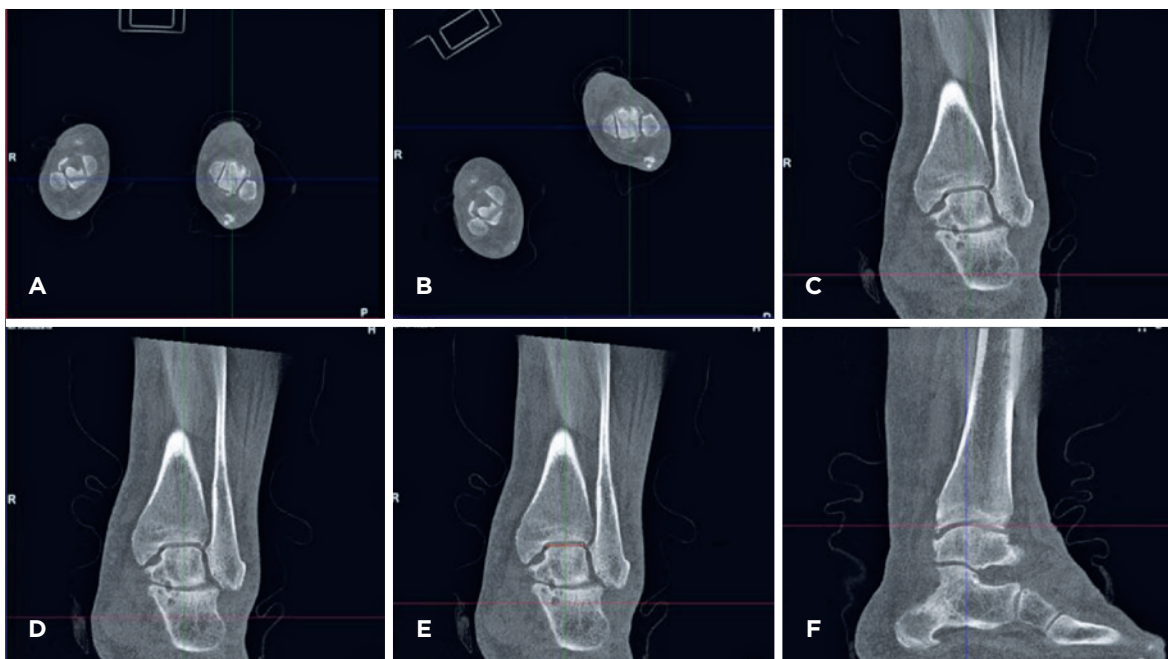


Figure 3. Using the bimalleolar axis and rotation to identify the most central and most proximal point of the talus. (A) Visualization of the medial and lateral malleoli in the axial view with the X and Y axes intersection point placed in the center of the talus. (B) Rotation of the X and Y axes about the Z-axis in the axial view such that the medial and lateral malleoli are intersected by the X-axis. (C) Visualization of the talus in the coronal plane, with the image then rotated about the X-axis such that the talar dome is parallel to the Z-axis with a midpoint line added across the plateau of the talus (D-E) Sagittal view after rotation with the intersection of the X and Z axes placed at the most central and proximal points of the talus.

Table 1. Intraobserver agreement and consistency of FAO (Traditional vs. Modified). Measurements assessed by ICC

	Intraobserver		p-value
	Agreement (95% CI)	Consistency (95% CI)	
Traditional FAO	0.957 (0.926-0.975)	0.956 (0.924-0.974)	< 0.001*
Modified FAO	0.96 (0.931-0.976)	0.959 (0.930-0.976)	< 0.001*

FAO: Foot and Ankle Offset. P-values are based on F tests inherent in the function ICC/R package IRR. *Statistical significance, p<0.05.

The mean TFAO was 2.37±4.65% (95% CI=1.16-3.59). Eight patients were found to have physiological normal hindfoot alignment (mean FAO of 3.67±0.55 95% CI, 3.31-4.03). Thirty-one patients had varus malalignment (mean FAO, -0.84; 95% CI, -1.92-0.25), and 18 had valgus malalignment (mean FAO, 6.74; 95% CI, 6.74-9.15).

The mean MFAO was 2.51±4.6 (95% CI=1.3-3.71). For the patients with physiological normal hindfoot alignment, the mean MFAO was 3.8±0.55 (95% CI, 3.43-4.16). For patients with varus malalignment, the mean MFAO was -0.75±3.18 (95% CI, -1.89-0.38), and for patients that had valgus malalignment, the mean MFAO was 7.58±2.49 (95% CI, 6.39-8.76) (Figure 4).

The mean MFAO values between the different alignment groups were significantly different (p<0.0001) (Figure 5). Significant differences were also found when comparing varus to valgus (p<0.001), varus to physiological (p=0.002), and valgus to physiological alignment (p=0.002).

Traditional FAO and MFAO were compared under three hindfoot alignment conditions (normal, valgus, and varus), and a t-test showed that the difference between TFAO normal-MFAO normal was not statistically significant, t(8)=-0.53, p=0.609. Also for TFAO cavus-MFAO cavus, t(28)=-0.15, p=0.884, and for TFAO valgus-MFAO valgus, t(14)=0.68, p=0.506 (Table 2).

A Spearman correlation was performed to test whether there was an association between TFAO and MFAO. The result of the Spearman correlation showed that there was a significant association between them, r(54)=0.92, p< 0.001 (Figure 6).

Discussion

Foot and ankle offset are a validated way to measure the 3D alignment of the foot and ankle in multiple foot and ankle conditions⁽¹⁾. The goal of this study was to identify if TFAO measurements are still effective when used in cases of severe deformity of the foot and ankle.

A high, positive correlation was found between the TFAO and MFAO measurements with excellent reliability. The study’s findings deny our primary hypothesis that the two measurement techniques would differ. Considering the results, we

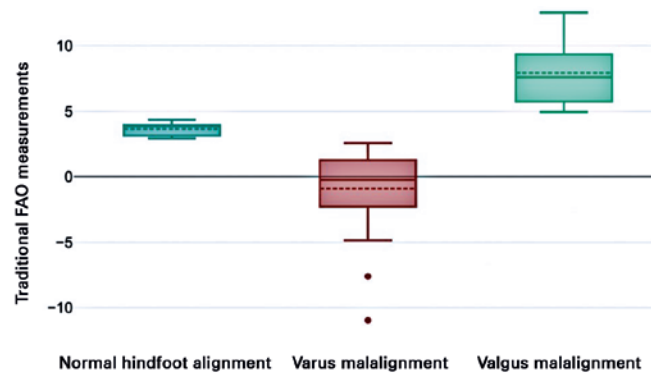


Figure 4. Mean values of traditional foot and ankle offset measurements (p<0.0001).

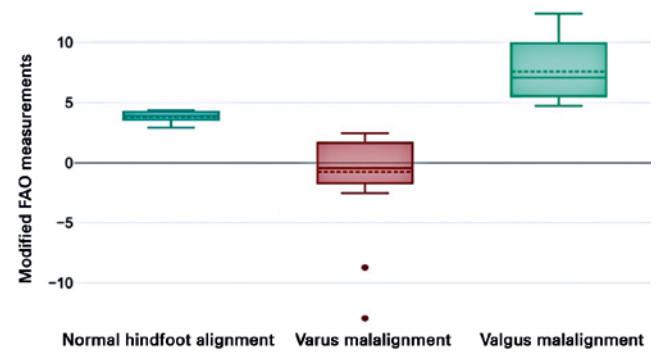


Figure 5. Mean values of modified foot and ankle offset measurements (p<0.0001).

Table 2. Foot and ankle offset in different hindfoot alignment

	t-test	DF	p-value
FAO normal - MFAO normal	-0.53	8	0.609
FAO cavus - MFAO cavus	-0.15	28	0.884
FAO valgus - MFAO valgus	0.68	14	0.506

FAO: Foot and ankle offset; MFAO: Modified foot and ankle offset; DF: P-values are based on t-tests inherent in the function ICC/ R package IRR. Statistical significance, p<0.05.

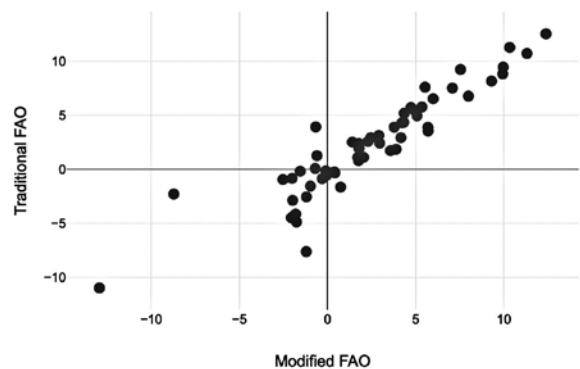


Figure 6. Spearman correlation, there is a high, positive correlation between the variables of traditional and modified foot and ankle offset measurements (p<0.001).

attest that the traditional method of measuring the FAO can assess severe rotational deformities.

The intraobserver reliability of both TFAO and MFAO measurement methods was excellent. This further supports the TFAO method's reliability and reproducibility, as previously indicated in the literature, and also shows how the novel MFAO method can similarly provide repeatable and consistent measures of FAO. Regarding the MFAO measurement method, this produced comparable results to the TFAO method, as there were also significant differences in mean FAO between normal hindfoot alignment and varus and valgus malalignment. These results indicate how the MFAO measurement method, like the TFAO, can produce an objective value portraying the alignment of the foot.


These results reject our previous hypothesis that adjusting the bimalleolar axis when identifying the center of the ankle voxel would change FAO values in cases of severe foot and ankle deformities. As the results indicate, the TFAO and MFAO methods produce significantly similar FAO values even in the setting of severe ankle deformities. Thus, TFAO measures show the ability to objectively portray disease progression in mild and severe forms of ankle deformities, despite the unique and severe physiological contortions of the foot and ankle in these patients. Therefore, the TFAO measurement method could potentially be used in these patients to provide a more detailed depiction of the misalignment in the foot and ankle, and physicians could more accurately treat these patients and potentially supply them with better outcomes.

The main findings of this study are subject to several limitations. The retrospective nature of the study could have

presented biases regarding the study's design and methodology. Another limitation is that this study did not utilize a control group. This information would have allowed information about how this modified method impacted FAO measurements of healthy ankles. It is also important to note the lack of previous research on FAO measurement in this specific population with severe foot and ankle deformities. While the current literature illustrates the reliability of this TFAO measurement tool for assessing the preoperative deformity state in progressive collapsing foot deformity patients, there is very little research depicting this in our study's population of interest. Lastly, this study does not measure the scope in which these MFAO measurements directly correlate to patient outcomes. Thus, there is a need for further investigation in this area.

Conclusion

We present a novel method of performing a 3D biometric WBCT measurement of FAO in a population with severe foot and ankle deformities. This modified FAO method provides statistically similar FAO measurements compared to the traditional FAO method in our specified population. Thus, the traditional FAO method could potentially expand its patient population to provide surgeons with a reliable tool for assessing more severe deformities. Further research, such as a prospective comparative study, would be beneficial to identify the correlation of these FAO measurement methods in severe foot and ankle deformity patients with their postoperative clinical and functional outcomes.

Authors' contributions: Each author contributed individually and significantly to the development of this article: RJ *(<https://orcid.org/0000-0003-3448-1300>) Conceived and planned the activities that led to the study, interpreted the results of the study, participated in the review process and approved the final version; HS *(<https://orcid.org/0000-0003-2664-0762>), VM *(<https://orcid.org/0000-0002-8612-5941>), GT *(<https://orcid.org/0000-0003-3448-1300>), ES *(<https://orcid.org/0000-0002-6922-5238>), AF *(<https://orcid.org/0000-0003-3448-1300>), KCK (<https://orcid.org/0000-0002-3731-8448>), Data collection and interpreted the results of the study; KAMC *(<https://orcid.org/0000-0003-1082-6490>) Interpreted the results of the study, participated in the review process and approved the final version; NSBM *(<https://orcid.org/0000-0003-1067-727X>) Interpreted the results of the study and approved the final version; CCN *(<https://orcid.org/0000-0001-6037-0685>) Interpreted the results of the study and approved the final version. All authors read and approved the final manuscript. *ORCID (Open Researcher and Contributor ID) 

References

1. de Cesar Netto C, Bang K, Mansur NS, Garfinkel JH, Bernasconi A, Lintz F, et al. Multiplanar Semiautomatic Assessment of Foot and Ankle Offset in Adult Acquired Flatfoot Deformity. *Foot Ankle Int* 2020;41(7):839-48.
2. Lintz F, Welck M, Bernasconi A, Thornton J, Cullen NP, Singh D, et al. 3D Biometrics for Hindfoot Alignment Using Weightbearing CT. *Foot Ankle Int*. 2017;38(6):684-9.
3. Barbachan Mansur NS, Lalevee M, Maly C, Dibbern K, Lee HY, Godoy-Santos AL, et al. Association Between Middle Facet Subluxation and Foot and Ankle Offset in Progressive Collapsing Foot Deformity. *Foot Ankle Int*. 2022;43(1):96-100.
4. Lintz F, Mast J, Bernasconi A, Mehdi N, de Cesar Netto C, Fernando C. International Weight-Bearing CT Society, Buedts K. 3D, Weightbearing Topographical Study of Periprosthetic Cysts and Alignment in Total Ankle Replacement. *Foot Ankle Int*. 2020;41(1):1-9.
5. Haldar A, Bernasconi A, Junaid SE, Lee KHB, Welck M, Saifuddin A. 3D imaging for hindfoot alignment assessment: a comparative study between non-weight-bearing MRI and weight-bearing CT. *Skeletal Radiol*. 2021;50(1):179-88.
6. Day J, de Cesar Netto C, Nishikawa DRC, Garfinkel J, Roney A, J O'Malley M, et al. Three-dimensional biometric weightbearing ct

evaluation of the operative treatment of adult-acquired flatfoot deformity. *Foot Ankle Int.* 2020;41(8):930-6.

7. Lintz F, Bernasconi A, Baschet L, Fernando C, Mehdi N, De Cesar Netto C. Relationship between chronic lateral ankle instability and hindfoot varus using weight-bearing cone beam computed tomography. *Foot Ankle Int.* 2019;40(10):1175-81.
8. Zhang JZ, Lintz F, Bernasconi A, Zhang S. 3D Biometrics for hindfoot alignment using weightbearing computed tomography. *Foot Ankle Int.* 2019;40(6):720-6.
9. de Cesar Netto C, Day J, Godoy-Santos AL, Roney A, Barbachan Mansur NS, Lintz F, et al. The use of three-dimensional biometric Foot and Ankle Offset to predict additional realignment procedures in total ankle replacement. *Foot Ankle Surg.* 2022;28(7):1029-34.
10. Bernasconi A, Cesar C, Roberts L, Lintz F, Godoy-Santos AL, O'Malley MJ. Foot alignment in symptomatic national football league (nfl) athletes: a weightbearing ct analysis. *Acta Ortop Bras.* 2021;29(3):118-23.
11. Lintz F, Ricard C, Mehdi N, Laborde J, Bernasconi A, Richardi G, Sans N. Hindfoot alignment assessment by the foot-ankle offset: a diagnostic study. *Arch Orthop Trauma Surg.* 2022.