

Case Report

Septic arthritis of the ankle due to *Citrobacter koseri*: a case report

Alexandre Loureiro de Castro¹ , Raquel Diana de Lima Cunha¹ , Tânia Raquel Alegre Veigas¹ ,
Eduardo Miguel de Almeida Moreira Pinto¹ , Pedro Manuel Atilano Carvalho^{1,2} , João Pedro Lopes Teixeira^{1,2} 

1. Centro Hospitalar de Entre o Douro e Vouga, Department of Orthopaedic and Traumatology, Santa Maria da Feira, Portugal.
2. Hospital da Luz Arrábida, Porto, Portugal.

Abstract

Septic arthritis of the ankle after arthroscopy is a rare but serious condition. Specifically, to the best of our knowledge, there have been no reports of septic arthritis of the ankle caused by *Citrobacter koseri*. An otherwise healthy 42-year-old male patient presented to our outpatient clinic with ankle pain, and magnetic resonance imaging (MRI) revealed intra-articular bodies compatible with osteochondromatosis. Patient underwent anterior and posterior ankle arthroscopy and, four weeks after surgery, presented with wound dehiscence of the previously healed anterolateral portal. Following the diagnostic work-up, patient was submitted to arthroscopic irrigation and debridement. *Citrobacter koseri* was isolated. After surgical intervention and antibiotic administration, patient's symptoms gradually improved. Six months later, no ankle pain or motion restriction was reported. Clinical symptoms of septic arthritis after ankle arthroscopy can be very mild and, for this reason, a low diagnosis threshold is necessary.

Level of Evidence IV; Therapeutic Studies; Case Report.

Keywords: Ankle; Arthritis, infectious; *Citrobacter koseri*; Arthroscopy; Postoperative complications.

Introduction

Citrobacter koseri (*C. koseri*) is a facultative anaerobic gram-negative bacillus belonging to the *Enterobacteriaceae* family. Members of this family are part of the normal flora of human and animal digestive tracts⁽¹⁾.

C. koseri is a well-known cause of central nervous system infection in pediatric patients but a rare cause of musculoskeletal infection. To our knowledge, there are only six reports of septic arthritis caused by *C. koseri*, none of the ankle⁽²⁾.

Septic arthritis of the ankle is a rare but serious condition that may lead to major cartilage damage. Infection may arise from other infection sites via hematogenous spread or from direct inoculation of microorganisms into the joint, either after traumatic wounds or surgical procedures.

Septic arthritis after arthroscopy has been reported in 0.13% to 1.8% of cases, rising to 3.9% in patients submitted to

intraoperative intra-articular corticosteroid injection⁽³⁾. Association between these two entities is not yet described in the literature, representing a challenging orthopedic condition.

The aim of this article is to describe the first case report of *C. koseri* septic arthritis of the ankle. Informed consent was filled.

Case description

An otherwise healthy 42-year-old male patient presented to our outpatient clinic with an indolent history of ankle pain and edema. There was no recent history of trauma. Patient had a mild dorsiflexion limitation. Magnetic resonance imaging (MRI) revealed flexor hallucis longus (FHL) and posterior tibial tenosynovitis, as well as three nodular lesions in the anterior recess of the ankle compatible with osteochondromatosis (Figure 1).

Study performed at the Centro Hospitalar de Entre o Douro e Vouga, Department of Orthopaedic and Traumatology, Santa Maria da Feira, Portugal.

Correspondence: Alexandre Loureiro de Castro. R. Dr. Cândido Pinho 5, 4520-211, Santa Maria da Feira, Portugal. **E-mail:** alexandredecastro.06@gmail.com

Conflicts of interest: none. **Source of funding:** none. **Date received:** August 31, 2023. **Date accepted:** October 10, 2023. **Online:** October 31, 2023.

How to cite this article: Castro AL, Cunha RDL, Veigas TRA, Pinto EMAM, Carvalho PMA, Teixeira JPL. Septic arthritis of the ankle due to *Citrobacter koseri*: a case report. *J Foot Ankle.* 2023;17(2):122-5

Patient underwent anterior and posterior ankle arthroscopy (Figure 2), where synovectomy was performed with further removal of intra-articular loose bodies and FHL release from its fibro-osseous tunnel. At the end of the procedure, an intra-articular corticosteroid injection was administered. Patient was discharged the following day and weight-bearing was allowed as tolerated.

Four weeks after surgery, patient presented to our outpatient clinic with wound dehiscence of the previously healed anterolateral portal and a posterior ankle hematoma.

Fever, chills, night sweats, or any other sign of systemic illness were not reported. On examination, patient ankle

presented moderate swelling and erythema, but painless range of motion.

Laboratory tests showed $7.61 \times 10^9/L$ leukocytosis with neutrophilia associated with mild elevation of c-reactive protein levels (12.1 mg/L). An ankle ultrasound was performed, showing an hypoechogenic heterogeneous collection of about 2 cm, compatible with hematoma.

With no clear signs of infection at the time, an initial course of anti-inflammatory treatment and cryotherapy was prescribed, with close surveillance of wound healing development.

Because there was no improvement, at five weeks postoperatively, an MRI was ordered and revealed a collection

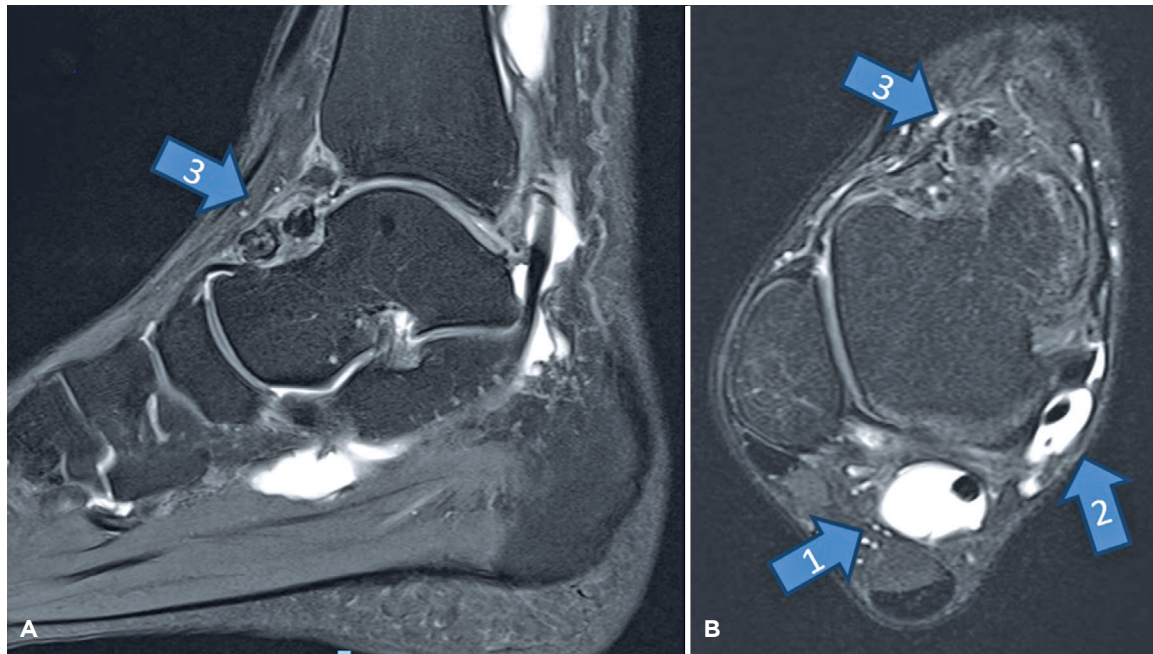


Figure 1. Ankle T2-weighted sagittal (A) and axial (B) magnetic resonance imaging showing flexor hallucis longus (arrow n. 1) and posterior tibial tenosynovitis (arrow n. 2), as well as three nodular lesions in the anterior recess of the ankle, compatible with osteochondromatosis (arrow n. 3).

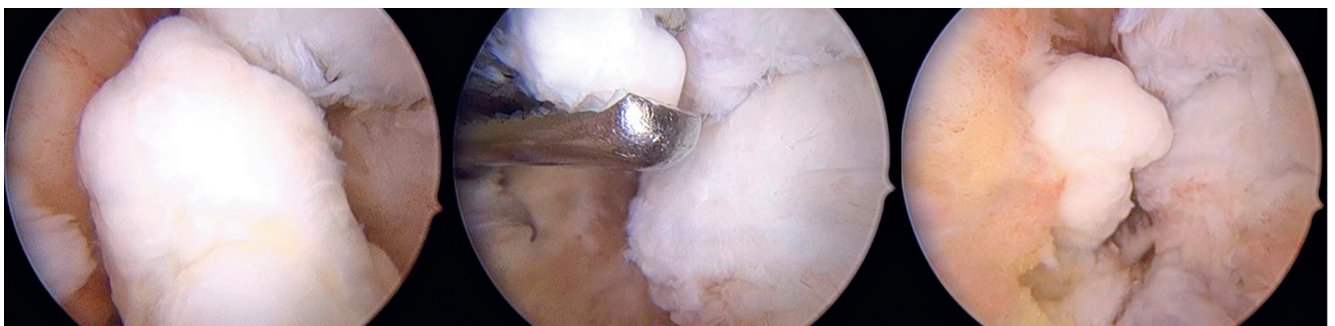


Figure 2. Intraoperative arthroscopic findings included flexor hallucis longus tenosynovitis and nodular lesions in the anterior recess of the ankle, compatible with osteochondromatosis.

of about 2 cm with high signal intensity, compatible with infection. Improvement of FHL and posterior tibial tenosynovitis was also noticed (Figure 3).

Patient was submitted to anterior and posterior arthroscopic irrigation and debridement. Main arthroscopic findings included tissue hyperemia and clots, without purulent collections. Tissue samples were sent for culture and classified as stage I infection according to Gächter classification⁽⁴⁾. Empiric broad-spectrum intravenous antibiotic therapy with vancomycin 1000 mg every 12 hours was initiated.

Postoperative period was uneventful, with progressive improvement of pain and edema, as well as a decrease in inflammatory parameters.

Microbiology cultures identified *C. koseri* as the causative agent of infection. It was sensitive to amoxicillin, ciprofloxacin, gentamicin, and trimethoprim/sulfamethoxazole. At this time, vancomycin was discontinued, and patient received targeted intravenous antibiotic therapy for two weeks - amoxicillin and clavulanic acid -, at which time he was discharged from the hospital. Then, patient received oral antibiotics treatment for four weeks.

During postoperative care, ankle motion was allowed, and progressive weight-bearing was encouraged after wound healing.

At six months of follow-up, no sequelae of septic arthritis were identified, and patient had a good clinical recovery.

Discussion

Native septic arthritis is a relatively uncommon condition either by arthrocentesis at the bedside, open or arthroscopic drainage in the operating room, or imaging-guided drainage in the radiology suite, is mandatory. Methicillin-resistant *Staphylococcus aureus* (MRSA) that requires urgent treatment to avoid cartilage damage and patient clinical deterioration⁽⁵⁾.

As far as we know, septic arthritis of native adult ankle secondary to *C. koseri* has not been previously described in published reports.

C. koseri is considered an opportunistic agent, as it rarely causes infection in healthy individuals. It is commonly found in water, soil, and food, being also found as occasional colonizers of the gastrointestinal tract⁽⁶⁾. *Citrobacter* strains can cause several forms of infections, such as urinary tract, respiratory, intra-abdominal, skin and soft tissue, eye, bone, bloodstream, and central nervous system infections⁽⁶⁾.

In the present case, patient was not immunocompromised and still developed ankle infection caused by *C. koseri*. Corticosteroids exert their anti-inflammatory action by interrupting the inflammatory and immune cascade at several levels, and this could possibly explain why such infection occurred. The association between intra-articular corticosteroid injection and development of infection has been extensively studied, and presence of opportunistic agents as a cause of this infection has also been reported⁽³⁾.

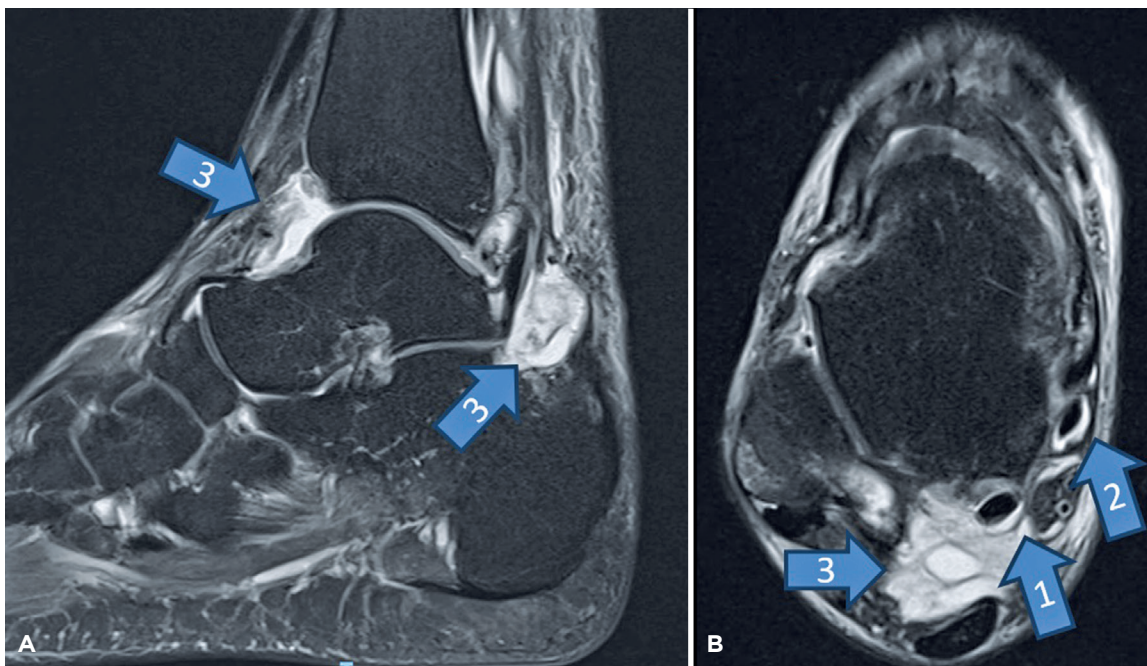


Figure 3. Ankle T2-weighted sagittal (A) and axial (B) magnetic resonance imaging showing improvement of flexor hallucis longus (arrow n. 1) and posterior tibial tenosynovitis (arrow n. 2). No nodules were present but a collection of about 2 cm, with high signal intensity, compatible with infection (arrow n. 3).


Although rare, septic arthritis is a major complication after arthroscopy⁽⁷⁾. Distinguishing postoperative inflammation and postoperative septic arthritis may be difficult, especially in patients with an indolent joint infection⁽⁸⁾. Setting a low threshold for suspicion and diagnostic work-out is important.

The presence of wound dehiscence and joint fluid demanded arthroscopic irrigation and debridement, with positive microbiology cultures for *C. koseri*.

Empiric antibiotic therapy prior to obtaining definitive cultures is based on patient age and/or risk factors, but transition to organism-specific antibiotic therapy should

be made after culture sensitivities are obtained⁽⁵⁾. *C. koseri* is reported to be resistant to aminopenicillins and carboxypenicillins and, throughout time, gained resistance to other antibiotics. Therefore, quinolones and carbapenems have been suggested to be used as treatment options⁽⁶⁾. In our sample, *C. koseri* was sensitive to amoxicillin and clavulanic acid, and we choose this therapy taking into consideration that quinolones are prone to resistance mechanisms.

In conclusion, the unique features of this case re-emphasizes the importance of obtaining a joint aspirate before initiating any antibiotic therapy.

Authors' contributions: Each author contributed individually and significantly to the development of this article: ALDC *(<https://orcid.org/0000-0001-7672-4265>), and JPLT *(<https://orcid.org/0000-0003-4857-1585>) Conceived and planned the activities that led to the study, wrote the paper, participated in the reviewing process, approved the final version; RDDLC *(<https://orcid.org/0000-0002-1834-6857>), and EMDAMP *(<https://orcid.org/0000-0002-4036-7478>) Interpreted the results achieved, approved the final version; TRAV *(<https://orcid.org/0000-0002-7631-9849>) Wrote the paper, approved the final version; PMAC *(<https://orcid.org/0000-0003-1459-6872>) Participated in the reviewing process, approved the final version. All authors read and approved the final manuscript. *ORCID (Open Researcher and Contributor ID) .

References

1. Drelichman V, Band JD. Bacteremias due to *Citrobacter diversus* and *Citrobacter freundii*. Incidence, risk factors, and clinical outcome. *Arch Intern Med*. 1985;145(10):1808-10.
2. Kwaees TA, Hakim Z, Weerasinghe C, Dunkow P. Musculoskeletal infections associated with *Citrobacter koseri*. *Ann R Coll Surg Engl*. 2016;98(7):446-9.
3. Werner BC, Cancienne JM, Burrus MT, Park JS, Perumal V, Cooper MT. Risk of infection after intra-articular steroid injection at the time of ankle arthroscopy in a medicare population. *Arthroscopy*. 2016;32(2):350-4.
4. Stutz G, Kuster MS, Kleinstück F, Gächter A. Arthroscopic management of septic arthritis: stages of infection and results. *Knee Surg Sports Traumatol Arthrosc*. 2000;8(5):270-4.
5. Ross JJ. Septic arthritis of native joints. *Infect Dis Clin North Am*. 2017;31(2):203-18.
6. Deveci A, Coban AY. Optimum management of *Citrobacter koseri* infection. *Expert Rev Anti Infect Ther*. 2014;12(9):1137-42.
7. Sircana G, Passiatore M, Capasso L, Saccomanno MF, Maccauro G. Infections in arthroscopy. *Eur Rev Med Pharmacol Sci*. 2019; 23(2 Suppl):279-87.
8. Voss A, Pfeifer CG, Kerschbaum M, Rupp M, Angele P, Alt V. Post-operative septic arthritis after arthroscopy: modern diagnostic and therapeutic concepts. *Knee Surg Sports Traumatol Arthrosc*. 2021;29(10):3149-58.