

Technical Tips

Anterior and posterior ankle arthroscopy in prone position: description of surgical technique

Gustavo Henrique Carillo Ambrosio¹, André Vitor Kerber Cavalcante Lemos¹, Vinicius Felipe Pereira¹,
Caio Augusto Souza Nery¹, Nacime Salomão Barbachan Mansur¹

1. Universidade Federal de São Paulo - Escola Paulista de Medicina, São Paulo, SP, Brazil.

Abstract

Ankle arthroscopy has several advantages compared to open surgery and can be performed anteriorly or posteriorly. Pathologies located in the anterior and posterior ankle regions may coexist and require combining the abovementioned arthroscopic techniques. The objective of this study was to describe the anterior and posterior ankle arthroscopic technique for treating lateral instability and posterior ankle impact, keeping the patient in prone position. The arthroscopic technique described with the patient in prone position allowed access to the anterior and posterior regions of the ankle, allowing the treatment of lateral ankle instability and posterior impact, potentially reducing the risks present in the change of decubitus position during surgery.

Level of Evidence V; Therapeutic Studies; Expert Opinion.

Keywords: Ankle joint; Arthroscopy; Joint instability; Ligaments; Prone position.

Introduction

Ankle arthroscopy has several advantages compared to open surgery, with less soft tissue trauma and an earlier return to daily and sports activities. It is also an important diagnostic technique for several ankle pathologies⁽¹⁻⁴⁾. Indications for anterior ankle arthroscopy include ankle impingement, osteochondral injuries, and ankle instability. The posterior ankle arthroscopy described by van Dijk covers other indications, such as the posterior ankle impact, flexor hallucis longus tenosynovitis, and subtalar coalitions^(2,5). Pathologies located in the anterior and posterior ankle regions may coexist and require combining the abovementioned techniques, especially in treating anterior and posterior impingement syndrome⁽⁶⁻¹¹⁾.

D'Hooghe et al.⁽¹²⁾ demonstrated that athletes diagnosed with chronic lateral ankle instability are ten times more likely to require surgery to treat the posterior impact by os trigonum than athletes with acute lateral ankle ligament injuries. In contrast, Strauss et al.⁽¹³⁾ demonstrated that lateral

ankle sprains could aggravate the posterior impact caused by os trigonum and become a cause of chronic pain.

Good functional results with arthroscopic treatment for lateral instability and posterior impact, associated with a low incidence of complications, have been reported in the literature^(6-11, 14-19). The combination of anterior and posterior in prone position also obtained good results, and no complications were obtained for impact treatment⁽¹⁰⁾. However, no studies describe the association of techniques in treating lateral instability and posterior impact with the patient kept in prone position.

The objective of this study is to describe the anterior and posterior ankle arthroscopic technique for treating lateral instability and posterior ankle impact, keeping the patient in prone position. This surgical strategy would reduce the risks of contamination of instruments and surgical fields and reduce the operative time, increased by changing the decubitus position. In addition, it would potentially facilitate the operative strategy in cases that require multiple changes in anterior and posterior accesses.

Study performed at the Universidade Federal de São Paulo - Escola Paulista de Medicina, São Paulo, SP, Brazil.

Correspondence: Gustavo Henrique Carillo Ambrosio. Rua Celso de Azevedo Marques, 475 - Apto 21 - Mooca - São Paulo, SP, Brazil. **Email:** gustavo.ambrosio93@gmail.com. **Conflicts of interest:** Caio Nery is Consultant/Speaker da Arthrex Inc, Wright Medical e Gleitlich Biomaterials. **Source of funding:** none. **Date received:** October 8, 2023. **Date accepted:** December 14, 2023. **Online:** April 30, 2024.

How to cite this article: Ambrosio GHC, Lemos AVKC, Pereira VF, Nery CAS, Mansur NSB. Anterior and posterior ankle arthroscopy in prone position: description of surgical technique. J Foot Ankle. 2024;18(1):128-32.

The technique description – preoperative evaluation

This study was approved by the Institutional Review Board, and the patient signed the informed consent form. This study was conducted in accordance with the Declaration of Helsinki and the Health Insurance Portability and Accountability Act (HIPAA).

An 18-year-old male patient without comorbidities, with a history of recurrent sprains and pain in the lateral and posterior region of the right ankle, exacerbated by forced flexion, was selected for the study. The complaints began 12 months prior, after the first episode of ankle sprain, and in that period, the patient was submitted to conservative treatment with physiotherapy and orthosis without improvement. The physical examination showed pain on palpation of the anterolateral gutter, positive anterior drawer test, and pain at the end of ankle flexion, which was reported in the posterior ankle region. It had no deformities on inspection. He was also submitted to radiographs and magnetic resonance imaging, showing damage to the anterior talofibular ligament and os trigonum syndrome associated with spinal cord and fluid bone edema in the posterior tibiotalar and talocalcaneal recesses. Clinical and imaging findings corroborated the diagnosis of chronic lateral instability and posterior ankle impingement (Figures 1-3).

The American Orthopedic Foot and Ankle Society (AOFAS) hindfoot score and the visual analog pain (VAS) scale were collected during the preoperative evaluation, resulting in 67 and 7.2, respectively.

Surgical technique

After sedation, the patient was positioned in prone position with a peripheral block (popliteal and saphenous), and a thigh pneumatic tourniquet was applied (Figure 4).

The surgery started through the posterior access, initially through the posterolateral portals, followed by the posteromedial portal⁽²⁰⁾. The neurovascular bundle was avoided at this stage through lateral access to the flexor hallucis longus tendon. Synovectomy and capsulotomy of the subtalar joint were performed using a shaver blade, allowing the

visualization of the posterior talus region. From that moment on, os trigonum was identified, and its resection began. Using a shaver and Basket forceps, the os trigonum was detached from the talus and partially resected to have its size reduced,

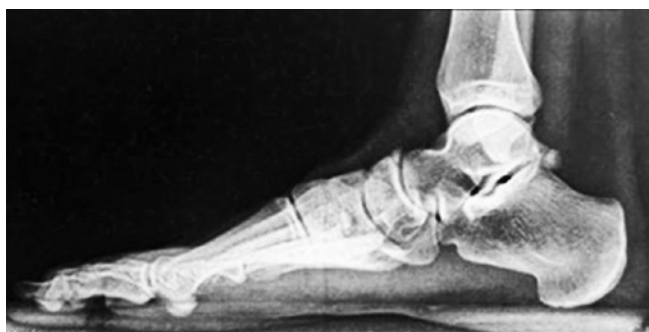

Figure 1. Presence of os trigonum on ankle radiograph in profile position.

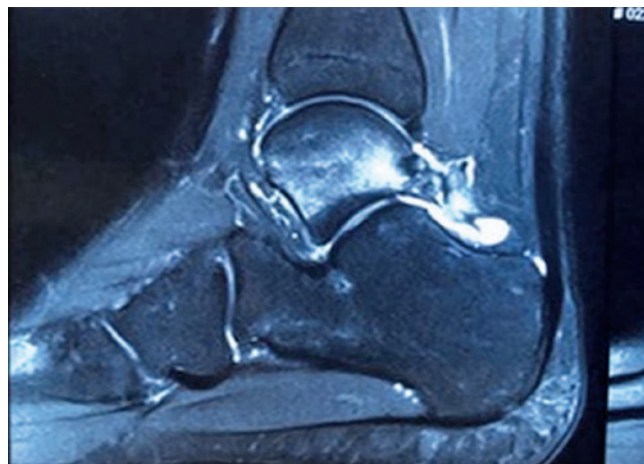


Figure 2. Ankle magnetic resonance imaging in sagittal position showing the *os trigonum* associated with spinal cord and fluid bone edema.

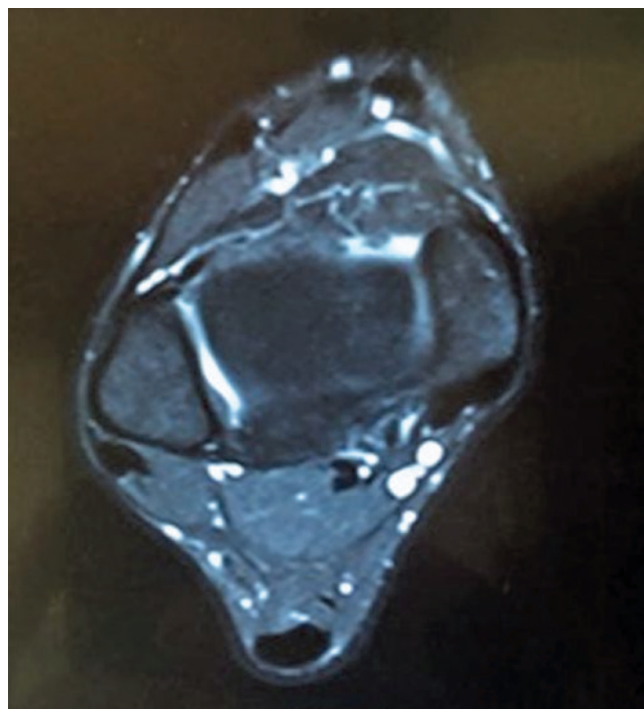


Figure 3. Ankle magnetic resonance imaging in axial position showing the lateral ligament injury.

thus enabling the introduction of Kocher forceps for the total removal of the accessory bone (Figure 5).

Still in prone position, the anterior ankle region was accessed through knee flexion at 90°, which the second

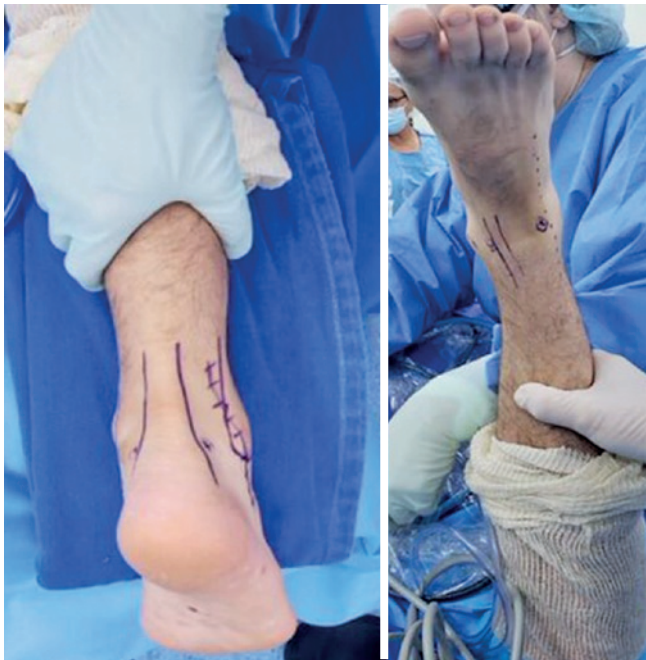

Figure 4. Patient positioned in prone position and anterior and posterior portals marked.

assistant maintained in this position. The anteromedial portals were made, performed medial to the anterior tibial tendon, avoiding the saphenous nerve and the great saphenous vein, followed by the anterolateral portal, performed medial to the superficial fibular nerve to prevent injury, making it possible to visualize the structures such as the anterior arthroscopy performed in dorsal decubitus, but with the upside-down images resulting from the limb position, needing to adapt the conventional intraoperative maneuvers. At this time, synovectomy and lateral gutter debridement were performed to expose the region where the ligaments originate in the fibula. Then, through the anterolateral portal, a 3.0 mm anchor was introduced 1 cm from the lateral malleolus apex using guidewires. The anchor wires were then passed through the safety zone through the lower extensor retinaculum, as described in the arthroscopic Bröstrom-Gould technique^(16,17), and sutures were performed with the ankle in eversion, allowing lateral ligament reconstruction without the need for decubitus change and the exchange of operative fields (Figure 6).

Postoperative period

The patient was instructed to maintain no weight-bearing in the first postoperative week; from the second to the fourth week, progressive partial weight-bearing was initiated with crutches and an immobilizer; from the fifth to the eighth week, a rigid anklet was allowed, then was progressively removed until the end of the sixteenth week.

Rehabilitation with physiotherapy began in the second week, allowing isometric strengthening, gain of ankle extension and eversion, and flexion of up to 20°. Inversion and internal

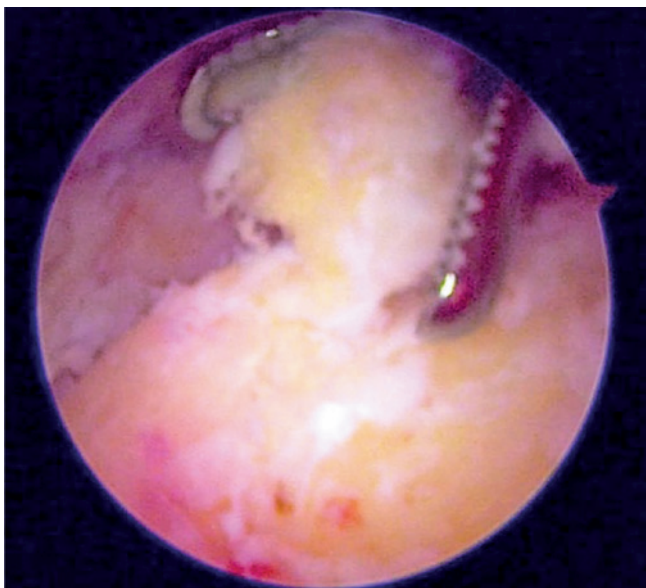


Figure 5. Arthroscopic identification of the os trigonum and its removal with forceps.

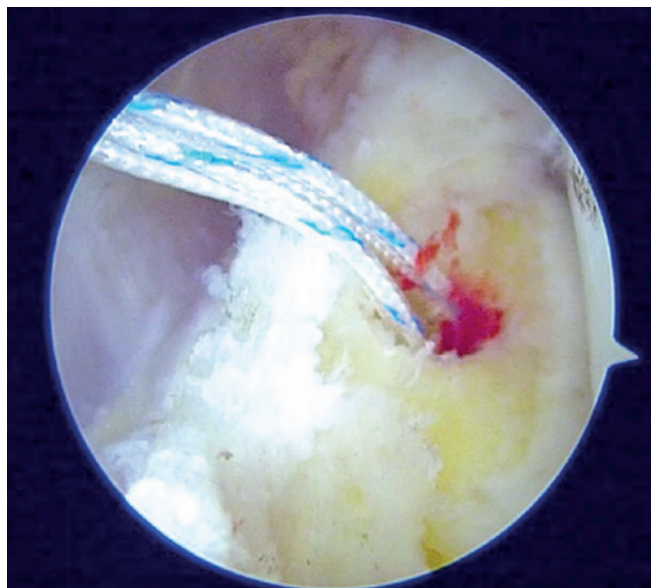


Figure 6. Intraoperative image demonstrating fibula visualization and anchor positioning for lateral ligament reconstruction.

rotation movements were restricted until the sixth week. The sutures were removed in the third week, and no problems with the operative wounds were observed. Light physical activities were released in the sixth week, and the intensity was allowed to increase from the eighth week.

In the twelfth week postoperatively, the patient was already gradually returning to previous physical activities, and the AOFAS and VAS scores were again collected, resulting in 94 and 0, respectively. Comparing the scores and preoperative complaints, the patient showed significant improvement and satisfactory results with the surgery. There were no complications related to the procedure.


Discussion

The arthroscopic techniques described in the literature for treating lateral ankle instability^(14,16-19) and those directed to the posterior ankle impact^(5-11,15) present good functional results and low incidence of complications. Our study aligns with the literature since the reported patient showed improvement in pain and functional scores after surgery, allowing the return to sport in the expected three months without complications associated with surgery.

Distraction during arthroscopy can improve the visualization of a congruent joint such as the ankle⁽²¹⁾. However, complications are associated with this method, such as neurovascular compression and skin necrosis⁽²²⁾. In the technique described, clear images were obtained without the need to apply traction to the limb, avoiding these events.

This study has some limitations. The procedure described imposes greater technical difficulties, requiring an experienced team in arthroscopic procedures. Also, it presents a difficulty in understanding the images, which can be confusing to interpret at first, and the need to adapt the surgical technique of the anterior access with the knee kept flexed. The sample presented was small and without a control group to compare. Other comparative studies are needed to evaluate the reduction in surgical time and the lower risk of contamination of the instruments in the change of decubitus position. In addition, studies with a larger number of patients submitted to the technique and a longer follow-up are necessary to evaluate functional results better.

The arthroscopic technique described with the patient in prone position allowed access to the anterior and posterior regions of the ankle, allowing the treatment of lateral ankle instability and posterior impact, potentially reducing the risks present in the change of decubitus position during surgery.

Authors' contributions: Each author contributed individually and significantly to the development of this article: GHCA *(<https://orcid.org/0000-0002-6458-6317>) Wrote the article, participated in the review process; AVKCL *(<https://orcid.org/0000-0001-8974-5815>) Conceived and planned the activities that led to the study, wrote the article, participated in the revision process, approved the final version; VFP *(<https://orcid.org/0000-0002-1005-6089>) Interpreted the results of the study, participated in the review process; CASN *(<https://orcid.org/0000-0002-9286-1750>) Participated in the revision process, approved the final version; NSBM *(<https://orcid.org/0000-0003-1067-727X>) Conceived and planned the activities that led to the study, wrote the article, participated in the review process, approved the final version. All authors read and approved the final manuscript. *ORCID (Open Researcher and Contributor ID) 

References

- Epstein DM, Black BS, Sherman SL. Anterior ankle arthroscopy: indications, pitfalls, and complications. *Foot Ankle Clin.* 2015;20(1):41-57.
- Rui Xiang T, Zhen Ning Y, Oon Thien Kevin K. Two-Year Outcomes of Posterior Ankle Arthroscopy: A Case Series. *Foot Ankle Spec.* 2022;15(6):556-62.
- Arshad Z, Aslam A, Al Shdefat S, Khan R, Jamil O, Bhatia M. Complications following ankle arthroscopy. *Bone Joint J.* 2023; 105-B(3):239-46.
- Weinraub GM, Vijayakumar A. Arthroscopy for Traumatic Ankle Injuries. *Clin Podiatr Med Surg.* 2023;40(3):529-37.
- Ögüt T, Yontar NS. Treatment of hindfoot and ankle pathologies with posterior arthroscopic techniques. *EFORT Open Rev.* 2017; 2(5):230-40.
- Abdelatif NM. Combined arthroscopic management of concurrent posterior and anterior ankle pathologies. *Knee Surg Sports Traumatol Arthrosc.* 2014;22(11):2837-42.
- Allegra F, Maffulli N. Double posteromedial portals for posterior ankle arthroscopy in supine position. *Clin Orthop Relat Res.* 2010;468(4):996-1001.
- Song B, Li C, Chen Z, Yang R, Hou J, Tan W, et al. Combined Anterior and Dual Posterolateral Approaches for Ankle Arthroscopy for Posterior and Anterior Ankle Impingement Syndrome. *Foot Ankle Int.* 2016;37(6):605-10.
- Wang X, Zhao Z, Liu X, Zhang J, Shen J. Combined Posterior and Anterior Ankle Arthroscopy for Posterior and Anterior Ankle Impingement Syndrome in a Switching Position. *Foot Ankle Int.* 2014;35(8):829-33.
- Kim HK, Jeon JY, Dong Q, Kim HN, Park YW. Ankle arthroscopy in a hanging position combined with hindfoot endoscopy for the treatment of concurrent anterior and posterior impingement syndrome of the ankle. *J Foot Ankle Surg.* 2013;52(6):704-9.
- Miyamoto W, Takao M, Matsui K, Matsushita T. Simultaneous ankle arthroscopy and hindfoot endoscopy for combined anterior and posterior ankle impingement syndrome in professional athletes. *J Orthop Sci.* 2015;20(4):642-8.

12. D'Hooghe P, Alkhelaifi K, Almusa E, Tabben M, Wilson MG, Kaux JF. Chronic lateral ankle instability increases the likelihood for surgery in athletes with os trigonum syndrome. *Knee Surg Sports Traumatol Arthrosc.* 2019;27(9):2813-7.
13. Strauss JE, Forsberg JA, Lippert FG 3rd. Chronic lateral ankle instability and associated conditions: a rationale for treatment. *Foot Ankle Int.* 2007;28(10):1041-4.
14. Nery C, Raduan F, Del Buono A, Asaumi ID, Cohen M, Maffulli N. Arthroscopic-assisted Broström-Gould for chronic ankle instability: a long-term follow-up. *Am J Sports Med.* 2011;39(11):2381-8.
15. Willits K, Sonneveld H, Amendola A, Giffin JR, Griffin S, Fowler PJ. Outcome of posterior ankle arthroscopy for hindfoot impingement. *Arthroscopy.* 2008;24(2):196-202.
16. Nery CAS, Carneiro Filho M, Barrôco RS, Oliveira AC. Tratamento artroscópico da instabilidade crônica do tornozelo. *Revista Brasileira de Ortopedia.* 1997;32(4):257-61.
17. Acevedo JI, Mangone P. Arthroscopic brostrom technique. *Foot Ankle Int.* 2015;36(4):465-73.
18. Acevedo JI, Palmer RC, Mangone PG. Arthroscopic Treatment of Ankle Instability: Brostrom. *Foot Ankle Clin.* 2018;23(4):555-70.
19. Moorthy V, Sayampanathan AA, Yeo NEM, Tay KS. Clinical Outcomes of Open Versus Arthroscopic Broström Procedure for Lateral Ankle Instability: A Meta-analysis. *J Foot Ankle Surg.* 2021;60(3):577-84.
20. van Dijk CN, Scholten PE, Krips R. A 2-portal endoscopic approach for diagnosis and treatment of posterior ankle pathology. *Arthroscopy.* 2000;16(8):871-6.
21. de Leeuw PA, Golanó P, Clavero JA, van Dijk CN. Anterior ankle arthroscopy, distraction or dorsiflexion? *Knee Surg Sports Traumatol Arthrosc.* 2010;18(5):594-600.
22. Ferkel RD, Small HN, Gittins JE. Complications in foot and ankle arthroscopy. *Clin Orthop Relat Res.* 2001;(391):89-104.