

## Case Report

# A rare case of calcaneal bone osteomyelitis resulting from local paracoccidioidomycosis in an immunosuppressed patient: a case report

Eduardo Cezar Silva dos Santos<sup>1</sup> , Cláudia Diniz Freitas<sup>1</sup> , Pedro Bragato Romanholi<sup>1</sup> , Daniel Araújo da Silva<sup>1</sup> , Martha Lúcia Silva Katayama<sup>1</sup> , Eduardo Araújo Pires<sup>1</sup> 

1. Oswaldo Cruz German Hospital Department of Foot and Ankle Surgery, São Paulo, SP, Brazil.

## Abstract

Isolated bone involvement of paracoccidioidomycosis without any pulmonary focus is rare. This report documents the first case of calcaneal osteomyelitis, where bone infection was the only manifestation of the disease. A young 22-year-old male, mixed race, from a rural area in Brazil, was treated in the orthopedics emergency room. He reported a callus in the region of the Achilles tendon and developed intermittent claudication and, at times, inability to walk. In addition to having a low fever and sweating. He was hypertensive and on immunosuppressive medication due to a previous kidney transplant. An intracalcaneal collection was observed on magnetic resonance imaging, requiring surgical treatment for debridement and filling of the bone defect. After surgical intervention and administration of antifungal medication, the patient's symptoms gradually improved. The epidemiological evaluation for differential diagnosis and the multidisciplinary clinical-orthopedic approach with effective diagnosis and treatment enabled the best clinical outcomes for the patient.

**Level of Evidence IV; Therapeutic studies; Case Report.**

**Keywords:** Bioactive glass s53p4; Calcaneo; Immunocompromised Host; Paracoccidioides; Osteomyelitis.

## Introduction

Paracoccidioidomycosis (PCM) is an endemic systemic mycosis caused by thermophilic fungi, *Paracoccidioides brasiliensis*, and Brazil accounts for 80% of the infected worldwide population<sup>(1)</sup>. The biggest risk factors for infection are related to activities that involve managing contaminated soil and patients using immunosuppressive medication<sup>(1,2)</sup>.

Fungal infections of the musculoskeletal system are uncommon and can occur in dead space in infected bone. Several procedures are available to manage bone defects resulting from bone involvement, such as autologous bone grafts, synthetic grafts, and antibiotic-loaded cement-based grafts<sup>(3)</sup>.

This is the first report of osteomyelitis caused by *Paracoccidioides brasiliensis* in the calcaneal bone, and the restoration of the bone defect performed with a bioactive glass (BAG) S53P4 graft (Bonalive<sup>®</sup>) allowed the total rehabilitation of the patient.

## Case description

A 22-year-old male patient residing in a rural area in Brazil was admitted to the orthopedics emergency room complaining of pain in his right ankle. He reported an injury five weeks prior due to a callus in the posterior region of the ankle (Figure 1A) with good wound healing but presented progressive pain in the calcaneus region and intermittent claudication a

Study performed at the Oswaldo Cruz German Hospital Department of Foot and Ankle Surgery, São Paulo, SP, Brazil.

**Correspondence:** Eduardo Cezar Silva dos Santos. R. Treze de Maio, 1815, Paraíso, 01323-903, São Paulo, SP, Brazil. **Email:** [eduardocezarsilva@gmail.com](mailto:eduardocezarsilva@gmail.com).

**Conflicts of interest:** none. **Source of funding:** none. **Date received:** November 14, 2023. **Date accepted:** November 30, 2023. **Online:** December 20, 2023.



few weeks later, mainly at night, coursing with edema, heat, and local redness, in addition to night sweats with low fever (37.5°–37.8° Celsius), without respiratory symptoms. He was hypertensive and submitted to a kidney transplant three years before in continuous use of immunosuppressant medication (Tacrolimus®) and prednisone. Ultrasonography (USG) of soft tissues showed thickening of the Achilles tendon. Laboratory markers of inflammatory/infection status were as follows: leukocyte count = 10,120/mm<sup>3</sup>; C-reactive protein = 5.06 mg/dL, and erythrocyte sedimentation rate = 109 mm/hour. Due to alteration on the USG, magnetic resonance imaging (MRI) of the ankle was performed, showing intense bone edema and an intraosseous collection of 22.5 cm<sup>3</sup> in the calcaneus (Figure 1B) with a transcortical fistulous path into the Achilles tendon (Figure 1C).

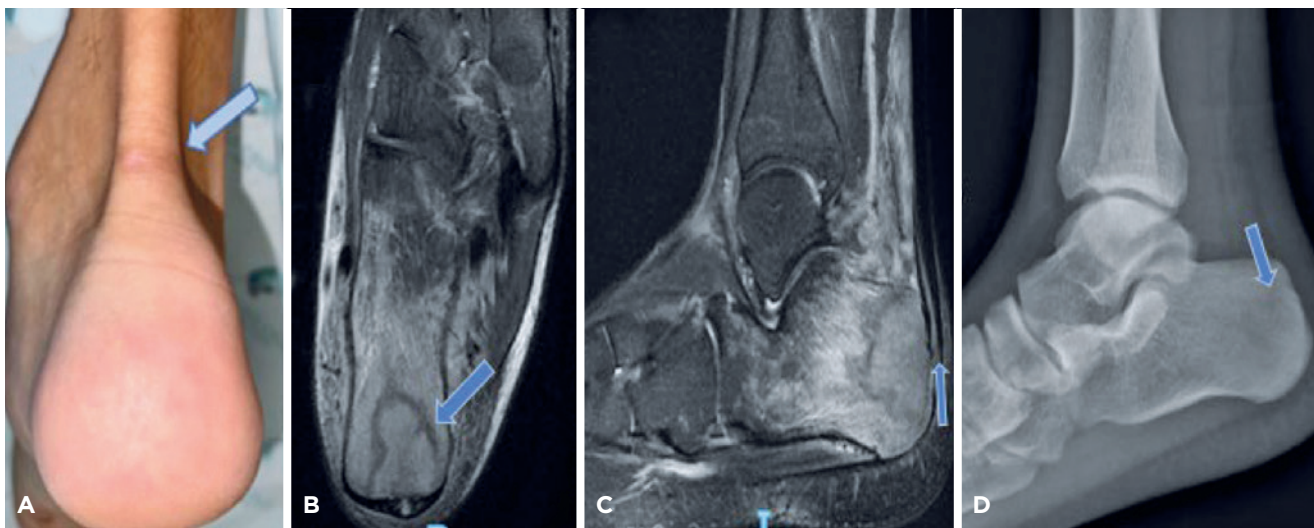
After collecting blood cultures, he started antimicrobial therapy with meropenem and daptomycin at adjusted doses and was hospitalized for surgical treatment. In the intraoperative, drainage of purulent secretion was observed in the Achilles tendon adjacent to the intracalcaneal collection (Figure 2), with signs suggestive of osteomyelitis and a large cortical defect of the posterior calcaneal process. Three surgical procedures were performed to remove all infected and necrotic tissue until healthy bone was exposed (Figures 2E and 2F). Negative pressure therapy dressing was used with instillation and changed weekly until the culture and pathology results were awaited. The cultures were partially negative, but the anatomopathological examination of the bone fragment showed fungal infection in the conventional anatomopathological examination (Figure 3A). After

special Grocott staining, the fungus was distinguished in *Paracoccidioides brasiliensis* (Figure 3B). A daily dose of 200 mg of itraconazole was started. The bone defect was filled with a BAG S53P4 graft (Figure 2), and the patient remained immobilized with load restriction. Pulmonary infection was suspected due to the presence of a granulomatous inflammatory process and the presence of “ground-glass” opacities on tomography, which was not confirmed by complementary exams.

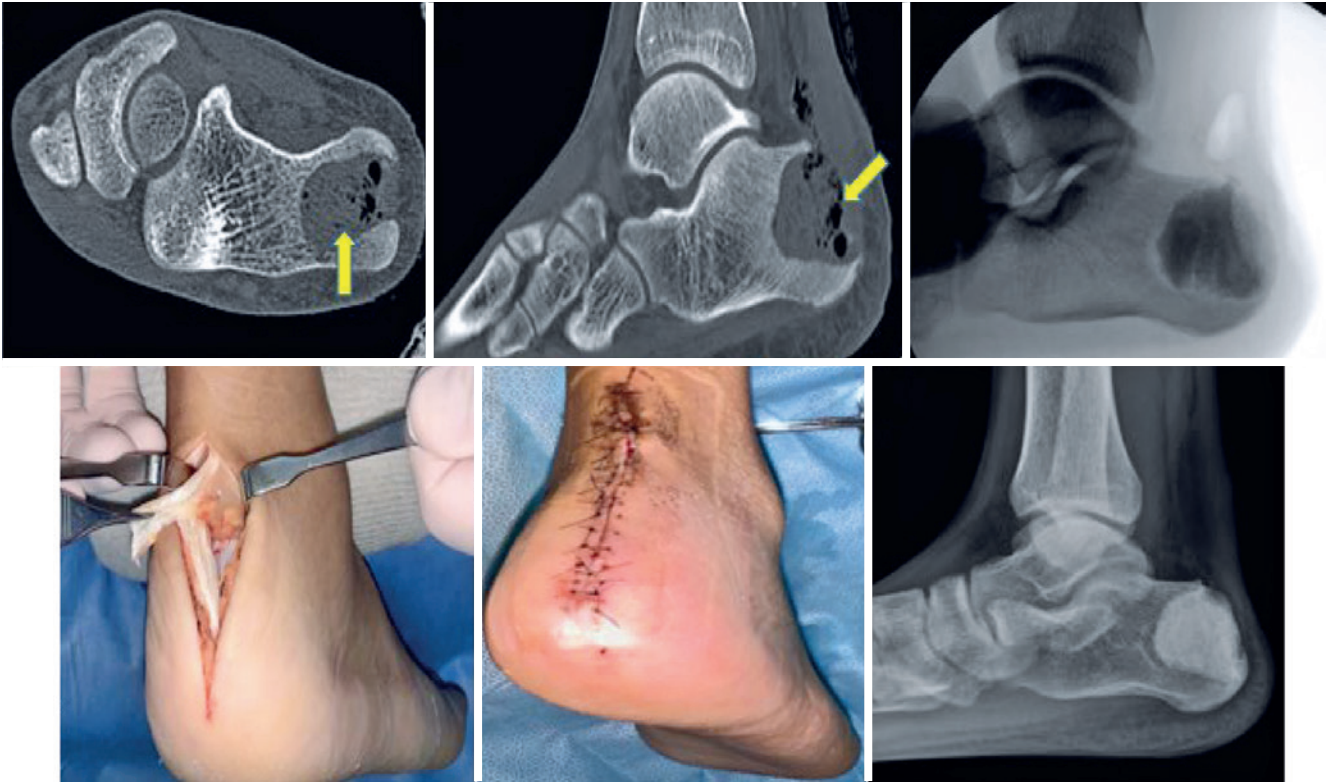
The patient was discharged using itraconazole and reevaluated after one week with no complaints and good wound healing (Figure 2). He returned to his usual activities five months after the surgical procedure and ended the use of antibiotics after eight months. One year after the surgery, the radiographs showed one formation and active remodeling of the biomaterial with good consolidation (Figure 2).

## Discussion

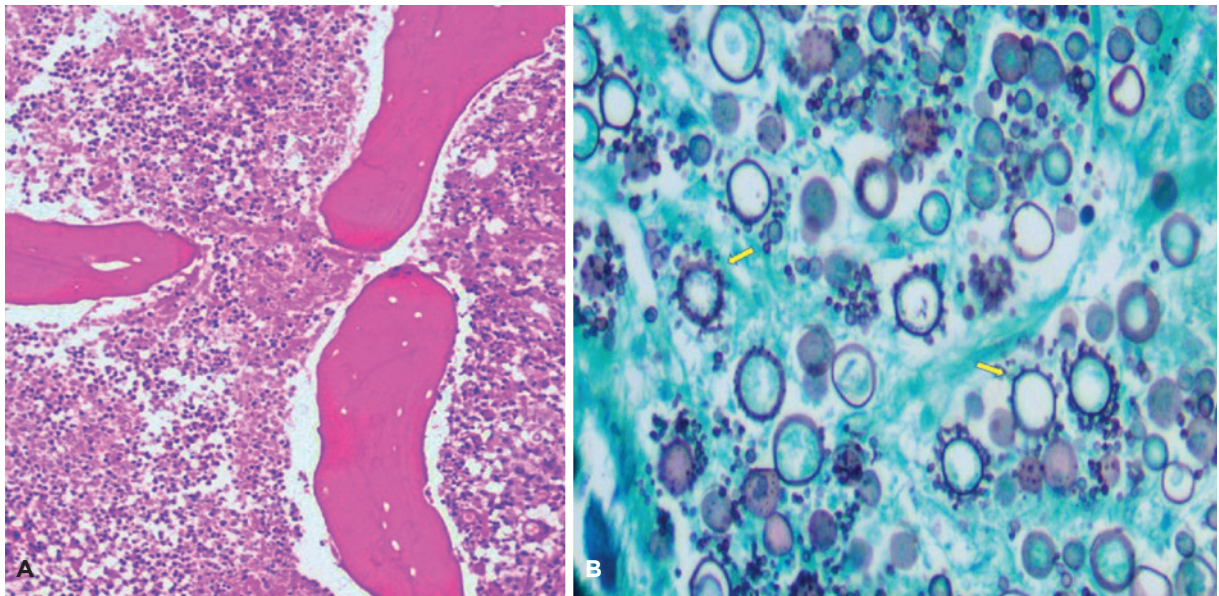
Paracoccidioidomycosis infection, in general, is acquired by inhaling dimorphic fungal propagules with two types of clinical presentations: the acute-subacute (juvenile) and chronic (adult) forms<sup>(4)</sup>. Isolated osteoarticular involvement of *Paracoccidioides brasiliensis* is responsible for approximately 0.01%–0.04% of osteomyelitis, and in the disseminated forms (involving multiple organs), the bone involvement can occur in up to 20% of patients. As described in our report, bone involvement by contiguity from skin lesions is considered rare<sup>(5)</sup>. Osteomyelitis is most common in bone around the thorax because of lymphohematogenous dissemination from the pulmonary system<sup>(5,6)</sup>.



**Figure 1.** (A) Image with an arrow indicating blunt injury site before symptoms. (B) Magnetic resonance imaging – axial T2 FAT SAT. (C) Magnetic resonance imaging – sagittal T2 FAT SAT. Both magnetic resonance imaging show bone edema, an intraosseous collection with a transcortical fistulous path into the Achilles tendon. (D) Lateral radiograph on admission to the orthopedic emergency room, with slight radiographic alteration and little sclerosis around the lesion.



**Figure 2.** Computed tomography - Axial view after surgical debridement. Computed tomography - Sagittal view after surgical debridement. Intraoperative radioscopy after filling with bioactive glass S53P4. Intraoperative image showing drainage of purulent secretion from the calcaneal bone adjacent to the calcaneal tendon sheath. Image before the surgical wound in the outpatient follow-up. Weight-bearing ankle control radiograph after one year of surgical treatment.



**Figure 3.** (A) Histopathological analysis hematoxylin-eosin 100x - bone tissue with neutrophilic inflammatory infiltrate showing extensive necrosis. (B) The histiocytic reaction with epithelioid granulomas predominates. Grocott staining reveals the presence of yeast-like structures with size variation and helm-wheel budding.

In osteoarticular infections, radiographs show lytic lesions without marginal sclerosis, with little or no periosteal reaction, and without pathognomonic signs<sup>(7)</sup>, similar to the radiographic findings of our patient (Figure 1D).

In their series of 19 cases, Monsignore et al.<sup>(6)</sup> demonstrated that performing MRI as a complementary exam was important for the differential diagnosis of bone tumors, bacterial osteomyelitis, histiocytosis, tuberculosis, and other diseases involving the bones. It also demonstrated that most of the findings were in meta-epiphyseal regions of long bones, differing from the bone location in our case. However, it had similar MRI findings, such as exuberant bone edema, well-defined margins, and little sclerotic reaction (Figures 1C and 1D).

As previously mentioned, our patient lived in a rural area and was on immunosuppressive medication due to a previous kidney transplant. The incidence of fungal infections affects only 5% of all infections in transplant patients, and in these patients, PCM infection is a rare condition associated with postrenal transplant immunosuppression<sup>(7)</sup>.

Histopathological evaluation of *Paracoccidioides brasiliensis* by Grocott staining shows rounded elements, with thick birefringent walls, distinguished in single or multiple buds connected to the parental cell by a narrow cytoplasmic bridge, with pathognomonic finding rudder of a ship<sup>(8)</sup>, confirming the findings of this case's analysis of the collected material (Figure 3).


Surgical management can leave a major bone gap that must be repaired, infection recurrence, and bone fragility fractures. Autologous bone grafts are the gold standard for bone reconstruction and have osteogenic, osteoinductive, and osteoconductive properties<sup>(8,9)</sup>. In our case, the BAG S53P4 graft was used; it has bactericidal, osteoinductive, and osteogenic functions, producing an ideal environment for treating bone defects in osteomyelitis. Bioactive glass is

a silica composed of  $\text{SiO}_2$ ,  $\text{Na}_2\text{O}$ ,  $\text{CaO}$ , and  $\text{P}_2\text{O}_5$ , facilitating tissue growth chemically linked to the bone matrix and promoting bone formation. Ion exchange occurs with increased pH and osmotic pressure, ensuring a hostile environment for bacteria without local antibiotics<sup>(9)</sup>. We did not find a specific validation of using BAG S53P4 graft for infection by *Paracoccidioides brasiliensis* in the literature, but the description of the bactericidal function that limits the growth of microorganisms is quite consolidated. Another characteristic of BAG S53P4 in microorganisms is its bacteriostatic effect. An isothermal microcalorimetry study demonstrated a reduction in the microbial activity of microorganisms that cause osteomyelitis<sup>(9)</sup>.

The medications used to control the infection caused by *Paracoccidioides brasiliensis* include amphotericin B, sulfamethoxazole-trimethoprim, and azole derivatives. Unfortunately, amphotericin B is associated with substantial toxicity, while trimethoprim-sulfamethoxazole is associated with relapses. In these situations, azole derivatives are the best option<sup>(10)</sup>.

Due to the risk of toxicity and failure to diagnose disseminated infection, 200 mg/day for eight months was chosen. According to the Brazilian guidelines, the treatment time can vary from nine to 18 months in mild and moderate cases. Continuous investigation of clinical, radiological, and immunological criteria in the patient is necessary<sup>(10)</sup>.

The osteoarticular infection of *Paracoccidioides brasiliensis* is rare in the appendicular skeleton and occurs mostly in renal transplant patients. In this case, the establishment of an interdisciplinary relationship, with an effective surgical approach with identification of the pathogen, filling of the bone defect with a bioactive glass S53P4 graft, and, synergistically, the choice of antifungal therapy appropriate to the patient's comorbidities enabled the patient to return to their usual activities and work effectively.

**Authors' contributions:** Each author contributed individually and significantly to the development of this article: ECSS \*(<https://orcid.org/0000-0001-5018-3923>) conceived and conceived and planned the activities that led to the study, wrote the article, participated in the review process, approved the final version; interpreted study results, participated in the review process; and participated in the review process, approving the final version; CDF \*(<https://orcid.org/0000-0002-6649-2066>), and PBR \*(<https://orcid.org/0000-0002-7215-8187>) Conceived and conceived and planned the activities that led to the study, wrote the article, participated in the review process, approved the final version; and interpreted study results, participated in the review process approved the final version; DAS \*(<https://orcid.org/0009-0008-8395-8797>), and MLSK \*(<https://orcid.org/0009-0009-9003-0863>), and EAP \*(<https://orcid.org/0000-0001-6008-8671>) Interpreted study results, participated in the review process; and participated in the review process, approving the final version. All authors read and approved the final manuscript.\*ORCID (Open Researcher and Contributor ID) 

## References

1. Peçanha PM, Peçanha-Pietrobon PM, Grão-Velloso TR, Rosa Júnior M, Falqueto A, Gonçalves SS. Paracoccidioidomycosis: what we know and what is new in epidemiology, diagnosis, and treatment. *J Fungi (Basel)*. 2022;8(10):1098.
2. Fisher MC, Gurr SJ, Cuomo CA, Blehert DS, Jin H, Stukenbrock EH, et al. Threats Posed by the Fungal Kingdom to Humans, Wildlife, and Agriculture. *mBio*. 2020;11(3):e00449-20.
3. Wassif RK, Elkayal M, Shamma RN, Elkheshen SA. Recent advances in the local antibiotics delivery systems for management of osteomyelitis. *Drug Deliv*. 2021;28(1):2392-414.
4. Restrepo A, Benard G, de Castro CC, Agudelo CA, Tobón AM. Pulmonary paracoccidioidomycosis. *Semin Respir Crit Care Med*. 2008;29(2):182-97.
5. Lima Júnior FV, Savarese LG, Monsignore LM, Martinez R, Nogueira-Barbosa MH. Computed tomography findings of paracoccidioidomycosis in musculoskeletal system. *Radiol Bras*. 2015;48(1):1-6.
6. Monsignore LM, Martinez R, Simão MN, Teixeira SR, Elias J Jr, Nogueira-Barbosa MH. Radiologic findings of osteoarticular infection in paracoccidioidomycosis. *Skeletal Radiol*. 2012;41(2):203-8.
7. Góes HF, Durães SM, Lima Cdos S, Souza MB, Vilar EA, Dalston MO. Paracoccidioidomycosis in a renal transplant recipient. *Rev Inst Med Trop Sao Paulo*. 2016;58:12.
8. Michelan MS, Fernandes Ede A, Freitas LF, Ribeiro RH, Milano MM, Monteiro SS. Osteomyelitis and pyoarthritis resulting from local paracoccidioidomycosis in an immunocompetent patient: a case report. *J Med Case Rep*. 2012;6:342.
9. Gonzalez Moreno M, Butini ME, Maiolo EM, Sessa L, Trampuz A. Antimicrobial activity of bioactive glass S53P4 against representative microorganisms causing osteomyelitis - Real-time assessment by isothermal microcalorimetry. *Colloids Surf B Biointerfaces*. 2020;189:110853.
10. Shikanai-Yasuda MA, Mendes RP, Colombo AL, Queiroz-Telles F, Kono ASG, Paniago AMM, et al. Brazilian guidelines for the clinical management of paracoccidioidomycosis. *Rev Soc Bras Med Trop*. 2017;50(5):715-40.