

Abstract Number: 18052

Sagittal tibiotalar alignment in fixed-bearing total ankle replacement

Guilherme Honda Saito¹, Natalie Nielsen¹, Austin Sanders¹, Scott Ellis¹, Carolyn Sofka¹, Constantine Demetracopoulos¹

1. Hospital for Special Surgery, New York City, USA.

ABSTRACT

Introduction: Implant positioning is critical in total ankle replacement (TAR). However, the effect of sagittal tibiotalar alignment on functional outcomes in fixed-bearing TAR remains unclear. Furthermore, no studies comparing different fixed-bearing implants with respect to the anteroposterior position of the talar component have been performed to date.

Methods: A retrospective analysis of 71 primary TARs in a single center was performed. Prostheses included were the INBONE II[®] (Wright Medical, Memphis, TN) and the Salto Talaris (Integra LifeSciences, Plainsboro, NJ). Radiographic measurements of the tibial-axis-to-talus ratio (T-T ratio) and the anteroposterior offset ratio (AP offset ratio) were performed preoperatively and postoperatively, respectively. Foot and Ankle Outcome Scores (FAOS) and SF-12 MCS and PCS scales were evaluated preoperatively and 2 years postoperatively.

Results: Postoperative sagittal tibiotalar alignment was neutral in 39 ankles and anterior in 32 ankles. No significant differences were observed between groups with respect to clinical outcome scores. Patients with a Salto Talaris prosthesis had a greater AP offset ratio (0.12 ± 0.05) than patients with an INBONE II[®] implant (0.05 ± 0.04) ($P < .01$); however, this increased translation did not correlate with the outcome scores.

Conclusion: At the 2-year follow-up, the INBONE II[®] TAA showed a more neutral sagittal alignment compared with the Salto Talaris prosthesis. However, no correlation between the postoperative AP offset ratio and functional outcome scores was observed with the use of the two fixed-bearing TAR. Further studies with longer follow-ups are needed to determine if the difference in sagittal alignment may have an effect on functional outcomes in the long-term.

Keywords: Arthroplasty, replacement, ankle; Component alignment; Radiologic analysis; Ankle arthritis.

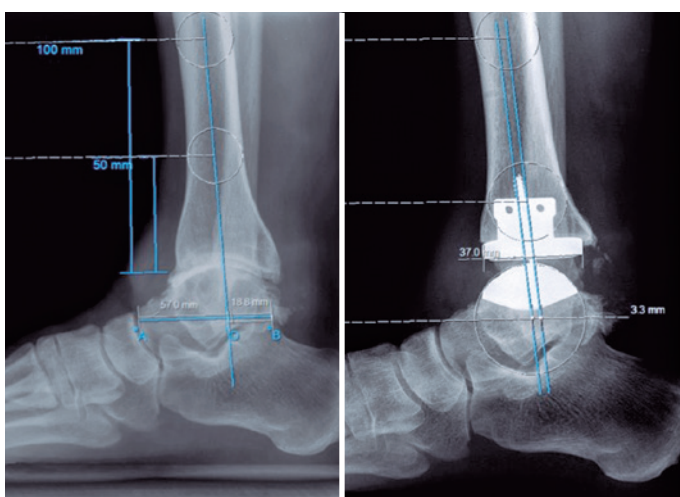


Figure 1. Lateral ankle radiographs showing the T-T ratio and the AP offset ratio.

