

Recurrent painful angioleiomyoma of the hindfoot: a case report

Angioleiomioma doloroso recidivado do retropé: um relato de caso

Eli Ávila Souza Júnior¹, Roberto Zambelli de Almeida Pinto¹, Fernando Araújo Silva Lopes¹

1. Hospital Mater Dei, Belo Horizonte, MG, Brazil.

ABSTRACT

Foot angioleiomyomas are rare tumors that are more prevalent in older women, may be asymptomatic, and rarely recur after surgical excision. We report an atypical case in a young woman of a painful and recurrent angioleiomyoma after excision.

Level of Evidence V; Diagnostic Studies; Expert Opinion.

Keywords: Angiomyoma; Foot diseases; Neoplasm recurrence, local.

RESUMO

Angioleiomiomas do pé são tumores raros, mais prevalentes em mulheres mais velhas, podendo ser assintomáticos, e raramente recidivam após a excisão cirúrgica. Apresentamos um caso atípico ocorrido em mulher jovem, doloroso e recidivado após excisão.

Nível de Evidência V; Estudos Diagnósticos; Opinião do Especialista.

Descritores: Angiomioma; Doenças do pé; Recidiva local de neoplasia.

How to cite this article: Souza Júnior EA, Pinto RZA, Lopes FAS. Recurrent painful angioleiomyoma of the hindfoot: a case report. *Sci J Foot Ankle*. 2019;13(3):232-5.

INTRODUCTION

Angioleiomyomas are rare benign tumors of vascular smooth muscle. According to Berlin⁽¹⁾, the prevalence of angioleiomyomas in the foot is 0.2%. This was based on the histopathological results of 307,601 foot tumors and other lesions analyzed in a large pathology laboratory.

The differential diagnosis of heel pain is extensive. Plantar heel pain typically has a mechanical etiology, including plantar fasciitis, heel spurs, stress fractures and nerve compression. Tumors are a rare cause of pain in the plantar heel⁽²⁾.

We report a case of recurrent hindfoot pain caused by a recurrent angioleiomyoma.

CASE REPORT

This study was approved by the Research Ethics Committee with registration in the Brazil Platform under CAAE number: 18452819.0.0000.5128.

An 18-year-old female patient, without comorbidities, presented with pain and discomfort in the plantar and medial regions of the left hindfoot in January 2017. The

Work performed at the Hospital Mater Dei, Belo Horizonte, MG, Brazil.

Correspondence: Av. do Contorno, 2250, Belo Horizonte, MG, Brazil. CEP 30110-012. E-mail: Eljir42@yahoo.com.br

Conflicts of interest: none. **Source of funding:** none.

Date received: August 29, 2019. **Date accepted:** September 20, 2019. **Online:** September 30, 2019



Copyright © 2019 SciJFootAnkle

patient had no history of trauma or previous incidents of the foot. According to the patient, the pain increased when walking, standing, and applying manual pressure to the plantar-medial region of the hindfoot. She did not notice the appearance of masses or signs of inflammation at the site.

On clinical examination, the patient presented no foot deformities upon weight-bearing, and plantar calluses were observed under the metatarsal heads (Figure 1). On palpation, no expansive lesions were found in the hindfoot, but intensification of pain on deep palpation was observed in the plantar-medial region (Figure 1). Mobility in all segments and the neurovascular examination were normal.

The patient underwent radiographic exams, which were also normal (Figure 2).

Magnetic resonance imaging (MRI) revealed a lesion in the plantar region deep to the flexor digitorum brevis, with reactive bone edema in the inferomedial aspect of the calcaneal body (Figure 3).

The tumor ($3.0 \times 2.0 \times 1.0$ cm in size) was excised in June 2017 through a medial longitudinal access in the hindfoot, and the anatomic-pathological result demonstrated a prolifera-

tion of capillary, venous and arteriolar vessels without atypia, compatible with an angioleiomyoma. After excision, the patient had complete improvement in pain and restored function.

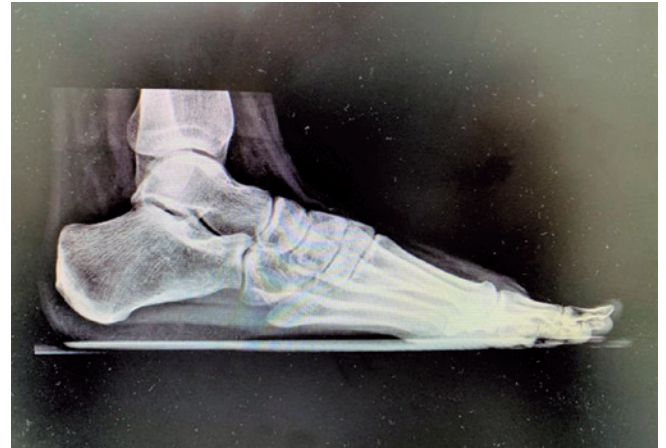

Figure 2. Profile radiograph of the left foot. No lesions were visualized.

Source: Author's personal archive.

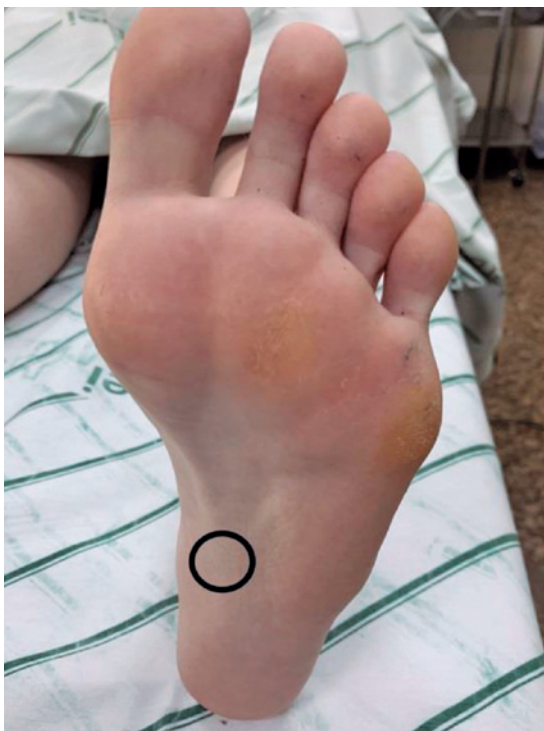

Figure 1. Plantar inspection of the foot showing callused areas in the forefoot and delimitation of the tender area on palpation, without evidence of a mass.

Source: Author's personal archive

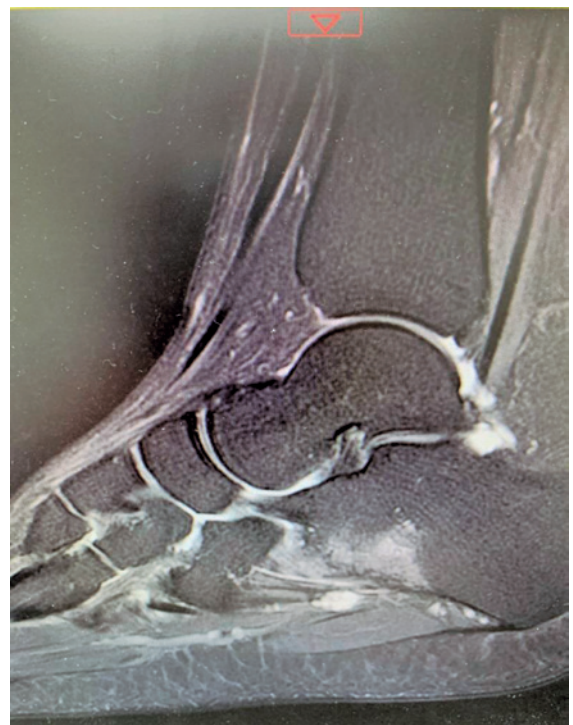

Figure 3. T2-weighted sagittal MRI scan performed in 2017, which showed a hypersignal plantar lesion within the soft tissue causing adjacent bone edema in the calcaneus.

Source: Author's personal archive.

In June 2019, the patient returned to the medical office complaining of recurrence of symptoms in a pattern similar to that previously shown. The physical examination yielded the same results: no palpable masses, localized pain, with subtle improvement in the forefoot callus; the only difference was the presence of the surgical scar. She again underwent an MRI examination (Figure 4), which showed a new lesion with similar characteristics to the previous lesion, causing osteitis in the adjacent calcaneus.

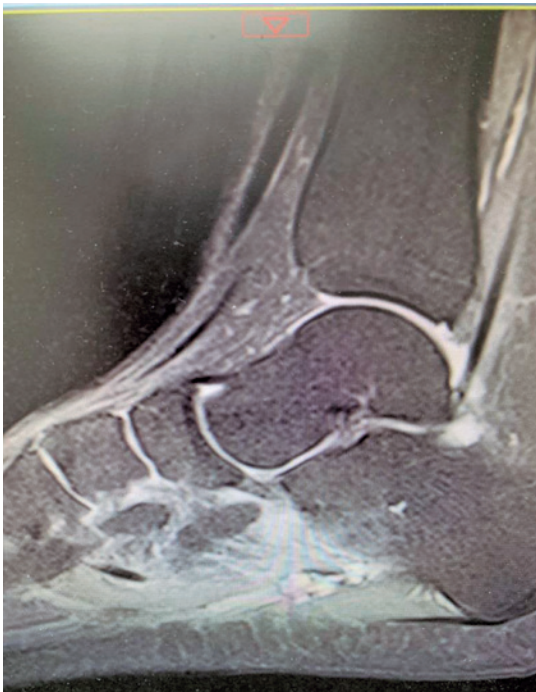

Figure 4. T2-weighted sagittal MRI scan performed in 2019 showing recurrence of the plantar lesion in a postoperative fibrosis area.

Source: Author's personal archive.

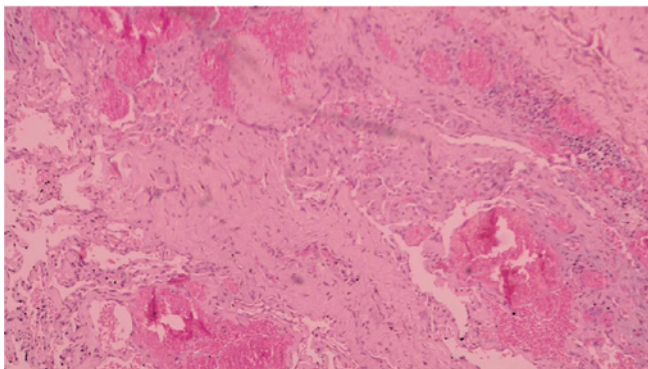


Figure 5. Blood vessel proliferation without atypia, compatible with an angioleiomyoma.

Source: Author's personal archive.

In the same month, the patient underwent a second surgery, this time with lateral longitudinal access to avoid the medial fibrous zone and the plantar load zone, with excision of the recurrent tumor (2.0 × 1.0 × 0.7 cm in size). The tumor had a brownish appearance, and microscopy revealed vascular proliferation similar to the previous sample from 2017 (Figure 5). In the first postoperative assessment, the patient reported improvement of the symptoms.

DISCUSSION

Angioleiomyoma is twice as prevalent in women as in men and mainly affects the middle-aged population; however, it can be found in males and females of all ages. Approximately 50-70% of all angioleiomyomas are found in the lower limbs⁽³⁾. The case reported here stands out due to the early age range of the patient, which is different from most of the prevalent cases reported in the literature.

Three histological subtypes of angioleiomyomas have been described according to their predominant component: solid (capillary), cavernous and venous. Each histological subtype has different clinical characteristics, according to the location of the lesion and the gender of the patient, and the solid form is the most common subtype. The solid form is three times more common in women and often involves the lower extremities. It is usually accompanied by pain⁽⁴⁾. The differential diagnosis includes lipoma, fibroma, ganglions, schwannomas, cutaneous angiomyolipomas, glomus tumors and others⁽⁵⁾. It is believed that angioleiomyomas arise due to vascular malformations, trauma, or venous stasis, and it is believed that estrogen may play a role in the predominance observed in females⁽⁶⁾.

Pain is not always associated with the presence of an angioleiomyoma. However, approximately 60% of patients report some type of pain, which includes sharp pain on pressure that can be affected by temperature. It was hypothesized that this pain may be associated with local tissue anoxia or compression of local neural structures⁽⁷⁾. In the case in question, pain was the main symptom both in the primary presentation and in the recurrence, and presented as described above: worse with local pressure, but without relation to temperature changes.

Angioleiomyomas often have a calcified appearance on X-ray, which may indicate tissue degeneration. In this reported case, the radiographs were normal. Characteristics typical of angioleiomyomas on MRI include a homogeneous or heterogeneous signal that is isointense to the skeletal muscle on T1-weighted images and a predomi-

nantly intermediate to hypointense signal on T2-weighted images, with extensive high-signal intensity lines corresponding to numerous vessels. It is likely that the intensity of the intermediate-to-low signals in the T2-weighted images corresponds to the fibrous tissue or intravascular thrombi within the mass⁽⁸⁾.

Local recurrence after excision is extremely rare. Duhig and Ayer⁽⁹⁾ reported that none of the 61 patients in their series had local recurrence after simple excision. In the largest series, Hachisuga et al.⁽¹⁰⁾ found that only 2 of the 562 patients had tumor recurrence, although their follow-up data were partially incomplete. In the reported case, symptoma-

tic recurrence occurred two years after primary excision, which is uncommon in the literature.

CONCLUSION

Angioleiomyoma should be considered in the differential diagnosis of any tender soft tissue mass in the lower extremities, even in atypical cases such as the one reported herein: a young female patient with painful recurrence. Excision of the lesion and histopathological examination provide a definitive diagnosis and can fully resolve the patient's symptoms; however, the risk of recurrence should always be considered.

Authors' contributions: Each author contributed individually and significantly to the development of this article: EASJ *(<https://orcid.org/0000-0002-5054-874X>) conceived and planned the activities that led to the study, wrote the article, participated in the review process, approved the final version; RZAP *(<https://orcid.org/0000-0001-9692-5283>) interpreted the results of the study, participated in the review process; FASL *(<https://orcid.org/0000-0001-5214-2420>) participated in the review process, approved the final version. *ORCID (Open Researcher and Contributor ID).

REFERENCES

- Berlin S. Statistical analysis of 307,601 tumors and other lesions of the foot. *J Am Podiatr Med Assoc.* 1995;85(11):699-703.
- Cheung MH, Lui TH. Plantar heel pain due to vascular leiomyoma (angioleiomyoma). *Foot Ankle Spec.* 2012;5(5):321-3.
- Gajanthodi S, Rai R, Chaudhry RK. Vascular leiomyoma of foot. *J Clin Diagn Res.* 2013;7(3):571-2.
- Ogura K, Goto T, Nemoto T. Painless giant angioleiomyoma in the subfascia of the lower leg. *J Foot Ankle Surg.* 2012;51(1):99-102.
- Dominguez-Cherit J, Brandariz A. Distal digital angioleiomyoma: a case report and review of the literature. *Int J Dermatol.* 2003;42(2):141-3.
- Ramesh P, Annareddy SR, Khan F, Sutaria PD. Angioleiomyoma: a clinical, pathological and radiological review. *Int J Clin Pract.* 2004;58(6):587-91.
- Requena L, Baran R. Digital angioleiomyoma: an uncommon neoplasm. *J Am Academy Dermatol.* 1993;29:1043-44.
- Gupte C, Butt SH, Tirabosco R, Saifuddin A. Angioleiomyoma: magnetic resonance imaging features in ten cases. *Skeletal Radiol.* 2008;37(11):1003-9.
- Duhig JT, Ayer JP. Vascular leiomyoma: a study of sixty-one cases. *Arch Pathol.* 1965;68:424-30.
- Hachisuga T, Hashimoto H, Enjoji M. Angioleiomyoma: a clinicopathologic reappraisal of 562 cases. *Cancer.* 1984;54(1):126-30.