

Peroneus brevis tendon transfer with the use of an interference screw in Achilles tendon injuries: a functional evaluation

Transferência do tendão fibular curto em lesões do tendão do calcâneo: avaliação funcional com uso do parafuso de interferência

Raul Carlos Barbosa¹, Victor Caponi Borba¹, Bruno Ferreira Gondim¹, Jefferson Soares Martins³, Edegar Nunes Costa²

1. Hospital das Clínicas de Goiânia, Goiânia, GO, Brazil.

2. Centro de Reabilitação e Readaptação Dr. Henrique Santilo, Goiânia, GO, Brazil.

3. Universidade Federal de Goiás, Goiânia, GO, Brazil.

ABSTRACT

Objective: To perform a functional evaluation of peroneus brevis tendon transfer using an interference screw fixation in chronic Achilles tendon injuries.

Methods: This was a cross-sectional, retrospective and observational study with medical record reviews and a convenience sample of ten (10) patients who underwent surgery between January 2013 and June 2017. The following clinical aspects were evaluated: sex, age group, race, affected side, injury time, distal stump size, gap between stumps, AOFAS questionnaire (pre- and 3 and 6 months postoperatively), patient satisfaction with treatment and complications.

Results: The mean subject age was 38.1 years; subjects were predominantly male (80%), and with respect to laterality, the right side was predominant. The paratendinous posterolateral incision technique was used, with the identification and use of the peroneus brevis associated with bone tunnel fixation onto the Achilles using an interference screw. Surgical planning of the technique followed the same procedure in all cases. Two complications occurred during evolution when considering the early and late postoperative periods.

Conclusion: The treatment of Achilles tendon injuries with this technique proved to be a good option for chronic injuries with satisfactory results in terms of maintenance of functionality and patient satisfaction postoperatively.

Level of Evidence IV; Therapeutic Studies; Case Series.

Keywords: Achilles tendon; Bone screws; Tendon transfer/utilization.

RESUMO

Objetivo: Avaliar funcionalmente o uso da transferência do tendão fibular curto fixado com parafuso de interferência em lesões crônicas do tendão calcâneo.

Métodos: Estudo transversal, retrospectivo e observacional com revisão de prontuários, amostra de conveniência e dez (10) pacientes operados entre janeiro de 2013 e junho de 2017. Foram avaliados os aspectos clínicos: sexo, faixa etária, raça, lado acometido, tempo de lesão, tamanho do coto distal, *gap* entre os cotos, questionário AOFAS (pré e pós-operatório com 3 e 6 meses), satisfação com o tratamento e complicações.

Resultados: Idade média de 38,1 anos, sendo predominante no sexo masculino (80%) e com relação à lateralidade, sendo predominante o lado direito. Foi utilizada a técnica de incisão posterolateral paratendinosa, identificação e uso do fibular curto associado à fixação com túnel em calcâneo usando parafuso de interferência. O planejamento cirúrgico da técnica seguiu o mesmo procedimento em todos os casos. Tivemos duas complicações durante a evolução, considerando o pós-operatório imediato e tardio.

Conclusão: O tratamento das lesões de tendão do calcâneo com essa técnica mostrou-se como uma boa opção para o tratamento das lesões crônicas, apresentando resultados satisfatórios na manutenção de funcionalidade e satisfação do paciente no pós-operatório.

Nível de Evidência IV; Estudos Terapêuticos; Série de Casos.

Descritores: Tendão do calcâneo; Parafusos ósseos; Transferência tendinosa/utilização.

Work performed at the Hospital das Clínicas de Goiânia, GO, Brazil.

Correspondence: Raul Carlos Barbosa. Primeira Avenida, sem número – Setor Leste Universitário. CEP: 74605-020 – Goiânia, GO, Brazil.

E-mail: raulcarlosbarbosa@gmail.com

Conflicts of interest: none. **Source of funding:** none.

Date received: January 31, 2018. **Date accepted:** April 16, 2018. **Online:** May 25, 2018.



How to cite this article: Barbosa RC, Borba VC, Gondim BF, Martins JS, Costa EN. Peroneus brevis tendon transfer with the use of an interference screw in Achilles tendon injuries: a functional evaluation. *Sci J Foot Ankle*. 2018;12(2):79-83.

INTRODUCTION

The Achilles tendon is the strongest and thickest tendon of the human body and its injury occurs mostly in men during the third and fourth decades of life with an annual incidence of around 18 to 37 people per 100,000⁽¹⁾.

The Achilles tendon is formed by the convergence of the soleus and gastrocnemius muscles and is approximately 15 cm long and found in the rear part of the calcaneus. The most frequent cause of partial or complete rupture is eccentric overload of the musculotendinous unit. Chronic injuries are those that have gone unnoticed in initial treatment or as a result of re-ruptures of the Achilles tendon⁽¹⁻³⁾.

Such injuries are diagnosed by clinical history and physical examination, in which we note an insufficiency of the gastrosoleus complex characterised by difficulty in walking and weakness in plantar flexion of the ankle. Finally, to complement the investigation, one can make use of additional tests, such as ultrasound and MRI.

In 2005, a meta-analysis by Khan et al. compared surgical and conservative treatment and concluded that the former has a much lower risk of re-rupture, allows early mobilisation and offers a shorter time to return to sport compared with conservative treatment. Surgery is the treatment of choice in patients who are athletes and those who require an early return to their activities⁽⁴⁻⁷⁾.

Numerous surgical techniques have been described for the treatment of chronic Achilles tendon injuries, as management is hampered by significant stump retraction and muscle atrophy, which is an indication for the use of tendon transfers. This study therefore aims to describe the Achilles tendon reconstruction technique by means of the peroneus brevis tendon transfer, using an interference screw for fixation, as well as the functional evaluation of patients undergoing this technique.

In 2014, Singh et al. showed that the peroneus brevis transfer offers a good postoperative functional response compared with primary tenorrhaphy. This can be explained by the fact that rupture sites can show changes in biochemical and genetic expression, resulting in a degeneration and reduction of tendon strength, even after repair^(8,9).

This study was conducted in order to evaluate the effectiveness of the Achilles tendon reconstruction technique with transposition of the peroneus brevis tendon using

interference screw fixation onto the calcaneus in chronic Achilles tendon injuries.

METHODS

This work was approved by the Research Ethics Committee with registration in the Brazil Platform under CAAE number: 73397317.0.0000.5078.

Ten patients with chronic Achilles tendon injuries, confirmed by ultrasound, were evaluated. The patients were treated at a tertiary hospital between January 2013 and June 2017. All patients underwent a peroneus brevis tendon transfer fixed with an interference screw. Patients with diabetes, vasculopathies or acute injuries were excluded. Patients were evaluated in regard to age, sex, race, trauma mechanism, injury time, affected side, distal stump size, gap between the stumps and function. All patients responded to the *American Orthopedic Foot and Ankle Society* (AOFAS) questionnaire, preoperatively and 3 months and 6 months postoperatively; the degree of patient satisfaction was graded as very satisfied, satisfied, or dissatisfied, and complications arising from the surgical approach were also collected.

The surgical technique was performed with the patient in a prone position, with a paratendinous posterolateral incision, identification of the rupture zone and debridement of the stump (Figure 1). From the same incision, the peroneal tendon sheath was opened, and the peroneus brevis tendon was identified and isolated. A mini-incision was made in the fifth metatarsal base region to detach the peroneus brevis tendon, which was then transferred. The guide wire was positioned at an inclination of 45° in relation to the bone surface of the posterior calcaneal tuberosity. A 7.0-mm drill was then used to open the tunnel. The peroneus brevis tendon was inserted through the tunnel and fixed with a 7x20 mm blunt interference screw. The Achilles tendon stumps were attached to the peroneus brevis tendon with 1-0 polyglactin wire.

Postoperatively, patients underwent immobilisation of the lower leg region for 4 weeks in a neutral ankle position. After removal of the immobilisation, physical therapy was initiated to gain range of motion and proprioception. Patients were allowed to use load protected with bracing for two weeks and to use total load after eight weeks.

RESULTS

Eighty percent of the 10 patients evaluated in the study were male, and 20% were female. The mean patient age was 38.1 years old, ranging from 22 to 60 years old.

The mean injury time in the group was 127.1 days, ranging from 40 to 400 days, and the right side was affected in 40% and the left side in 60% of cases. In regard to race, 20% of patients were black, 30% were white, and 50% were brown (Figure 2).

The most common trauma mechanism was sports injury, which comprised 70% of the total injuries, and the primary sport cause was soccer. Traumatic causes accounted for 20% of cases and other causes accounted for 10% (Figure 3).

The mean distal stump size was 2.75cm, varying from 2.5cm to 3.0cm, while the mean gap between stumps was 5.5cm and ranged from 4.0 to 7.0cm.

The mean preoperative functional evaluation score, according to the AOFAS questionnaire, was 53.3 points. The same score 3 months postoperatively was 91.8 points and at 6 months postoperatively it was 94.9 points (Figure 4). Patients rated their satisfaction with treatment as very satisfied in 50% of cases, satisfied in 50% and dissatisfied in 0%.

Two surgically addressed patients (20% of cases) had complications with skin necrosis. These patients were treated using conservative measures (local bandage associated with oral antibiotics) without the need for surgical reapproach.

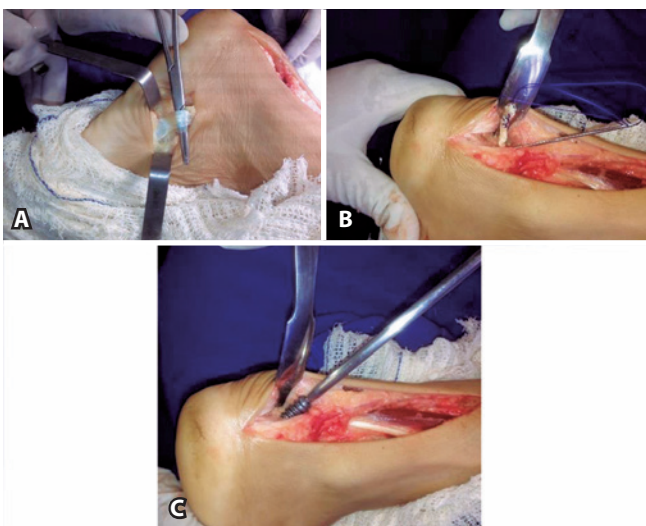

Figure 1. A. Surgical technique: dissection of the peroneus brevis tendon insertion. B. Passage of the peroneus brevis tendon in a transosseous calcaneal tunnel; and C. Fixing of the transferred tendon with interference screw.

Source: Author's personal archive.

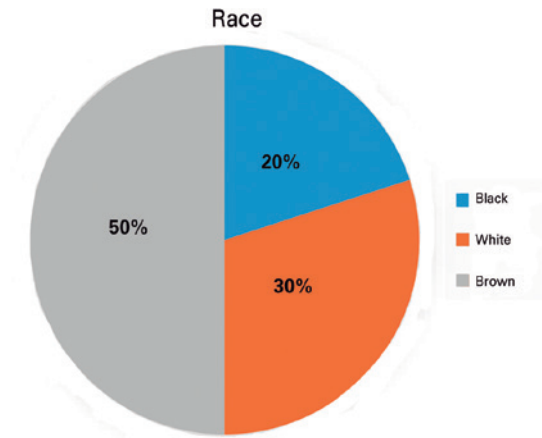


Figure 2. Distribution according to patient race.

Source: Prepared by the author based on the results of the study.

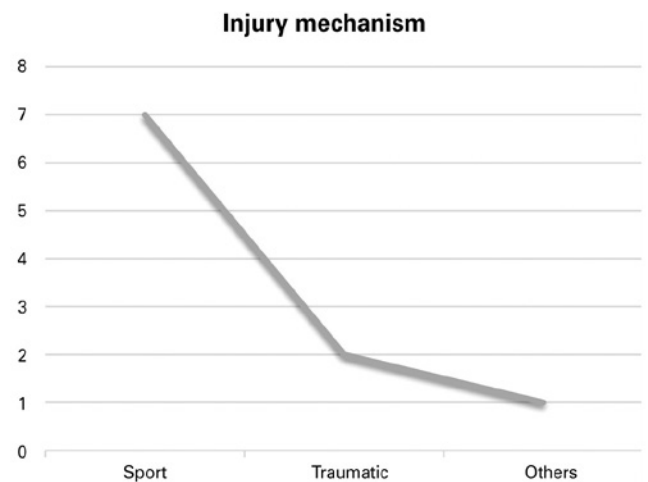


Figure 3. Distribution according to injury mechanism.

Source: Prepared by the author based on the results of the study.

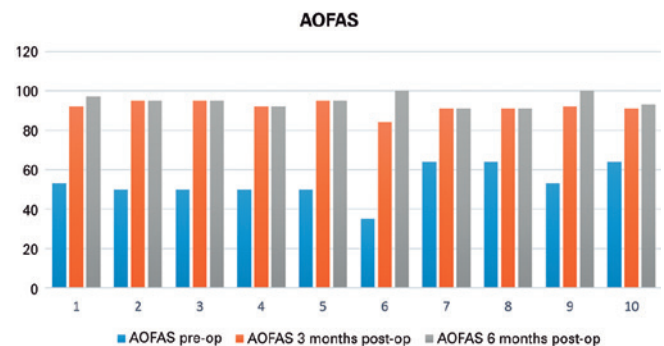


Figure 4. AOFAS score preoperatively (AOFAS1), 3 months after surgery (AOFAS2), and 6 months after surgery (AOFAS3).

Source: Prepared by the author based on the results of the study.

DISCUSSION

This study documents our experience with peroneus brevis tendon transfer fixed with interference screw in the treatment of chronic Achilles tendon injuries with a mean 4.5 years of follow-up (January 2013 to June 2017).

We found a prevalence of Achilles tendon injuries in male patients between 30 and 50 years of age. These data are similar to those reported in the studies by Reito et al. in 2018 and Mann et al. in 1991^(4,10-12).

The surgical option with use of the peroneus brevis tendon to repair and strengthen the injured tendon is an established technique, as described in Teuffer's 1974 studies and confirmed by more recent studies^(3,7-10). This approach has shown satisfactory results in relation to re-rupture rate and patient satisfaction^(3,10,12,13). In our study, we found satisfaction rates similar to those of the above-mentioned studies.

In 1997, Nery et al. showed that the surgical procedure involving removal of the peroneus brevis tendon from its insertion, for use as reinforcement in the repair of Achilles tendon injuries, does not show any decrease in maximal eversion torque when compared with the torque of the non-operated contralateral side⁽⁹⁾. These results demon-

strated that no force imbalance occurs between the foot's evertors and inverters, which we confirmed in our sample.

We observed a low incidence of postoperative complications in our study. We had two cases of wound dehiscence associated with superficial wound infection, which were resolved with conservative measures without the need for any new surgical approach. There were no cases of re-rupture after reconstruction.

In our study, the AOFAS scale evaluations demonstrated excellent functional results in the 3- and 6-month postoperative evaluations compared with data reported in the literature⁽¹¹⁻¹⁵⁾. All patients returned to their activities without functional loss.

CONCLUSION

The surgical technique of peroneus brevis calcaneal tendon graft fixation with interference screw is reproducible and offers optimal functional results according to the AOFAS scale. The technique proved to be a good option for the treatment of chronic Achilles tendon ruptures when compared with data reported by other authors and offers a low complication rate and good reproducibility.

Authors' contribution: Each author contributed individually and significantly to the development of this article: RCB (<https://orcid.org/0000-0003-4923-8370>)* wrote the article, performed the surgery, interpreted the study results, approved the final version; VCB (<https://orcid.org/0000-0001-6232-5204>)* wrote the article, interpreted the results of the study; BFG (<https://orcid.org/0000-0002-1580-0655>)* wrote the article, interpreted the results of the study; JSM (<https://orcid.org/0000-0003-4742-1905>)* conceived and planned the activities that led to the study, performed the surgery, participated in the review process, approved the final version; ENC (<https://orcid.org/0000-0002-6836-3110>)* approved the final version and participated in the review process. *ORCID (Open Researcher and Contributor ID).

REFERENCES

1. Bruggeman NB, Turner NS, Dahm DL, Voll AE, Hoskin TL, Jacofsky DJ, et al. Wound complications after open Achilles tendon repair: an analysis of risk factors. *Clin Orthop Relat Res.* 2004;(427):63-6.
2. Cetti R, Christensen SE, Ejsted R, Jensen NM, Jorgensen U. Operative versus nonoperative treatment of Achilles tendon rupture. A prospective randomized study and review of the literature. *Am J Sports Med.* 1993;21(6):791-9
3. Reito A, Logren HL, Ahonen K, Nurmi H, Paloneva J. Risk factors for failed nonoperative treatment and rerupture in acute Achilles tendon rupture. *Foot Ankle Int.* 2018;1071100717754042.
4. Khan RJ, Fick D, Keogh A, Crawford J, Brammar T, Parker M. Treatment of acute Achilles tendon ruptures. A meta-analysis of randomized, controlled trials. *J Bone Joint Surg Am.* 2005;87(10):2202-10.
5. Jaakkola JI, Hutton WC, Beskin JL, Lee GP. Achilles tendon rupture repair: biomechanical comparison of the triple bundle technique versus the Krakow locking loop technique. *Foot Ankle Int.* 2000; 21(1):14-7.
6. Jaakkola JI, Beskin JL, Griffith LH, Cernansky G. Early ankle motion after triple bundle technique repair vs. casting for acute Achilles tendon rupture. *Foot Ankle Int.* 2001;22(12):979-84.
7. Mann RA, Holmes GB Jr, Seale KS, Collins DN. Chronic rupture of the Achilles tendon: a new technique of repair. *J Bone Joint Surg Am.* 1991;73(2):214-9.
8. Singh A, Nag K, Roy SP, Gupta RC, Gulati V, Agrawal N.: Repair of Achilles tendon ruptures with peroneus brevis tendon augmentation. *J Orthop Surg (Hong Kong).* 2014;22(1):52-5.
9. Nery CAS, Alloza JFM, Laurino CFS, Tanaka GS. Avaliação da força muscular isocinética do pé e tornozelo após tratamento cirúrgico das lesões do tendão de Aquiles, utilizando a transferência do tendão fibular curto. *Rev Bras Ortop.* 1997;32(7):503-12.

10. Wills CA, Washburn S, Caiozzo V, Prietto CA. Achilles tendon rupture. A review of the literature comparing surgical versus nonsurgical treatment. *Clin Orthop Relat Res.* 1986;(207):156-63.
11. Möller A, Astron M, Westlin N. Increasing incidence of Achilles tendon rupture. *Acta Orthop Scand.* 1996;67(5):479-81.
12. Pérez Teuffer A. Traumatic rupture of the Achilles tendon. Reconstruction by transplant and graft using the lateral peroneus brevis. *Clin Orthop North Am* 1974;5(1):89-93.
13. Kuwada GT. Classification of tendon Achillis rupture with consideration of surgical repair techniques. *J Foot Surg.* 1990;29(4): 361-5.
14. Jones MP, Khan RJ, Carey Smith RL. Surgical interventions for treating acute Achilles tendon rupture key findings from a recent Cochrane review. *J Bone Joint Surg Am.* 2012;94(12):e88.
15. Kocher MS, Bishop J, Marshall R, Briggs KK, Hawkins RJ. Operative versus nonoperative management of acute Achilles tendon rupture: expected-value decision analysis. *Am J Sports Med.* 2002;30(6): 783-90.