

All-arthroscopic AMIC® (AT-AMIC) in the treatment of osteochondral talar lesions

AMIC® totalmente artroscópico (AT-AMIC) para o tratamento das lesões osteocondrais do tálus

Tiago Soares Baumfeld⁴, Daniel Soares Baumfeld², Marcelo Pires Prado³, Caio Augusto de Souza Nery¹

1. Universidade Federal de São Paulo, São Paulo, SP, Brazil.
2. Universidade Federal de Minas Gerais, Belo Horizonte, MG, Brazil.
3. Hospital Israelita Albert Einstein, São Paulo, SP, Brazil.
4. Escola Paulista de Medicina, Universidade Federal de São Paulo, São Paulo, SP, Brazil.

ABSTRACT

Objective: The objective of this study was to report the postoperative clinical outcomes of patients undergoing the all-arthroscopic AMIC® technique (AT-AMIC®) combined with autologous bone graft placement as necessary.

Methods: This was a case series of 17 consecutive patients who underwent AT-AMIC® between January 2016 and April 2017. Nine men and eight women between 15 and 67 years of age were diagnosed with an osteochondral talar lesion (OTL) and underwent surgery only after failure of conservative treatment of at least 3 months. Patients answered the AOFAS scale before surgery and at the final follow-up session, which ranged from 8 to 20 months.

Results: The mean size of the OTLs was 1.16cm², and "Raikin-4" was the most common site of lesions (71%). Calcaneal osteotomy was the most commonly associated procedure (18%). The mean follow-up period was 12.3 months. The mean AOFAS score before surgery was 46.4 points, rising to 89.5 points at the last follow-up, and this difference was statistically significant ($p < 0.001$). No complications were observed in any of the treated patients.

Conclusion: AT-AMIC® is a reliable and reproducible treatment method for OTLs and achieves high postoperative clinical scores with very low complication rates.

Level of Evidence IV; Therapeutic Studies; Case Series.

Keywords: Talus; Arthroscopy; Cartilage; Fractures, cartilage.

RESUMO

Objetivo: O objetivo deste estudo é relatar os resultados clínicos pós-operatórios dos pacientes submetidos à técnica AMIC® totalmente realizada através de artroscopia (AT-AMIC®) combinada à colocação de enxerto ósseo autólogo, quando necessário.

Métodos: Esta é uma série de casos de 17 pacientes consecutivos que foram submetidos à AT-AMIC®, entre janeiro de 2016 e abril de 2017. Nove homens e oito mulheres, entre 15 e 67 anos, foram diagnosticados com LOT e submetidos à cirurgia apenas após falha do tratamento conservador de duração mínima de 3 meses. Os pacientes responderam ao escore AOFAS pré-operatório e no último acompanhamento, que variou de 8 a 20 meses.

Resultados: O tamanho médio das LOT foi de 1,16cm², sendo o "Raikin-4" o local o mais comum (71%) das lesões. A osteotomia do calcâneo foi o procedimento mais comumente associado, com a cifra de 18%. O seguimento médio foi de 12,3 meses. O AOFAS médio antes da cirurgia foi de 46,4 pontos, aumentando para 89,5 pontos no último acompanhamento. Essa diferença foi estatisticamente significativa ($p < 0,001$). Não foram observadas complicações em nenhum dos pacientes tratados.

Conclusão: AT-AMIC® é um método de tratamento confiável e reprodutível para as LOT, atingindo altas pontuações clínicas pós-operatórias, com taxa muito baixa de complicações.

Nível de Evidência IV; Estudos Terapêuticos; Série de Casos.

Descritores: Tálus; Artroscopia; Cartilagem; Fraturas de cartilagem.

Work performed at the Hospital São Paulo, Escola Paulista de Medicina, Universidade Federal de São Paulo, São Paulo, SP, Brazil.

Correspondence: Tiago Soares Baumfeld. Rua dos Pampas, 990, Prado – Belo Horizonte, MG, Brazil – CEP: 30411-030. E-mail: tiago.baumfeld@gmail.com

Conflict of interest: Caio Nery is a consultant and speaker for Arthrex, USA. **Source of funding:** none.

Date received: March 03, 2018. **Date accepted:** March 26, 2018. **Online in:** May 25, 2018.



How to cite this article: Baumfeld TS, Baumfeld DS, Prado MP, Nery CAS. All-Arthroscopic AMIC® (AT-AMIC) in the treatment of osteochondral talar lesions. *Sci J Foot Ankle*. 2018;12(2):96-101.

INTRODUCTION

Osteochondral talar lesions (OTLs) are pathological entities that affect the articular cartilage and subchondral bone. They can occur in up to 50% of acute ankle sprains and fractures, particularly in association with sports injuries⁽¹⁾. Various surgical procedures have been used to treat OTLs, such as subchondral bone debridement and microfracture, osteochondral autograft transfer (OATS) and autologous chondrocyte implantation (ACI)⁽²⁾. Although several studies have reported positive postoperative results for these techniques, they are associated with several drawbacks⁽³⁻⁵⁾.

New alternatives for treating these lesions include autologous matrix induced chondrogenesis (AMIC®), which has been found to provide satisfactory results over a medium-term follow-up period⁽⁶⁾. AMIC® combines microfractures with the application of Chondro-Gide®, which is a double layered type I/III collagen matrix (Geistlich Surgery, Wolhusen, Switzerland) used to stabilise and protect the blood clotting that results from the subchondral bone microfractures. Additionally, collagen membranes have been found to be good biomaterials for restoring the subchondral bone, which is a critical step in the regeneration of healthy hyaline cartilage⁽⁷⁾.

Initially, this procedure was performed with an open approach only, but an all-arthroscopic AMIC® technique (AT-AMIC®) has recently been described⁽⁸⁾. This approach has the advantages of smaller incisions, less soft tissue dissection, better visibility of the joint and better patient recovery. It also allows the surgeon to fill any subchondral defect with autologous bone graft in a single procedure⁽⁹⁾.

The objective of this study was to report the postoperative clinical outcomes of patients undergoing the AT-AMIC® technique, combined with autologous bone graft placement when necessary, in the treatment of osteochondral talar lesions.

METHODS

This work was approved by the Research Ethics Committee with registration in the Brazilian Platform under CAAE number: 80854417.7.0000.5505.

This was a case series of 17 consecutive patients who underwent AT-AMIC® between January 2016 and April

2017. Nine men and eight women, between 15 and 67 years of age, were diagnosed with OTL with a typical history of deep pain in the ankle and a corresponding lesion on MRI. The surgery was first proposed after failure of conservative treatment of at least 3 months' duration. Patients answered the American Orthopedic Foot and Ankle Society (AOFAS) scale before surgery and at the final follow-up session, which ranged from 8 to 20 months after surgery. All patients signed an informed consent in order to be included in the study. This study met all requirements regarding human rights and was approved by the ethics committee of our institution.

Statistical analysis was performed using GRETL software (2017c). Student's t-test was used to compare preoperative and postoperative data. In this study, we adopted a value of 0.05 for the alpha error and consequent rejection of the null hypothesis.

Surgical technique

All surgeries were performed using the AT-AMIC® technique⁽⁸⁾. Anterior ankle arthroscopy was performed (Figure 1), where necessary, with the help of a Hintermann™ distractor (Integra LifeSciences, Plainsboro, NJ), which facilitated adequate joint distraction (Figure 2). After identification and debridement of devitalised tissue at the edges and bottom of the osteochondral lesion (Figure 3), microfractures were performed using the Chondro Pick instru-

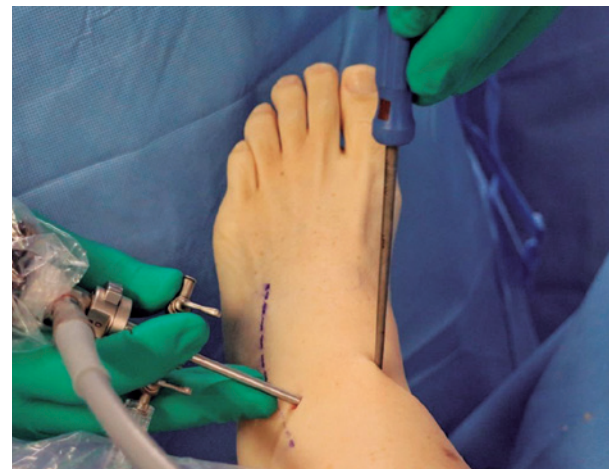

Figure 1. Anterior ankle arthroscopy.
Source: Author's personal archive.

ment (Arthrex, Naples, FL), which facilitates safe drilling of the subchondral bone plate located in the deepest layer of the defect. When irregularities or subchondral cysts were observed at the base of the lesions, we filled and stabilized these defects by grafting autologous cancellous bone removed from the heel body or ipsilateral tibial metaphyses by means of a small percutaneous approach. At the time of introduction and compaction of the cancellous bone graft at the base of the lesions, fluid flow was interrupted within the joint, allowing conditions for dry arthroscopy. Small quantities of cancellous bone were introduced with the use of a cannula and trocar. After impaction, the graft

was fixed by applying a thin coating of fibrin glue (Tisseel®, Baxter, USA) (Figure 4). The approximate shape and dimensions of the lesion were carefully measured with the aid of a graduated arthroscopic probe, creating a “template” for preparing and cutting the collagen membrane. It is imperative to mark the visceral face of the membrane with a surgical pen to ensure that during its positioning over the lesion, the visceral surface is facing downward (Figure 5). Once the membrane was properly positioned to cover the entire surface of the lesion, we glued carefully using the aforementioned fibrin glue (Figure 6). At this point, the Hintermann™ distractor was removed, allowing contact of the articular surfaces that would stabilise the membrane in its proper place. After a few minutes without any movement of the ankle, the arthroscopic portals were sutured, and postoperative immobilisation was applied. All patients were maintained on a sural-pedal plaster splint for 15 days after surgery to prevent mobilisation of the matrix and were then allowed to use a plastic boot and start active and passive movements of the operated ankle. Patients were kept without load for 6 to 8 weeks.

RESULTS

Table 1 shows the demographic data of the 17 patients. Nine left and eight right ankles were treated. The mean size of the OTLs was 1.16cm² and “Raikin-4” was the most common lesion site (71%). Valgus calcaneal osteotomy (Dwyer) for treating hindfoot varus was the procedure most commonly associated with treatment of the OTLs and occurred in 18% of cases. The mean follow-up period was 12.3 months.

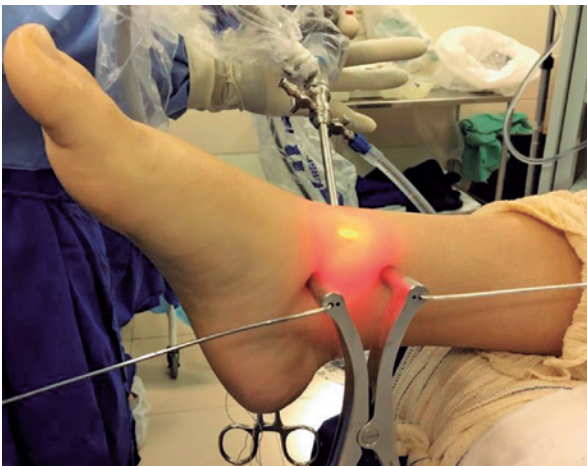

Figure 2. Hintermann™ distractor, which allows joint distraction.
Source: Author’s personal archive.

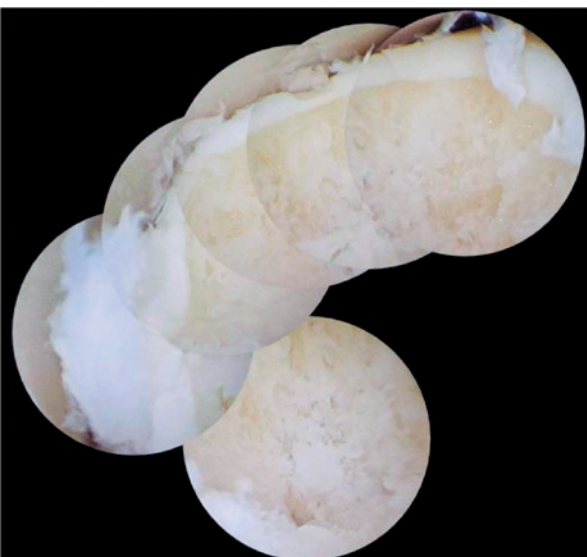

Figure 3. Composite image of OTL after debridement.
Source: Author’s personal archive.

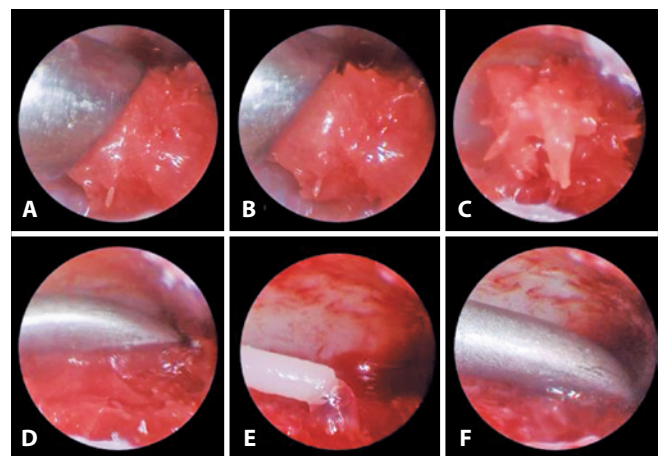


Figure 4. A to C. Cancellous bone covering the defect. D. Impaction of cancellous bone. E to F - Fixation with fibrin glue.
Source: Author’s personal archive.

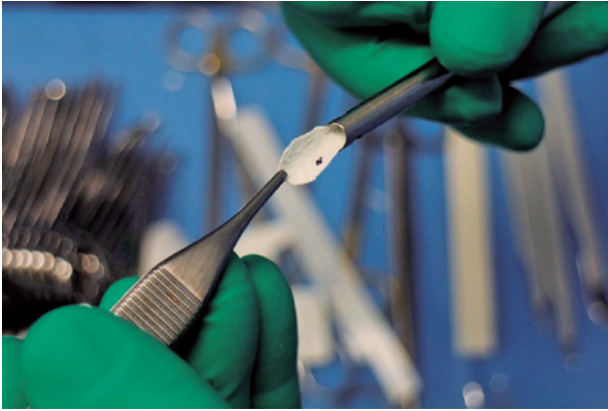


Figure 5. Chondro-Gide® cut and marked with a surgical pen on its visceral surface.

Source: Author's personal archive.

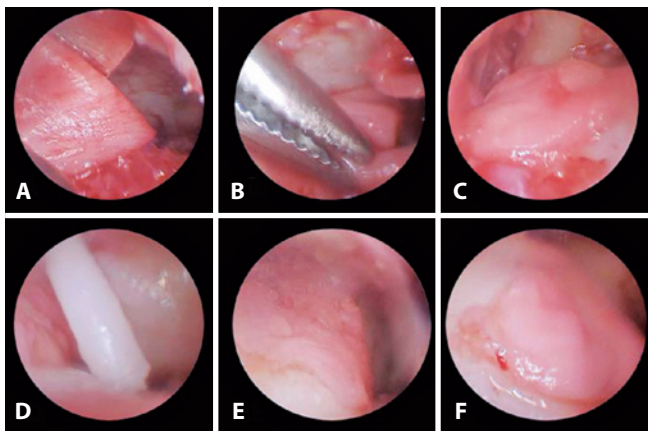


Figure 6. A to C. Positioning of the Chondro-Gide® membrane. D to E - Fixation with fibrin glue. F. Final aspect of construction.

Source: Author's personal archive

The mean preoperative AOFAS score was 46.4, increasing to 89.5 in the final follow-up after surgery. This difference was statistically significant ($p < 0.001$).

No complications were observed, and no changes were necessary in the postoperative protocol for the patients in this study.

DISCUSSION

The goal of OTL treatment is to create a healthy environment for cartilage regeneration, eliminate pain and restore ankle function. Many techniques have been described aiming at such purposes, such as bone marrow stimulation, autologous chondrocyte implantation and particulated juvenile cartilage allograft⁽¹⁰⁾. Microfracture-derived fibrocolla-

gen is composed mainly of type I collagen and has been described as having biological and biomechanical properties inferior to those of normal hyaline cartilage^(11,12). In addition, microfracture has good results in the short term but inferior clinical results in studies with longer follow-up, in older patients and in cases of deep lesions and lesions of the central quadrants⁽¹³⁾.

To resolve these problems, AMIC® has been used on the knee, hip and ankle with very satisfactory clinical and radiological results, along with matrix autologous chondrocyte implantation (MACI), a more complex and expensive cell-based cartilage repair technique^(14,15). With a minimum follow-up of two years, Valderrabano et al. and Walther and Martin have reported excellent clinical and radiological results using AMIC®, which obtained high AOFAS and MOCART scores^(16,17). In a very recent prospective cohort study, Gottschalk et al. corroborated these findings and found high clinical satisfaction in a 5-year follow-up, which is the longest in the literature⁽¹⁸⁾. The greatest benefits of the technique were observed in the first year; however, additional clinical satisfaction was achieved after five years.

Traditionally, the AMIC® technique is applied using a medial malleolus osteotomy or miniarthrotomy⁽¹⁹⁾. The medial malleolus osteotomy increases the morbidity of the treatment and has some significant drawbacks, such as the risk of injury to surrounding structures, risk of consolidation delay or pseudoarthrosis and joint degeneration in the long term, inducing or increasing the possibility of the emergence of osteoarthritis⁽²⁰⁾.

AT-AMIC® is a minimally invasive approach that allows the surgeon to enjoy the benefits of membrane-based treatment without damaging the soft tissue. It may, however, cause complications arising from anterior ankle arthroscopy, ranging from 3.4 to 9.0%⁽²¹⁾. This technique has been described and used on the knee, shoulder, hip and ankle, with encouraging results⁽²²⁻²⁵⁾. In 2018, Usulli et al. published the first medium-term results of the AT-AMIC® technique for the talus, with a minimum follow-up of 24 months. Their twenty patients achieved a mean AOFAS score of 86.6 (within the good mean results from the literature) and a mean MOCART score of 50.9 at the final follow-up. The authors suggest that foot and ankle surgeons should adopt the AT-AMIC® technique for the treatment of OTLs because of the low risk of complications, its effectiveness and its minimally invasive approach⁽²⁵⁾.

Our series corroborates previous studies by showing that AT-AMIC® can achieve very satisfactory results. Our

Table 1 | Patient data

Patient No.	Side	Age	Gender	AOFAS PRE	AOFAS POST	Follow-up	Size (cm ²)	Raikin Site	Associated procedure
1	D	23	M	68	86	8	1.13	9	-
2	E	30	M	68	90	8	1.09	9	-
3	D	30	M	28	87	16	2.35	5	Syndesmosis stabilisation
4	D	34	M	32	85	9	1.02	7	-
5	E	32	F	71	100	18	0.62	7	-
6	D	21	F	52	90	17	2.07	4,5,6,7	Arthroscopic Brostrom
7	D	37	F	33	90	14	1.33	4,5,6,7	Calcaneal osteotomy
8	D	46	F	44	86	13	0.75	1,2,3,4	Arthrolysis
9	E	48	M	60	92	20	3.41	1,4,7	Calcaneal osteotomy + anterior impact
10	E	67	F	59	86	10	0.69	4	Calcaneal osteotomy
11	E	60	F	36	82	14	0.88	4,5,6,7	-
12	D	67	F	34	87	14	0.82	4,5,6,7	-
13	E	19	M	37	97	11	0.61	4	-
14	E	44	M	42	85	11	0.79	4	-
15	D	15	M	46	96	9	0.63	4,5,6,7	-
16	E	30	M	38	93	9	0.66	1,2,3,4	-
17	E	35	F	40	90	8	0.86	4	-
Mean		37.5		46.4	89.5	12.3	1.16		

Source: Prepared by the author based on the results of the study.

patients achieved a mean AOFAS score of 89.5 at the final follow-up, with no complications being observed in this short observation period.

The most important finding of this study is that AT-AMIC® is a reliable and reproducible OTL treatment method that achieved high postoperative clinical scores without complications. The disadvantages of this study are its retrospective method, with no control group, the lack of radiological

assessment of reparative tissue and the lack of observation of surgery time and time until return to sports activity.

CONCLUSION

AT-AMIC® is a reliable and reproducible OTL treatment method and achieved high postoperative clinical scores without complications in this study. More studies are needed, with a prospective methodology, to confirm its effectiveness.

Authors' contribution: Each author contributed individually and significantly to the development of this article: TSB (<https://orcid.org/0000-0001-9244-5194>)* conceived and planned the activities that led to the study, interpreted the results of the study, wrote the article and approved the final version; DSB (<https://orcid.org/0000-0001-5404-2132>)* conceived and planned the activities that led to the study, performed the surgeries, participated in the review process and approved the final version; MPP (<https://orcid.org/0000-0003-3812-9320>)* performed the surgeries, participated in the review process and approved the final version; CASN (<https://orcid.org/0000-0002-9286-1750>)* conceived and planned the activities that led to the study, performed the surgeries, participated in the review process and approved the final version. *ORCID (Open Researcher and Contributor ID).

REFERENCES

- Savage-Elliott I, Ross KA, Smyth NA, Murawski CD, Kennedy JG. Osteochondral lesions of the talus: a current concepts review and evidence-based treatment paradigm. *Foot Ankle Spec.* 2014;7(5): 414-22.
- Kraeutler MJ, Chahla J, Dean CS, Mitchell JJ, Santini-Araujo MG, Pinney SJ, Pascual-Garrido C. Current concepts review update. *Foot Ankle Int.* 2017;38(3):331-42.
- Giannini S, Buda R, Faldini C, Vannini F, Bevoni R, Grandi G, Grigolo B, Berti L. Surgical treatment of osteochondral lesions of the talus in young active patients. *J Bone Joint Surg Am.* 2005;87(Suppl 2): 28-41.
- Knutsen G, Drogset JO, Engebretsen L, Grøntvedt T, Isaksen V, Ludvigsen TC et al. A randomized trial comparing autologous chondrocyte implantation with microfracture: findings at five years. *J Bone Joint Surg Am.* 2007;89(10):2105-12.

5. Schneider TE, Karaikudi S. Matrix-induced autologous chondrocyte implantation (MACI) grafting for osteochondral lesions of the talus. *Foot Ankle Int.* 2009;30(9):810-4.
6. Gottschalk O, Altenberger S, Baumbach S, Kriegelstein S, Dreyer F, Mehlhorn A, et al. Functional medium-term results after autologous matrix-induced chondrogenesis for osteochondral lesions of the talus: a 5-year prospective cohort study. *J Foot Ankle Surg.* 2017; 56(5):930-936.
7. Cavallo M, Buda R, Vannini F, Castagnini F, Ruffilli A, Giannini S. Subchondral bone regenerative effect of two different biomaterials in the same patient. *Case Rep Orthop.* 2013;2013:850502.
8. Usuelli FG, de Girolamo L, Grassi M, D'Ambrosi R, Montrasio UA, Boga M. All-arthroscopic autologous matrix-induced chondrogenesis for the treatment of osteochondral lesions of the talus. *Arthrosc tech.* 2015;4(3):e255-9.
9. D'Ambrosi R, Maccario C, Ursino C, Serra N, Usuelli FG. Combining Microfractures, Autologous bone graft, and autologous matrix-induced chondrogenesis for the treatment of juvenile osteochondral talar lesions. *Foot Ankle Int.* 2017;38(5):485-495.
10. Grambart ST. Arthroscopic management of osteochondral lesions of the talus. *Clin Podiatr Med Surg.* 2016;33(4):521-30.
11. Murawski CD, Foo LF, Kennedy JG. A review of arthroscopic bone marrow stimulation techniques of the talus: the good, the bad, and the causes for concern. *Cartilage.* 2010;1(2):137-44.
12. Nehrer S, Spector M, Minas T. Histologic analysis of tissue after failed cartilage repair procedures. *Clin Orthop Relat Res.* 1999;(365):149-62.
13. Yoshimura I, Kanazawa K, Takeyama A, Angthong C, Ida T, Hagio T, et al. Arthroscopic bone marrow stimulation techniques for osteochondral lesions of the talus: prognostic factors for small lesions. *Am J Sports Med.* 2013;41(3):528-34.
14. Giannini S, Buda R, Ruffilli A, Cavallo M, Pagliuzzi G, Bulzamini MC, et al. Arthroscopic autologous chondrocyte implantation in the ankle joint. *Knee Surg Sports Traumatol Arthrosc.* 2014;22(6):1311-9.
15. Mancini D, Fontana A. Five-year results of arthroscopic techniques for the treatment of acetabular chondral lesions in femoroacetabular impingement. *Int Orthop.* 2014;38(10):2057-64.
16. Valderrabano V, Miska M, Leumann A, Wiewiorski M. Reconstruction of osteochondral lesions of the talus with autologous spongiosa grafts and autologous matrix-induced chondrogenesis. *Am J Sports Med.* 2013;41(3):519-27.
17. Walther M, Martin K. Scaffold based reconstruction of focal full thickness talar cartilage defects. *Clin Res Foot Ankle.* 2013;1(2):115.
18. Gottschalk O, Altenberger S, Baumbach S, Kriegelstein S, Dreyer F, Mehlhorn A, et al. Functional medium-term results after autologous matrix-induced chondrogenesis for osteochondral lesions of the talus: a 5-year prospective cohort study. *J Foot Ankle Surg.* 2017;56(5):930-6.
19. Walther M, Altenberger S, Kriegelstein S, Volkering C, Röser A. Reconstruction of focal cartilage defects in the talus with miniarthrotomy and collagen matrix. *Oper Orthop Traumatol.* 2014; 26(6):603-10.
20. Kreuz PC, Steinwachs M, Edlich M, Kaiser T, Mika J, Lahm A, Südkamp N. The anterior approach for the treatment of posterior osteochondral lesions of the talus: comparison of different surgical techniques. *Arch Orthop Trauma Surg.* 2006;126(4):241-6.
21. Ferkel RD, Small HN, Gittins JE. Complications in foot and ankle arthroscopy. *Clin Orthop Relat Res.* 2001;(391):89-104.
22. Piontek T, Ciemnievska-Gorzela K, Szulc A, Naczek J, Słomczykowski M. All-arthroscopic AMIC procedure for repair of cartilage defects of the knee. *Knee Surg Sports Traumatol Arthrosc.* 2012;20(5):922-5.
23. Fontana A. Autologous Membrane Induced Chondrogenesis (AMIC) for the treatment of acetabular chondral defect. *Muscles Ligaments Tendons J.* 2016;6(3):367-71.
24. Cuéllar A, Ruiz-Ibán MÁ, Cuéllar R. The use of all-arthroscopic autologous matrix-induced chondrogenesis for the management of humeral and glenoid chondral defects in the shoulder. *Arthrosc Tech.* 2016; 5(2):e223-7.
25. Usuelli FG, D'Ambrosi R, Maccario C, Boga M, de Girolamo L. All All-arthroscopic AMIC® (AT-AMIC®) technique with autologous bone graft for talar osteochondral defects: clinical and radiological results. *Knee Surg Sports Traumatol Arthrosc.* 2018;26(3):875-81.