

# Macrodactyly: case series

## Macrodactilia: série de casos

Felipe Cunha Pessôa<sup>1</sup>, Edegar Nunes Costa<sup>2</sup>, Jefferson Soares Martins<sup>1</sup>

1. Hospital das Clínicas de Goiânia, Goiânia, GO, Brazil.

2. Centro de Reabilitação e Readaptação Dr. Henrique Santilo, Goiânia, GO, Brazil.

### ABSTRACT

Macrodactyly is a rare condition characterized by an increased volume of all mesenchymal structures that compose the digit and can affect the hands and feet. Macrodactyly is defined as primary when isolated or secondary when associated with other congenital malformations. The aim of the present study was to report three cases of primary macrodactyly of the foot, treated by surgical amputation of the rays or forefoot, which led to satisfactory clinical outcomes. The results corroborate the present literature about the disease, which indicates that treatment is eminently surgical but may comprise various treatment forms.

**Level of Evidence IV, Therapeutic Studies; Expert Opinion.**

**Keywords:** Foot; Gigantism/pathology; Foot deformities, congenital.

### RESUMO

Macrodactilia é uma condição rara caracterizada pelo aumento de volume de todas estruturas mesenquimais que compõem o dígito, podendo acometer mãos e pés. É definida como primária quando isolada ou secundária quando associada a outras malformações congênitas. O seguinte trabalho tem por finalidade a apresentação de três casos de macrodactilia primária do pé, cujo tratamento cirúrgico foi a amputação de raios e antepé, que levou a desfecho clínico satisfatório, corroborando com a presente literatura sobre a doença, cujo tratamento é eminentemente cirúrgico, mas que pode compreender diversas formas de tratamento.

**Nível de Evidência IV; Estudos Terapêuticos; Opinião de Especialista.**

**Descritores:** Pé; Gigantismo/patologia; Deformidades congênitas do pé.

**How to cite this article:** Pessôa FC, Costa EM, Martins JS. Macrodactyly: case series. Sci J Foot Ankle. 2018;12(3):255-9.

### INTRODUCTION

Macrodactyly is a rare congenital condition in which one or more fingers or toes are disproportionately larger than the others. It occurs by the hypertrophy of all mesenchymal tissues<sup>(1,2)</sup>, simultaneously involving the soft tissues and bony components<sup>(3-5)</sup> of the affected digit. It

is considered a primary disease when isolated, nonsyndromic and without concomitant involvement of vascular components explaining the enlarged digit<sup>(4)</sup>, and it may be secondary to neurofibromatosis, hemangiomatosis, arteriovenous malformations, congenital lymphedema or Klippel-Trenaunay-Weber syndrome<sup>(2,4,5,6)</sup>. The reported

Work performed at the Hospital das Clínicas de Goiânia, Universidade Federal de Goiás, Goiânia, GO, Brasil.

**Correspondence:** Felipe Cunha Pessôa. SQSW 105 Bloco F, Apto. 522, Brasília, DF, Brazil – CEP: 70670-426. E-mail: felipecunhapessoa@gmail.com

**Conflicts of interest:** none. **Source of Funding:** own.

**Date Received:** March 20, 2018. **Date Accepted:** July 22, 2018. **Online:** August 31, 2018.



incidence of macroductyly is 1 in 18,000 live births, with a slight predominance in males<sup>(2,4)</sup> and a higher prevalence in the fingers<sup>(2)</sup>. It is classified as static or progressive, with the latter being the most common type<sup>(1,5,7,8)</sup>; the static type accompanies the growth of the other digits after birth, whereas in the progressive type, disproportionate growth of the digit persists<sup>(5,6)</sup>. The etiology of macroductyly is obscure<sup>(7)</sup>; however, due to excessive adipose tissue proliferation on microscopic analysis<sup>(1,2)</sup>, it is postulated that its genesis is related to lipomatous degeneration<sup>(1,2,8)</sup>. The aim of the treatment of primary macroductyly in the foot is to obtain feet capable of adapting to footwear, allowing walking, and with near normal-looking toes. For this purpose, surgical treatment<sup>(2,4,5,6,7)</sup> is required, ranging from resection of the redundant tissue, tenodesis, epiphysiodesis and bone shortening to amputation when necessary<sup>(8)</sup>. The present study reports a series of three cases of primary macroductyly of the foot treated in our service, which underwent primary surgical treatment with amputation of the central rays or forefoot, and correlates the results with the literature.

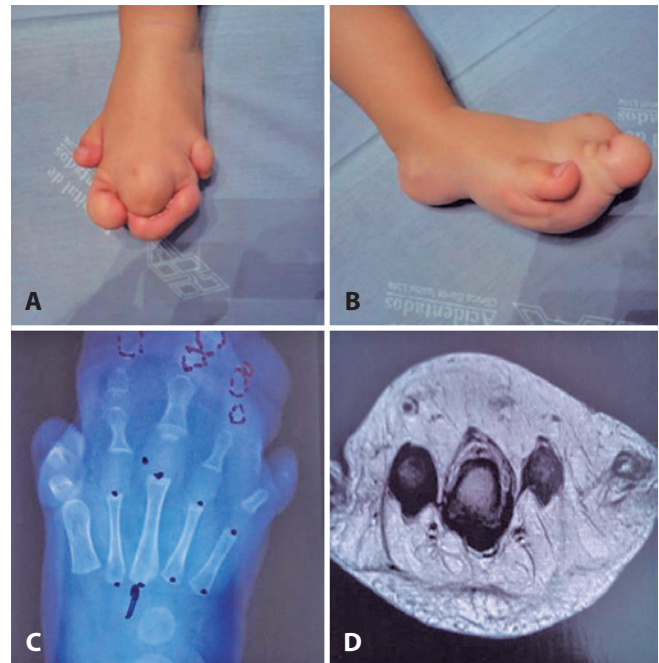
## CASE REPORTS

The study was approved by the Ethics Committee and registered in the Brazil Platform (Plataforma Brasil) under CAAE number 65289917.6.0000.5078.

During the analysis period, three patients with foot deformities were included in the study, with one patient (31 years old) complaining of pain related to central metatarsalgia associated with a plantar ulcer in the forefoot. The ratio of male to female patients was 2:1. All patients underwent surgical treatment, with an indication for ray amputation or forefoot amputation at the level of the Lisfranc joint due to the involvement of the 2nd, 3rd and 4th metatarsals. There was only one case of a late complication, in which the formation of a plantar hypertrophic scar occurred, culminating in a new surgical procedure for resection of the scar, with good progression. The mean postoperative follow-up time was 24 months, with flat, painless feet and a decrease in forefoot width obtained. All cases had satisfactory clinical outcomes.

### Case 1

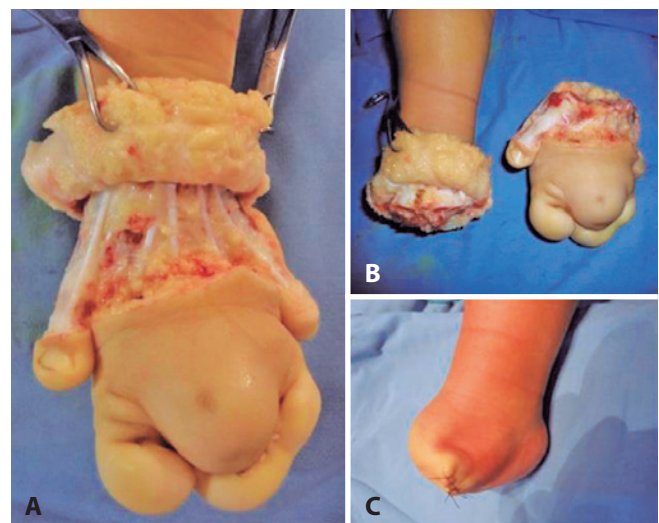
A 10-month-old patient who was not yet walking was brought in by the parents with complaints of deformity in the feet and no associated pain complaints (Figure 1). The patient presented macroductyly of the 2nd, 3rd and 4th rays.



**Figure 1.** A and B. 10-month-old patient with macroductyly of the central rays. C. X-ray of the foot affected by macroductyly of the 2nd, 3rd and 4th central metatarsals. D. Preoperative nuclear resonance image evidencing the hypertrophy of soft and bony tissues.

**Source:** Author's personal archive.

The patient underwent surgical amputation of the forefoot at the level of the Lisfranc joint due to the involvement of the three central rays (Figure 2).



**Figure 2.** A and B. Intraoperative aspect of amputation of the forefoot affected by macroductyly. C. Final aspect of amputation surgery of the forefoot.

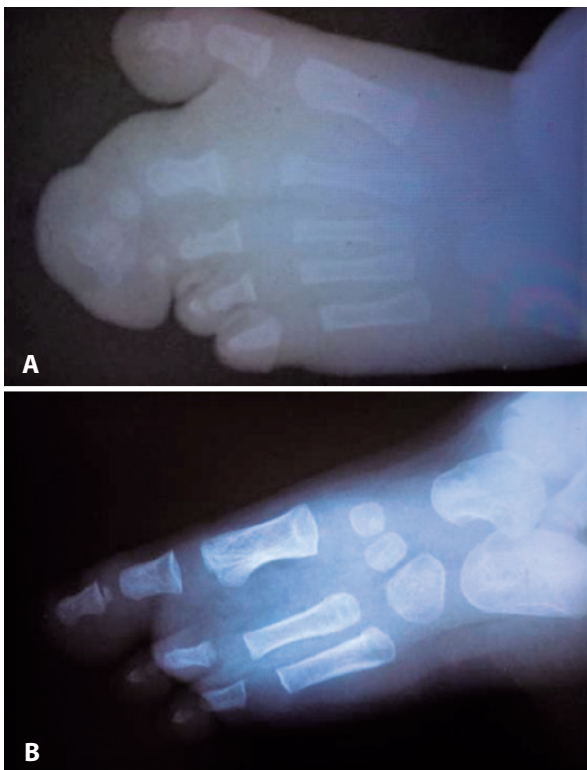
**Source:** Author's personal archive.

The patient progressed without pain complaints and with good adjustment to footwear after 2 years of clinical follow-up.

### Case 2

The patient was brought in by the parents at 4 months of age with esthetic complaints in the right foot, without pain complaints. The patient presented macroductyly of the 2nd and 3rd rays (Figure 3A).

The patient underwent surgical resection of both affected rays, with postoperative radiography showing a significant reduction in forefoot enlargement (Figure 3B).



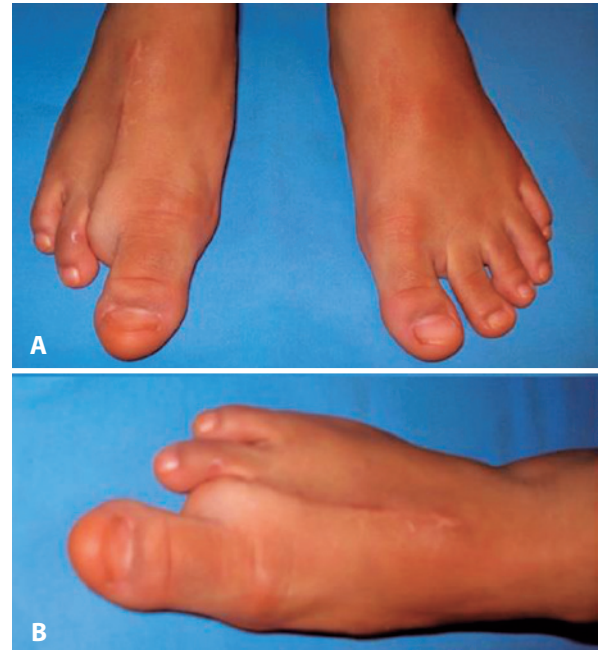
**Figure 3.** A. Preoperative radiography of macroductyly of the 2nd and 3rd rays. B. Postoperative radiography of amputation of the 2nd and 3rd rays.

**Source:** Author's personal archive.

After 9 years of follow-up, the patient maintained good adjustment to footwear, without pain complaints (Figure 4)

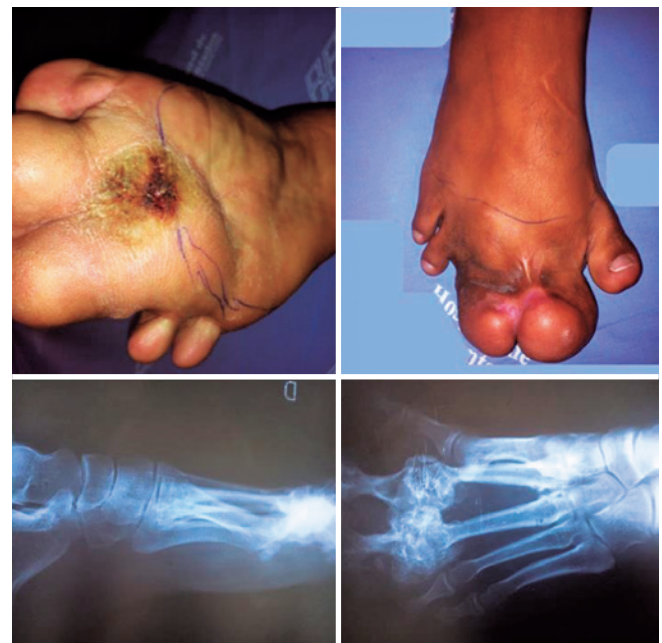### Case 3

A 31-year-old patient came to our service due to central metatarsalgia, a plantar ulcer and forefoot deformity, characterized by gigantism of the central rays (Figure 5).



**Figure 4.** Patient after 9 years of follow-up for amputation of the 2nd and 3rd rays.

**Source:** Author's personal archive.

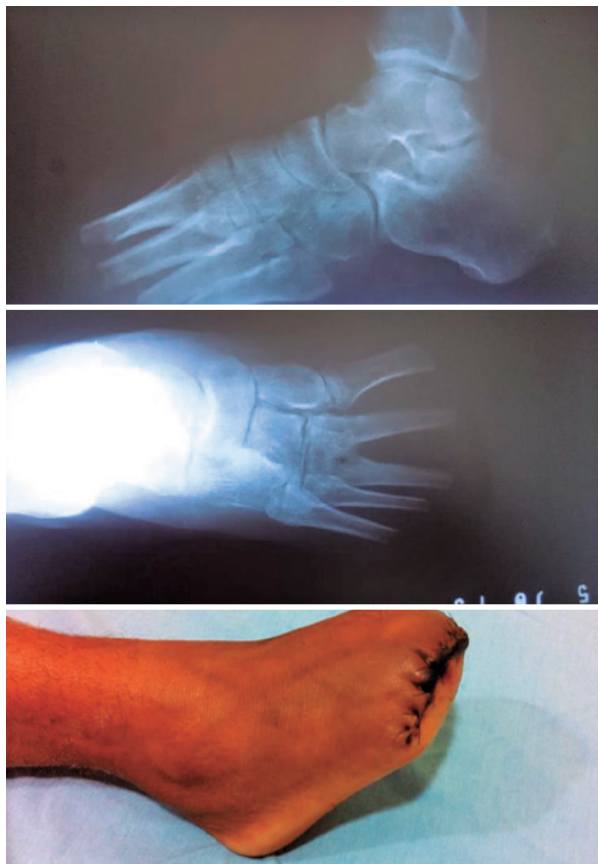

**Figure 5.** A 31-year-old patient with macroductyly of the 2nd and 3rd rays with a plantar ulcer.

**Source:** Author's personal archive.

In this case, due to the involvement of the soft tissues and central rays, transmetatarsal amputation of the forefoot was chosen (Figure 6).





**Figure 6.** A 31-year-old patient subjected to amputation of the forefoot for central ray macroductyly.

**Source:** Author's personal archive.

There was a complete regression of the pain complaints and load release on the 14th postoperative day, with good healing, gait and adjustment to footwear.

## DISCUSSION

Enlargement or increased volume of a single digit may occur by hypertrophy of any of the tissues that compose it, either by hemangioma, lipoma or soft tissue tumor<sup>(2)</sup>. However, macroductyly is characterized by increased volume in all tissues simultaneously<sup>(1-5)</sup>. It may involve the hands or feet, with macroductyly of the fingers<sup>(2,5)</sup> being more frequent; only macroductyly of the feet was included in this series of cases.

Macroductyly can be defined as primary or secondary. In this case series, only patients with the primary disease were included, with all cases in which patients had other abnormalities, which requires different treatment, being excluded.

There are several treatment modalities for macroductyly in the literature, the main choice being surgical treatment, including epiphysiodesis, bone shortening, redundant tissue debridement and amputation<sup>(2-7)</sup>. When the first ray is affected, which is a rare event, debridement or "thinning" of the digit as opposed to amputation is preferable, given the potential for change in gait biomechanics, a situation not contemplated in this study. When other rays are affected, surgical treatments that do not include amputation generate unsatisfactory results in most cases; there are reports of overgrowth after surgery, recurrence and the inability to reduce the forefoot width with debridement alone<sup>(4-6)</sup>. In agreement with the current literature, we opted for ray amputation or forefoot amputation when the central rays were affected, and we obtained satisfactory clinical outcomes in these cases: flat, painless feet, adaptable to footwear and with a satisfactory gait<sup>(2-6)</sup>.

The ideal time for the indication of surgical treatment varies according to the degree of disease involvement. More advanced degrees of macroductyly should be addressed after determining the disease type (primary or secondary) and extension, and treatment should be delayed as little as possible, since there will be greater difficulty in reducing the width of the forefoot after maturation of the tarsometatarsal joints<sup>(3)</sup>. In our series, the surgical approach was indicated after determination of the extent of macroductyly involvement and the type of growth. The age disparity among the patients was due to a delay in the search for a specialized service for treatment by the older patient.

In the surgical amputation of the rays or the forefoot in macroductyly, one must pay attention to the formation of a hypertrophic scar in the surgical wound, especially in the plantar region, which can lead to difficulty walking. In primary macroductyly, ischemic events that compromise the healing of the amputation stump in cases of forefoot amputation are infrequent; however, delaying walking until attaining adequate healing is suggested. In central ray amputations, there is difficulty reducing the width of the forefoot when more than two rays are simultaneously affected in patients of a more advanced age. In our series, one case of central ray amputation (case 2) was successful without a forefoot amputation due to the early treatment indication (4 months of age) and preservation of the first ray. In this case, there was no need for temporary bone stabilization for maintenance of the intermetatarsal space during the postoperative follow-up, as we opted to suture the joint capsule of the contiguous metatarsophalangeal joints. In cases where the patient is older, provisional bone stabilization may be required before walking is allowed. Special attention should be paid to cases of late macro-

dactyly, in which complications are more frequent. In this study, the older patient presented a plantar ulcer before the forefoot amputation and complaints of central metatarsalgia. Walking should be allowed as early as possible after the skin heals.

## CONCLUSION

Primary macroductyly is a challenging disease to treat, but when addressed early, treatment can present favorable outcomes in the long term, reaching the goal of flat and painless feet.

**Authors' contributions:** Each author contributed individually and significantly to the development of this article: FCP \*(<https://orcid.org/0000-0002-5094-8997>) conceived and planned the activities that led to the study, wrote the article and interpreted the study results; ENC \*(<https://orcid.org/0000-0002-6836-3110>) conceived and planned the activities that led to the study and approved the final version; JSM \*(<https://orcid.org/0000-0003-4742-1905>) conceived and planned activities that led to the study, participated in the review process and approved the final version. \*ORCID (Open Researcher and Contributor ID).

## REFERENCES

1. Ho CA, Herring JA, Ezaki M. Long-term follow-up of progressive macrodystrophia lipomatosa. A report of two cases. *J Bone Joint Surg Am.* 2007;89(5):1097-102.
2. Syed A, Sherwani R, Azam Q, Haque F, Akhter K. Congenital macroductyly: a clinical study. *Acta Orthop Belg.* 2005;71(4):399-404.
3. Chang CH, Kumar SJ, Riddle EC, Glutting J. Macroductyly of the Foot. *J Bone Joint Surg Am.* 2002;84(7):1189-94.
4. Kim J, Park JW, Hong SW, Jeong JY, Gong HS, Baek GH. Ray amputation for the treatment of foot macroductyly in children. *Bone Joint J.* 2015;97(10):1364-9.
5. Bulut M, Karakurt L, Belhan O, Serbest S. Ray amputation for the treatment of macroductyly in the foot: report of three cases. *Acta Orthop Traumatol Turc.* 2011;45(6):458-62.
6. Hop MJ, van der Biezen JJ. Ray reduction of the foot in the treatment of macroductyly and review of the literature. *J Foot Ankle Surg.* 2011;50(4):434-8.
7. Adorno Filho ET, Almeida KG, Costa GR, Oliveira GSM. Macroductilia: estudo retrospectivo de quatro casos. *Rev Bras Cir Plást.* 2013;28(3):92.
8. Watt AJ, Chung KC. Macroductyly lipomatosa: a reconstructive approach to gigantism of the foot. *J Foot Ankle Surg.* 2004;43(1):51-5.