

Evaluation of the prognosis of type IV Charcot arthropathy treatment

Avaliação do prognóstico de tratamento da artropatia de Charcot do tipo IV

Marcelo Marcucci Chakkour¹, Noé De Marchi Neto¹, Ricardo Cardenuto Ferreira¹

1. Santa Casa de Misericórdia de São Paulo, São Paulo, SP, Brazil.

ABSTRACT

Objective: To evaluate the prognosis of specialized orthopedic treatment to obtain a functional foot and ankle in diabetic patients with neglected Charcot arthropathy (NCA).

Methods: Sixty-five patients with NCA were treated in the period between 2000 and 2017, according to a systematized protocol adopted at our institution. Six patients (9%) were lost to follow-up, and the remaining 59 patients had a total of 63 affected extremities (four patients were bilaterally affected). The mean follow-up time was 72 months (range 12 to 132 months), and the mean age was 54 years (range 30 to 80 years). We considered the results satisfactory when the patient was able to walk independently, fully supporting the foot on the ground. We considered the results unsatisfactory when the affected extremity presented a frank instability and was deformed to the point that it was not possible to accommodate it in a stabilizing orthosis or support it during gait or when amputation was necessary.

Results: We obtained an unsatisfactory result in 31 of the 59 patients (53%). Only 31 of the 63 extremities (49%) were considered functional after treatment.

Conclusion: The prognosis of NCA treatment using the systematized treatment protocol is poor. Only half of the treated extremities were capable of plantar support and independent gait.

Level of Evidence IV; Prognostic Studies; Case Series.

Keywords: Arthropathy, neurogenic; Diabetic foot; Prognosis.

RESUMO

Objetivo: Avaliar o prognóstico do tratamento ortopédico especializado em possibilitar a obtenção de um pé e tornozelo funcionais nos pacientes diabéticos que apresentam artropatia de Charcot negligenciada (ACN).

Métodos: Sessenta e cinco pacientes com ACN foram tratados no período compreendido entre 2000 e 2017, segundo protocolo sistematizado adotado na nossa instituição. Seis pacientes (9%) perderam o seguimento, restando 59, totalizando 63 extremidades afetadas (quatro apresentavam afecção bilateral). O tempo médio de seguimento foi de 72 meses (variação de 12 a 132) e a média de idade de 54 anos (variação de 30 a 80). Consideramos o resultado como satisfatório quando o paciente foi capaz de caminhar de maneira independente, apoiando completamente o pé no solo; e insatisfatório quando a extremidade afetada apresentou instabilidade franca e encontrou-se deformada, a ponto de não ser possível acomodá-la numa órtese estabilizadora nem apoiá-la durante a marcha, ou ainda quando foi necessário realizar a amputação.

Resultados: Obtivemos resultado insatisfatório em 31 dos 59 pacientes (53%). Apenas 31 das 63 extremidades (49%) foram consideradas funcionais após o tratamento.

Conclusão: O prognóstico do tratamento da ACN utilizando o protocolo sistematizado de tratamento é reservado. Somente metade das extremidades tratadas foi capaz de realizar apoio plantígrado e marcha independente.

Nível de Evidência IV; Estudos Prognósticos; Série de Casos.

Descritores: Artropatia neurogênica; Pé diabético; Fatores prognósticos.

Work performed at the Santa Casa de Misericórdia de São Paulo, São Paulo, SP, Brazil.

Correspondence: Marcelo Marcucci Chakkour. Rua Pascal, 605 apto 43 – Campo Belo – CEP: 04616-002 – São Paulo, SP, Brazil.
E-mail: marcelo.chakkour@gmail.com

Conflicts of interest: none. **Source of funding:** none.

Date received: November 09, 2018. **Date accepted:** December 10, 2018. **Online:** December 30, 2018.



How to cite this article: Chakkour MM, Marchi Neto N, Ferreira RC. Evaluation of the prognosis of type IV Charcot arthropathy treatment. *Sci J Foot Ankle.* 2018;12(4):316-23.

INTRODUCTION

Described by Jean-Martin-Charcot in 1868, Charcot arthropathy (CA) was originally associated with tertiary syphilis⁽¹⁻¹⁰⁾. The use of antibiotics in medical practice (early 20th century) drastically reduced the incidence of syphilis in our country and, as a consequence, CA became rarer⁽⁸⁾. Furthermore, the development of synthetic insulin provided better control of the disease and increased survival of diabetic patients, creating conditions for the development of late complications of this disease^(5,6,8,11). Currently, there is a worldwide obesity epidemic that is closely related to the alarming increase in the incidence of *diabetes mellitus* and, consequently, an increase in CA^(5,11-14).

CA is a relevant concern for orthopedists because it involves a destructive osteoarticular process that frequently affects the foot and ankle of patients with peripheral neuropathy due to the prolonged course of the disease^(1,2,4,5,7-9,11,15-20). The loss of the protective sensitivity of the feet causes traumatic lesions that are not recognized by the patient to induce bone fragmentation, osteoarticular derangement and destruction, which often result in gross deformities and marked instability, making it impossible to support body weight and perform an independent gait⁽¹⁹⁾. Consequently, formation of bony prominences may occur that predispose the patient to pressure ulcers located in the protruding areas of the insensitive feet^(2,5,8,11,15,17). The patient's insistence on trying to bear weight on the unstable and deformed extremity leads to recurrent pressure ulcers typically related to a sequence of events that results in the amputation of the extremity^(5,19-25).

Because early diagnosis of the destructive events caused by CA is neglected, osteoarticular derangement tends to extend to the other regions of the foot and ankle, which further compromises the deformation of the original extremity architecture and results in a poor prognosis with regard to functional viability^(5,26).

The primary objective of this study is to evaluate the prognosis of treatment of neglected Charcot arthropathy (NCA) (type IV)^(5,19) in patients with diabetes to obtain a functional extremity capable of performing support functions during gait and allowing independent locomotion.

As a secondary objective, we evaluated the impact of ulcer presence on the prognosis of the treatment of NCA patients. Our hypothesis is that the clinical-functional prognosis of this type of condition is poor.

METHODS

This study was approved by the Research Ethics Committee with registration in the Brazil Platform under CAAE number: 82949318.4.0000.5479.

Over a period of 17 years, from September 2000 to September 2017, 65 patients (69 extremities) with NCA were treated and followed up on an outpatient basis.

The treatment instituted in our case series strictly followed the orientation of the systematized protocol developed in our institution.

Systematized treatment protocol

Generally, we used non-invasive treatment with a total-contact cast (TCC) and recommended using crutches and avoiding supporting the body weight on the affected extremity during gait until regression of edema. Patients affected bilaterally were advised to use a wheelchair. Cast immobilization was changed every two weeks during the first six weeks and then monthly until clinical and radiographic evolution from phase I fragmentation to the beginning of phase II consolidation occurred⁽²⁷⁾. Then, we replaced the TCC with a rigid polypropylene molded orthosis of the Ankle Foot Orthosis (AFO) type, which was used until the progression to phase III sequela⁽²⁷⁾. In cases in which consolidation was achieved and the extremity achieved complete stability without significant deformation, the orthosis was replaced with protective extra deep footwear with custom-made insoles for the insensitive feet. In cases where complete stabilization of the foot and ankle could not be achieved, we recommended continued use of the molded AFO orthosis.

When non-invasive treatment failed to obtain a suitably stable extremity that was capable of supporting the body weight or sufficiently aligned to permit the use of a rigid AFO type orthosis, surgical treatment was indicated.

Other possible indications for surgical treatment included 1) presence of recurrent ulcers caused by a localized bony prominence located on the area of support and 2) active infection from a previously contaminated ulcer.

The surgical modalities employed were as follows: 1) simple exostectomy (Figure 1), used to remove bony protrusions located in pressure areas, which was indicated when the foot and/or ankle were stable after the end of bone consolidation; 2) reconstructive bone surgery (Figure 2), used to realign seriously deformed and/or unstable bones and joints, indicated for extremities in which circulation is adequate and without active infection; 3) de-

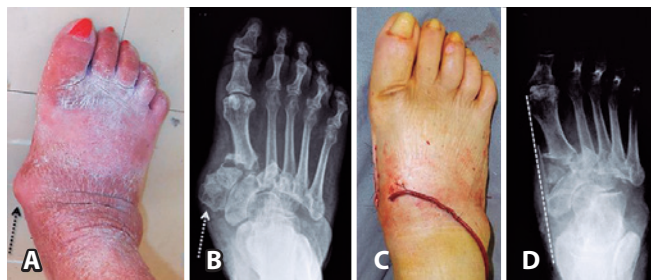

Figure 1. Localized prominence in the medial aspect of the right foot (dark dotted arrow) (1A) corresponding to the bony prominence of the medial and intermedial wedge, which is identified in the radiographic image of the foot (light dotted arrow) (1B). After surgical resection, improvement is visible in the foot contour (1C), with corresponding elimination of the bony prominence (clear dashed line) (1D).

Source: Author's Personal Archive.

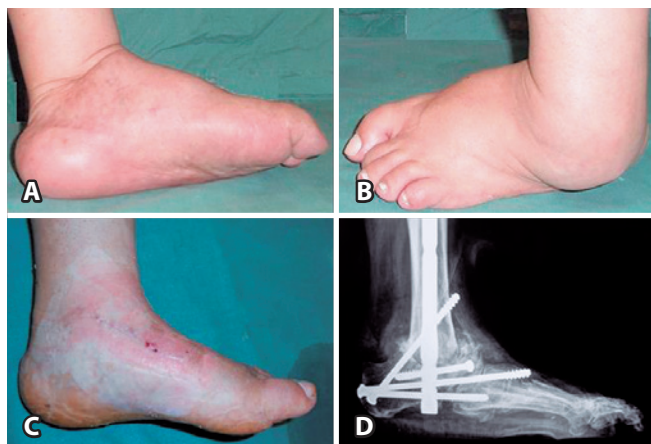

Figure 2. Photographic image of the medial (2A) and lateral (2B) projections of the left foot and ankle showing varus angular deformity. Panarthrodesis was used for correction of foot alignment with respect to the axis of the leg (2C) after reconstructive surgery (2D).

Source: Author's Personal Archive.

bridement with removal of infected bones (Figure 3) was indicated in the presence of contaminated deep ulcers, with bone exposure and osteomyelitis, in addition to abscess formation; and 4) amputation of the extremity (Figure 4) was indicated mainly for uncontrolled infections, extremities with severely impaired circulation or in the presence of extremely severe deformities in which great difficulty was anticipated in performing osteoarticular reconstruction.

All patients were followed up at the neuropathic foot clinic. Data regarding the clinical evolution, physical examination and complementary tests were collected and stored at the service. In cases where a surgical approach was necessary, patients were operated on by the foot and ankle surgery team of our institution.

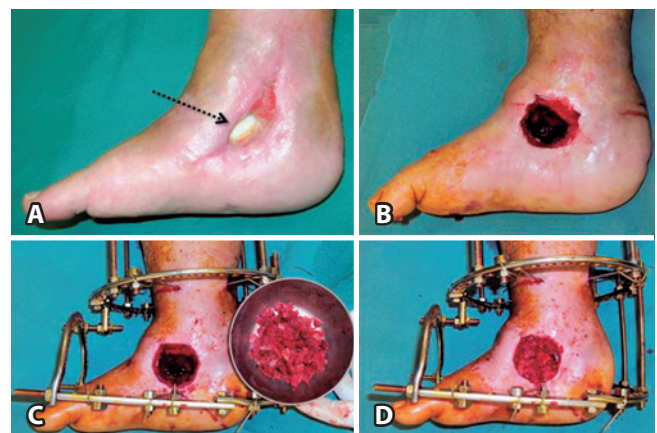


Figure 3. Photographic image showing the presence of antibiotic cement at the bottom of a previously infected ulcer (dotted arrow) (3A). After removing the cement and curetting the lesion (3B), an external circular fixator (3C) was placed, and the remnant bone cavity was filled with a cancellous bone graft from the patient's own iliac crest (3D).

Source: Author's Personal Archive.

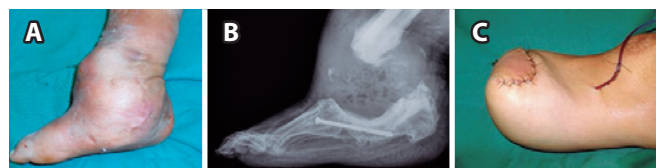

Figure 4. Medial view of a severely deformed and bulging right foot and ankle (4A). A lateral radiographic image of the foot and ankle (4B) shows extensive bone resorption after an unsuccessful surgical reconstruction attempt. The patient underwent transtibial amputation (4C).

Source: Author's Personal Archive.

To analyze the efficacy of the treatment, we considered the data present in the electronic medical record until September 2017. Thus, the ability of the patient to use the affected extremity to perform full support of the body weight during independent gait at the time of the last assessment was used as an evaluation criterion. Three possible outcomes were considered: 1) good outcome: preservation of a plantigrade foot, sufficiently aligned to fit inside extra deep footwear and sufficiently stable to perform complete body weight support during gait; 2) acceptable outcome: preservation of a plantigrade but unstable foot that was sufficiently aligned to allow fitting inside a rigid AFO type orthosis and capable of performing independent walking and supporting the body weight on the affected extremity during gait; and 3) poor outcome: extremity amputation or preservation of a non-plantigrade, unstable foot with severe deformity that prevented the use of a rigid polypropylene molded orthosis (AFO), making the patient unable to support body weight on the affected extremity during gait.

In the final analysis of the outcomes of this study, we considered extremities that obtained a good or acceptable outcome as satisfactory, while extremities for which the final result was classified as poor were considered unsatisfactory.

As a subject of this study, we evaluated the medical records of patients enrolled in our database with a clinical and radiographic diagnosis of type IV CA according to the Brodsky classification, which was modified by Trepmann^(5,28). Of 864 diabetic patients enrolled in our service, 252 patients (29%) were diagnosed with CA. Of these, 65 patients (26%) were diagnosed with NCA (type IV). Four patients (6%) were affected bilaterally, totaling 69 affected extremities. At the time of the clinical evaluation, which was based on the information contained in our database, sufficient information for analysis was found for 59 patients (91%), totaling 63 treated extremities (9% loss). The mean age of the 29 male and 30 female patients was 55 years (24 to 77 years).

According to our treatment protocol, 28 of 63 extremities (44% of the total) were treated exclusively in a non-invasive manner. This group included 26 patients, two of whom were bilaterally affected. The mean age of these patients was 56 years (30 to 74 years). At the time of conservative treatment, 7 of 28 extremities (25%) already had pressure ulcers located under bony prominences (60% in the malleolar region). None of the ulcers were infected, and all were treated with local debridement, dressing and TCC use.

Additionally, 35 of 53 extremities (56%) required a surgical procedure throughout the treatment. This group included 33 patients, two of whom were bilaterally affected, and only one of the extremities underwent surgery. The mean age of these patients was 53 years (24 to 77 years). At the start of treatment, 23 of 35 extremities (66%) already had pressure ulcers located under bony prominences (61% in the malleolar region). In 13 of 35 extremities, the ulcers were infected, and the patient had to be hospitalized for extensive debridement and intravenous systemic antibiotic therapy. In 2 of 13 extremities with infected ulcers, circular external fixation was used, while in 3 patients, primary transtibial amputation was performed.

In the group of patients who underwent surgery, the modalities of surgery were as follows: simple exostectomy of bony prominences in 3 of 35 extremities (9%); reconstructive bone surgery to salvage the limb in 25 of 35 extremities (71%); and transtibial amputation in 7 of 35 extremities (20%). Among the 25 extremities submitted to the salvage attempt using multiple osteotomies and modeling arthrodesis, the two different modalities used for bone fixation were 1) internal fixation with retrograde intramedullary nails (indicated for patients with instability of the hindfoot and ankle) or plates and screws (indicated for patients with mid-foot, hindfoot and/or ankle instability) in 18 of 25 extremities (72%) (Figure 5) or 2) circular external fixation (indicated for patients with poor bone quality for fixation, osteopenia) in 7 of 25 extremities (28%). Among the 7 amputated extremities, 3 amputations were performed primarily due to uncontrolled severe infection from pressure ulcers, while the other 4 were the result of unsuccessful reconstructive surgery.

Statistical analysis

For statistical analysis, we used IBM SPSS® (Statistical Package for Social Sciences) software version 22.0, using the Chi-square test and Fisher's exact test. These tests were applied for evaluation of satisfactory or unsatisfactory outcomes in the presence or absence of ulcers and, separately, in the presence or absence of infected ulcers in the extremities of diabetic patients submitted to the NCA treatment protocol used in our study (Tables 1 and 2). We calculated the mean to describe variables such as age, sex and mean follow-up time and used percentage data to describe the outcomes.

RESULTS

At the time of the evaluation, after using our systematized treatment protocol, we obtained a satisfactory outco-

me for type IV NCA in 31 of the 63 extremities (49%), and an unsatisfactory outcome was observed in the other 32 extremities (51%). Among the outcomes considered satisfactory, 21 of 31 of the extremities (68%) obtained a good result, while the outcome of 10 extremities (32%) was considered acceptable.

Considering the treatment modality employed, the outcome was considered unsatisfactory in 14 of the 28 extremities (50%) submitted to conservative treatment and in 18 of the 35 extremities (51%) submitted to surgical treat-

ment. Regarding a satisfactory outcome, in the conservatively treated group, 8 of 14 extremities (57%) were classified as presenting a good outcome, and 6 (43%) were classified as presenting an acceptable outcome. In the group treated surgically, the outcome was classified as good in 13 of 17 extremities (76%), and the outcome was considered acceptable in 4 extremities (24%) (Table 3).

Among the cases in which ulcers were present (30 of 63 extremities), the final treatment outcome was considered unsatisfactory in 22 affected extremities (73%) (p=0.001). Among the 30 ulcers, 13 were infected, and hospitalization was needed for surgical treatment, the final treatment outcome was considered unsatisfactory in 12 affected extremities (92%) (Fisher's exact test 0.073).

Among the surgical modalities required during the treatment of type IV NCA, exostectomy was performed for resection of bone prominences in 3 of 35 extremities and showed a satisfactory outcome in all patients. However, reconstructive bone surgeries, performed in 25 of 35 extremities, showed satisfactory outcomes in only 14 of 25 extremities, which corresponded to 56% of the total. Of these, the final outcome was classified as good

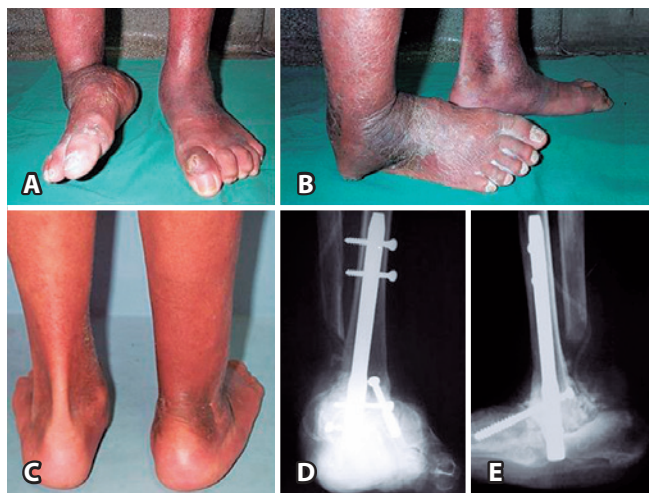

Figure 5. Photographs showing marked varus deformity and severe instability of the ankle, resulting in the lateral border of the right foot being used for support (5A) and pressure ulcer formation under the fibular malleolus (5B). Rear view of the lower limbs (5C) showing adequate alignment after tibiototalcalcaneal arthrodesis. Radiographic images show the correction obtained (5D and 5E).

Source: Author's Personal Archive.

Table 1. Analysis of the impact of the presence or absence of infected ulcers on the prognosis of patients with NCA, demonstrating a poor prognosis in patients with infected ulcers.

		Outcome		Total
		Unsatisfactory	Satisfactory	
Ulcer	No	10	23	33
		30.3%	69.7%	100.0%
	Yes	22	8	30
		73.3%	26.7%	100.0%
Total		32	31	63
		50.8%	49.2%	100.0%
			Value	p
Fisher's exact test			11.642(b)	0.001

Source: Prepared by the author based on the research results.

Table 2. Analysis of the impact of the presence or absence of an ulcer on the prognosis of patients with NCA, demonstrating a poor prognosis in patients with ulcers.

		Outcome		Total
		Unsatisfactory	Satisfactory	
Infected ulcer	No	11	7	18
		61.10%	38.90%	100.00%
	Yes	11	1	12
		91.70%	8.30%	100.00%
Total		22	8	30
		73.30%	26.70%	100.00%
		Value	p	Exact Sig
Chi-square test		3.438(b)	0.064	
Fisher's exact test				0.073

Source: Prepared by the author based on the results of the research.

Table 3. Final outcome of the treatment of patients with NCA submitted to the systematized treatment protocol.

Type of treatment	Number of extremities	Satisfactory outcome	Unsatisfactory outcome
Conservative	28	14 (50%)	14 (50%)
Surgical	35	17 (49%)	18 (51%)
Total	63	31 (49%)	32 (51%)

Source: Prepared by the author based on the research results.

in 11 operated extremities (79%) and acceptable in 3 extremities (21%).

When the type of bone fixation used in 25 of the 35 extremities that required reconstructive salvage surgery was considered, internal fixation, used in 18 of the 25 operated extremities, showed a satisfactory outcome in 12 extremities (67%), while external fixation, required in 7 of the 25 extremities, showed a satisfactory outcome in only 2 evaluated extremities (29%).

At the time of the evaluation, 5 of the 59 patients had died. Three of these patients had undergone transtibial amputation, of whom one was submitted to primary amputation due to uncontrollable infection, and two underwent amputation due to complications during the course of an unsuccessful surgical attempt of osteoarticular reconstruction. Regarding the other two patients who died, both had undergone reconstructive bone surgery, and the outcome was acceptable in one patient and unsatisfactory in the other patient.

DISCUSSION

CA more frequently affects midfoot joints (type 1 and type 2)^(4,9). The first option for treatment of these lesions involves a TCC, and the main goal is to achieve bone consolidation with minimal structural deformities^(4,10,26,29,30). The literature supports conservative treatment of these lesions, with several studies showing satisfactory clinical and functional results^(5,11,15,31). However, both the delay in identifying CA and the delay in initiating treatment often contribute to increase the area of osteoarticular destruction and cause serious deformities. In these situations, extension of the midfoot osteoarticular lesions to the other joints of the hindfoot and ankle significantly aggravates the clinical picture that typically characterizes NCA (type IV)⁽⁵⁾. The literature shows that studies performed in other countries present a low frequency of NCA patients⁽⁵⁾ due to the early diagnosis of CA; however, no study to date has specifically addressed the prognosis of type IV CA.

The expectation of the final treatment outcome for the studied patients with NCA was low. Trepman was the first to describe the variation of type IV of CA and identified a poor prognosis of these lesions compared to the other anatomical variations⁽⁵⁾. The frequency of unsatisfactory outcomes obtained in our case series was extremely high and involved 32 of the 63 extremities (51%), which is consistent with the expected outcome. An unsatisfactory outcome occurred in 50% of the cases receiving conservative

treatment and in 51% of the surgical cases, which suggests a poor prognosis for both treatments.

In our case series, ulcers were present in 30 of the 63 extremities at the beginning of NCA treatment. Of these 30 extremities, the treatment outcome was unsatisfactory in 22 (73%), which clearly indicates that ulcers are associated with a poor prognosis. Additionally, 13 of the 30 ulcers presented active infection at the beginning of treatment, and hospitalization and surgical intervention were required for these patients. The outcome of this treatment was considered unsatisfactory in 12 of the 13 extremities (92%), and transtibial amputation was required for 8 extremities (62%). Thus, consistent with studies that show the worst prognosis for CA patients with ulcers⁽⁵⁾, our data suggest that NCA associated with an infected ulcer determines a poor prognosis.

The large number of patients with clinical symptoms suggesting NCA who arrive at our service without a confirmed diagnosis is noteworthy. This demonstrates the precariousness of the public health system regarding the decreased capacity of general practitioners and orthopedists involved in the primary care of diabetic patients to identify CA. Alarming data contained in a Brazilian Institute of Geography and Statistics (IBGE) study published in 2013⁽³²⁾ report that only 3% of diabetic patients seeking care in basic health units have their feet examined by the physician. Lack of information on the part of diabetic patients also increases the likelihood of worsening of the condition.

We recommend that public health organizations prioritize 1) the improvement of the basic education of diabetic patients; 2) the creation of programs for the prevention and treatment of this disease and its complications; 3) the provision of adequate infrastructure with preparation of health units to perform early treatment of injuries that affect the feet of diabetic patients with CA; and 4) the creation of centers specialized in the adequate treatment of CA, aiming to reduce its complications and sequelae. Thus, effective targeting of available resources can avoid the waste associated with long-term, highly complex and costly treatments that often have poor outcomes^(9,25).

The limitations of this study were the fact that it was retrospective (case series) and that the follow-up time limited the analysis of the outcomes of patients who started conservative treatment and obtained an unsatisfactory outcome because these patients were awaiting surgery or underwent the surgical procedure after the study period.

CONCLUSION

The prognosis of NCA treatment using a systematized treatment protocol is poor. Only half of the treated extre-

mities were able to perform plantigrade support and an independent gait.

The presence of a pressure ulcer is associated with a worse prognosis for patients with NCA.

Authors' contributions: MMC *(<https://orcid.org/0000-0001-8133-7892>) wrote the article, interpreted the results of the study and participated in the review process; NMN *(<https://orcid.org/0000-0001-7696-2220>) wrote the article, participated in the review process and approved the final version; RCF *(<https://orcid.org/0000-0002-9886-5082>) conceived and planned the activities that led to the study, wrote the article, participated in the review process and approved the final version. *ORCID (Open Researcher and Contributor ID).

REFERENCES

1. Strotman PK, Reif TJ, Pinzur MS. Charcot arthropathy of the foot and ankle. *Foot Ankle Int.* 2016;37(11):1255-1263.
2. Varma AK. Charcot neuroarthropathy of the foot and ankle: a review *J Foot Ankle Surg.* 2013;52(6):740-9.
3. Sammarco VJ. Superconstructs in the treatment of Charcot foot deformity: plantar plating, locked plating, axial screw fixation. *Foot Ankle Clin.* 2009;14(3):393-407.
4. Souza LJ. Charcot arthropathy and immobilization in a weight-bearing total contact cast. *J Bone Joint Surg Am.* 2008;90(4):754-9.
5. Trepman E, Nihal A, Pinzur MS. Current topics review: Charcot neuroarthropathy of the foot and ankle. *Foot Ankle Int.* 2005;26(1):46-63.
6. Bariteau JT, Tenenbaum S, Rabinovich A, Brodsky JW. Charcot arthropathy of the foot and ankle in patients with idiopathic neuropathy. *Foot Ankle Int.* 2014; 35(10):996-1001.
7. Bevan WPC, Tomlinson MPW. Radiographic measures as a predictor of ulcer formation in diabetic Charcot midfoot. *Foot Ankle Int.* 2008; 29(6):568-573.
8. Stéfani KC, Mercadante MT. Princípios do tratamento da neuroartropatia de Charcot no pé e no tornozelo. *Rev Bras Ortop.* 2003;38(9):497-506.
9. Frykberg RG, Belczyk R. Epidemiology of the Charcot foot. *Clin Podiatr Med Surg.* 2008;25(1):17-28.
10. Osterhoff G, Böni T, Berli M. Recurrence of acute Charcot neuropathic osteoarthropathy after conservative treatment. *Foot Ankle Int.* 2013; 34(3):359-364.
11. Ferreira RC, Gonçalves DH, Fonseca Filho JM, Costa MT, Santin RAL. Midfoot Charcot arthropathy in diabetic patients: complication of an epidemic disease. *Rev Bras Ortop.* 2012; 47(5):616-25.
12. Ferreira RC, Silva APS, Costa MT, Frizzo GG, Santin RAL. Aspectos epidemiológicos das lesões no pé e tornozelo do paciente diabético. *Acta Ortop Bras.* 2010;18(3):135-141.
13. Armstrong DG, Peters EJ. Charcot's arthropathy of the foot. *J Am Podiatr Med Assoc.* 2002; 92(7):390-4.
14. International Diabetes Federation. IDF Diabetes Atlas [online]. 7thed. Brussels, Belgium: IDF; 2015. Available at: <https://www.idf.org/e-library/epidemiology-research/diabetes-atlas/13-diabetes-atlas-seventh-edition.html>.
15. Wukich DK, Sung W. Charcot arthropathy of the foot and ankle: modern concepts and management review. *J Diabetes Complications.* 2009; 23(6):409-26.
16. Pinzur MS. Current concepts review: Charcot athropathy of the foot and ankle. *Foot Ankle Int.* 2007; 28(8):952-959.
17. Lowery NJ, Woods JB, Armstrong DG, Wukich DK. Surgical management of Charcot neuroarthropathy of the foot and ankle: a systematic review. *Foot Ankle Int.* 2012;33(2):113-21.
18. Stark C, Murray T, Gooday C, Nunney I, Hutchinson R, Loveday D, Dhatariya K. 5 year retrospective follow-up of new cases of Charcot neuroarthropathy - A single center experience. *Foot Ankle Surg.* 2016;22(3):176-180.
19. Pinzur MS, Schiff AP. Deformity and clinical outcomes following operative correction of Charcot foot: a new classification with implication for treatment. *Foot Ankle Int.* 2018;39(3):265-70.
20. Kliushin NM, Sudnitsyn AS, Subramanyam KN, George J. Management of neurologic deformity of the ankle and foot with concurrent osteomyelitis with the Ilizarov method. *Foot Ankle Int.* 2018;39(2):226-35.
21. Hastings MK, Johnson JE, Strube MJ, Hildebolt CF, Bohnert KL, Prior FW, Sinacore DR. Progression of foot deformity in Charcot neuropathic osteoarthropathy. *J Bone Joint Surg Am.* 2013;95(13):1206-13.
22. Wukich DK, Sadoskas D, Vaudreuil NJ, Fourman M. Comparison of diabetic Charcot patients with and without foot wounds. *Foot Ankle Int.* 2017;38(2):140-148.
23. Schon LC, Easley ME, Cohen I, Lam PWC, Bedekas A, Anderson CD. The acquired midtarsus deformity classification system – interobserver reliability and intraobserver reproducibility. *Foot Ankle Int.* 2002;23(1):30-6.
24. Richman J, Cota A, Weinfeld S. Intramedullary nailing and external rig fixation for tibiototalcaneal arthrodesis in charcot arthropathy. *Foot Ankle Int.* 2017;38(2):149-152.

25. Kroin E, Schiff A, Pinzur MS, Davis ES, Chaharbakhshi E, DiSilvio Jr FA. Functional impairment of patients undergoing surgical correction for Charcot foot arthropathy. *Foot Ankle Int.* 2017;38(7):705-9.
26. Höpfner S, Krolak C, Kessler S, Tiling R, Brinkbaümer K, Hahn K, et al. Preoperative imaging of Charcot neuroarthropathy in diabetic patients: comparison of ring PET, hybrid PET, and magnetic resonance imaging. *Foot Ankle Int.* 2004;25(12):890-5.
27. Eichenholtz SN. Charcot joints. Springfield, IL, USA: Charles C. Thomas; 1966.
28. Brodsky JW. The diabetic foot. In: Coughlin MJ, Mann RA. *Surgery of the Foot and Ankle.* Philadelphia: Mosby; 1999. p. 895-969.
29. Pinzur M. Surgical versus accommodative treatment for charcot arthropaty of the midfoot. *Foot Ankle Int.* 2004;25(8):545-9.
30. Sammarco GJ, Conti SF. Surgical treatment of neuroarthropathic foot deformity. *Foot Ankle Int.* 1998; 19(2):102-9.
31. Hyer CF, Pinzur MS, Ellington JK, Davis WH, Jones CP. Charcot arthropathy: operative and nonoperative management. *Foot Ankle Spec.* 2014;7(4):286-90.
32. IBGE – Instituto Brasileiro de Geografia e Estatística. Percepção do estado de saúde, estilos de vida e doenças crônicas: Brasil, Grandes Regiões e Unidades da Federação [internet]. Brasília: IBGE; 2013. Available at: <http://ibge.gov.br/home/estatistica/populacao/pns/2013/>