

Arthroscopic treatment of subtalar joint injuries

Tratamento artroscópico das lesões da articulação subtalar

Felipe Ayusso Correa Sossa¹, Inacio Diogo Asaumi¹, Alfonso Apostólico Netto¹, Rafael da Rocha Macedo¹, Fabio Luiz Kiyam¹, Donato Lo Turco¹

1. Hospital IFOR, São Bernardo do Campo, SP, Brazil.

ABSTRACT

Objective: To evaluate the results of arthroscopic treatment of various subtalar joint pathologies.

Methods: Retrospective study of patients undergoing arthroscopy of the subtalar joint from 2005 to 2013, totaling 10 cases over a mean follow-up of 27.1 months, in which the American Orthopedic Foot and Ankle Society (AOFAS) scale and pain visual analogue scale (VAS) scores before and after surgery were compared.

Results: The preoperative AOFAS scores ranged from 35 to 74, with a mean score of 50.1 points, and the postoperative scores ranged from 82 to 100 points, with a mean score of 90.8 points. When comparing the scores, we observed an average gain of 40.1 points. The mean VAS score for the initial pain assessment was 6.5 points, and the mean postoperative score was 1.4 points.

Conclusion: Arthroscopic treatment of the reported subtalar pathologies led to encouraging results, with a significant reduction of pain and improvement of functional status.

Level of Evidence IV; Therapeutic Studies; Case Series.

Keywords: Arthroscopy; Subtalar joint; Treatment outcome.

RESUMO

Objetivo: Avaliar os resultados do tratamento artroscópico de diversas patologias da articulação subtalar.

Métodos: Foi realizado um estudo retrospectivo dos pacientes submetidos à artroscopia da articulação subtalar no período de 2005 a 2013, somando um total de 10 casos, durante um seguimento médio de 27,1 meses, em que foi comparado os resultados dos escores AOFAS e escala EVA de dor no pré e pós-operatório.

Resultados: Os valores pré-operatórios do escore AOFAS oscilaram entre 35 e 74, com média de 50,1 pontos, e os valores pós-operatórios encontrados foram de 82 a 100 pontos, ficando com a média de 90,8 pontos. Ao realizar-se a comparação entre os valores notamos um ganho médio de 40,1 pontos. O valor médio da EVA para avaliação da dor colhido inicialmente foi de 6,5 pontos, e o valor médio pós-operatório foi de 1,4 pontos.

Conclusão: O tratamento artroscópico das patologias subtalares relatadas levou a resultados encorajadores, com redução significativa da dor e melhora da qualidade funcional dos pacientes.

Nível de Evidência IV; Estudos Terapêuticos; Série de Casos.

Descritores: Artroscopia; Articulação subtalar; Resultado do tratamento.

How to cite this article: Sossa FAC, Asaumi ID, Netto AA, Macedo RR, Kiyam FL, Lo Turco D. Arthroscopic treatment of subtalar joint injuries. Sci J Foot Ankle. 2019;13(1):22-7.

Work performed at the Hospital IFOR, São Bernardo do Campo, São Paulo, Brazil.

Correspondence: Felipe Ayusso Corrêa Sossa. Av. Armando Italo Setti, 659, Baeta Neves, CEP: 09760-280, São Bernardo do Campo, SP, Brazil
E-mail: felipesossa@hotmail.com

Conflicts of interest: none. **Source of funding:** none.

Date received: December 21, 2018. **Date accepted:** March 15, 2019. **Online:** March 31, 2019.



Copyright © 2019 SciJFootAnkle

INTRODUCTION

Today, the etiology of isolated anterolateral hindfoot pain, a characteristic of sinus tarsi syndrome (STS), is a source of discussion and remains undefined. The anatomical and biomechanical complexity of the subtalar joint complicates the accurate diagnosis and definition of the ideal treatment of its diseases. With the evolution of minimally invasive surgical procedures, arthroscopy has proven to be a useful diagnostic and therapeutic tool⁽¹⁻⁷⁾.

STS was first described in 1958 by O'Connor and characterized as pain on palpation of the sinus tarsi – which is eliminated with local anesthesia – and some sensation of instability. Since then, several hypotheses on the etiology of STS have been proposed, such as scarring and excessive stress on the ligaments, pinching of herniations of the sinus tarsi membrane, synovial hyperplasia, ligamentous scar tissue, hemosiderin deposits, and posttraumatic fibrotic changes in the tissues surrounding the vessels⁽¹⁻⁴⁾. A history of previous trauma appears to be the most common predisposing factor of STS, representing 70% of the cases, especially inversion sprains. Other inflammatory conditions, such as ankylosing spondylitis, rheumatoid arthritis, gout, ganglion cysts, and deformities such as pes cavus and pes planus account for 30% of the remaining cases^(3,5).

In STS, there are no pathognomonic clinical signs or complaints or imaging tests capable of revealing a reliable diagnosis. Arthroscopy has been a useful tool for the diagnosis and treatment of subtalar diseases when conservative treatment fails⁽⁵⁾.

Since 1985, when subtalar arthroscopy was performed for the first time in a cadaveric study by Parisien and Vangsness⁽⁶⁾, several studies have demonstrated the inherent advantages of minimally invasive procedures and the good results of arthroscopic intervention in the management of subtalar conditions⁽⁷⁻¹¹⁾.

The possible therapeutic indications for subtalar arthroscopy are debridement of chondromalacia, excision of free bodies and osteophytes, synovectomy, excision of symptomatic os trigonum, drilling of osteochondral lesions of the talus, evaluation of chondral lesions after talar and calcaneal fracture, removal of adhesions and intra-articular plicae, possible subtalar arthrodesis, diagnostic and therapeutic assessment of chronic hindfoot pain, instabilities, injury of the talocalcaneal ligaments, and removal of fibrocartilaginous coalitions⁽¹⁰⁾.

The objective of this study was to evaluate the result of arthroscopic treatment of the various subtalar joint injuries.

METHODS

This study was approved by the Research Ethics Committee with registration in the Brazil Platform under CAAE number: 05044818.3.0000.5625.

A retrospective study was conducted including all patients undergoing subtalar arthroscopy performed by the senior author from 2005 to 2013. The total sample consisted of 10 patients (10 feet, 5 left and 5 right), including 5 women and 5 men with ages ranging between 18 and 41 years (mean of 30.7 years).

The American Orthopedic Foot and Ankle Society (AOFAS) Ankle-Hindfoot Scale) and pain visual analogue scale (VAS) scores were collected before the procedures, and follow-up ranged from 9 to 43 months (mean of 27.1 months). The scores were collected again six months after surgery and compared with the preoperative scores. The nonparametric Wilcoxon test was used for statistical analysis of the data collected, and the software SPSS 17.0 for Windows was used for the calculations.

All patients undergoing arthroscopic treatment of their respective subtalar pathologies, such as impingement, instability, intra-articular free bodies, pseudarthrosis of the lateral process of the talus, and osteochondral injury of the posterior facet, were included in the study (Table 1). Patients with advanced subtalar arthritis and significant angular deformities were excluded from the study.

Surgical indication was based on the combination of physical examination and imaging tests. The common clinical presentation was hindfoot pain, and the change found on physical examination was pain on palpation of the sinus tarsi, with or without limited subtalar joint range of motion. The important test was xylocaine infiltration without vasoconstriction in the sinus tarsi region (Figure 1).

Table 1. Overall results and follow-up.

Name	AOFAS Pre	VAS Pre	AOFAS Post	VAS Post	Follow-up (months)
A.S.C.	51	7.4	86	3.5	35
A.M.	45	8.3	83	4.2	25
F.R.A.F.	40	7.3	85	0	17
D.B.	67	4.3	98	0.5	09
D.F.	35	7.2	82	3.4	19
O.S.	74	5.7	100	0	18
K.M.Y.I.	48	5.1	88	0.4	18
C.A.B.	56	6.5	100	0	56
A.C.S.	40	7.1	86	1.5	43
E.G.O.S	51	6.1	100	0.5	31

Source: Prepared by the author based on the results of the research.

After 10 minutes, a reassessment was performed, and the mandatory condition for the indication of the endoscopic procedure was improvement of pain and/or joint mobility. Weight-bearing radiographs of the foot and ankle and magnetic resonance imaging (MRI) were performed in all patients. In cases of talocalcaneal impingement, due to ligament remnants, MRI showed nonspecific findings that were formerly diagnosed as STS.

All patients initially underwent nonsurgical treatment for at least six months, including immobilization, analgesics, nonsteroidal anti-inflammatory drugs, and physical therapy, without success.

Surgical technique

The patient was positioned on the operating table in a semilateral decubitus position under regional anesthesia, and a pneumatic cuff was placed on the thigh root and inflated to 280 mmHg with the knee flexed. After asepsis and placement of surgical drapes, a surgical pen was used to mark the reference points, such as venous structures near the portals, the sural nerve, and branches of the superficial peroneal nerve, peroneal tendon, and lateral malleolus. Use of noninvasive traction devices was not typically necessary.

For subtalar arthroscopy, three portals were made – anterolateral, accessory anterolateral, and posterolateral – with the latter being rarely used, typically when a more significant inflow was necessary and/or the most posterior region of the posterior facet of the subtalar joint was approached. The anterolateral portal was made approximately 1cm distal and 1.5 to 2cm anterior to the tip of the lateral malleo-

lus, and the accessory anterolateral portal was made approximately 2cm medial and 1cm distal to the anterolateral portal. Next, 10ml of saline solution was infused into the subtalar joint through the anterolateral portal, and after a small transverse incision with a no. 11 scalpel blade and blunt dissection of the subcutaneous layer, the optic was introduced. The posterolateral portal was made 0.5 to 1cm proximal to the lateral malleolus and lateral to the calcaneal tendon, always with caution to avoid injuring the sural nerve. Figure 2 shows the anterolateral, accessory anterolateral, posterolateral, and posterolateral accessory portals, and Figure 3 shows the optic through the anterolateral portal. The surgical instruments required to perform the procedure consisted of an arthroscope with a 2.7-mm/30° optic, a 2.9-mm shaver blade, curettes, and probe and grasper for small joints^(6,7,9).

After the procedure was performed, the skin was sutured, bandaged, and wrapped with a compression bandage. The stitches were removed at two to three weeks, and protected weight bearing with or without orthosis was introduced gradually starting on the second week. The patient was referred to rehabilitation with stretching exercises of the posterior chain of the lower limbs, gain in inversion-eversion range of motion, and strengthening of the intrinsic musculature of the foot.

RESULTS

The evaluated group comprised 10 patients, including 5 men and 5 women. Ages ranged from 18 to 41 years (mean 30.7), and the mean follow-up was 27.1 months, ranging from 9 to 43 months.

All patients were evaluated using the AOFAS scale and pain VAS, and the scores before and after surgery were compared. Table 1 shows the scores evaluated in the pre- and postoperative periods, as well as the follow-up time.

Regarding the etiology of the patients, most were due to previous traumatic events, and arthroscopy aided in confirming the diagnosis. The procedures performed in each patient in our sample were as follows: two patients had fracture sequelae, one with pseudoarthrosis of the lateral process of the talus and another with onset of arthrosis after calcaneal fracture. In one patient, the pseudoarthrotic fragment was resected, and in another, the intra-articular debris was removed. Four patients had isolated impingement injuries of the talocalcaneal ligaments, in which synovectomy and intra-articular shaving of ligament remnants were performed (Figures 4 and 5). In the three patients with associated instability of the lateral

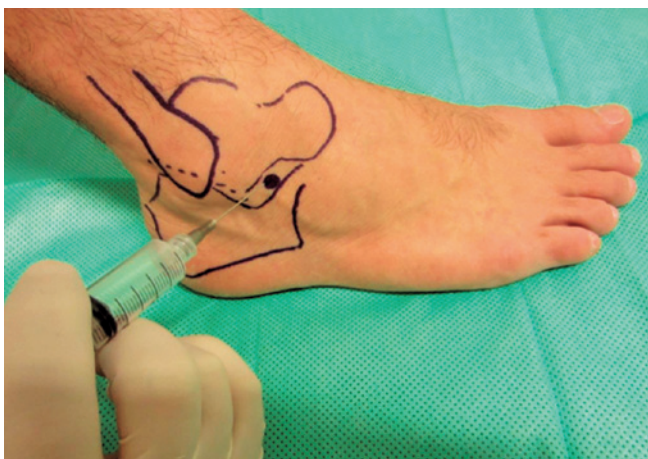


Figure 1. Infiltration of the sinus tarsi.
Source: Author's personal archive.

ligamentous complex of the ankle, ankle arthroscopy and Brostrom-Gould ligament repair were also performed. One patient had an osteochondral injury of the posterior facet; free bodies were removed, and curettage and drilling of the osteochondral injury were performed.

The preoperative AOFAS scores ranged from 35 to 74, with a mean of 50.1 points, and the postoperative scores ranged from 82 to 100 points, with a mean of 90.8 points (Figure 6). When comparing the scores, we observed a significant ($p=0.005$) average increase in the AOFAS score of 40.1 points, representing good clinical and functional improvement.

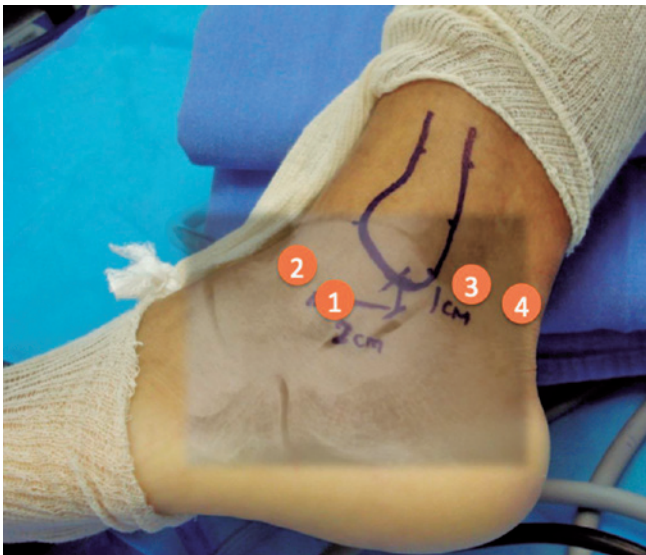


Figure 2. Arthroscopic portals.
Source: Author's personal archive.

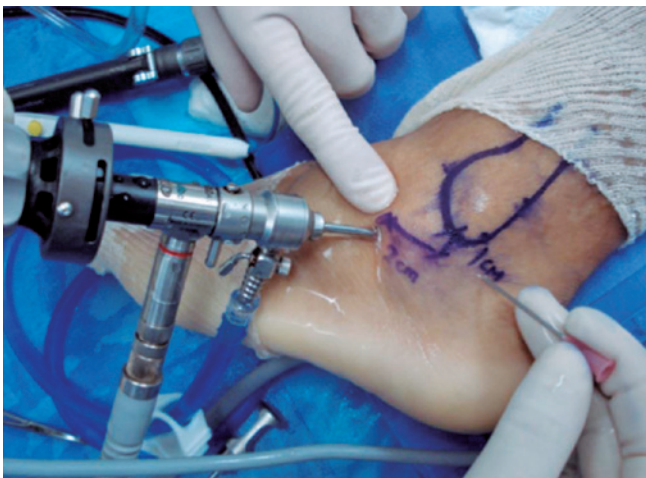

Figure 3. Optic in the anterolateral portal.
Source: Author's personal archive.

The mean VAS score for the assessment of pain initially collected was 6.5 points, and the mean postoperative score was 1.4 points, reflecting an overall significant ($p=0.005$) improvement in pain (Figure 6).

There were no reports of postoperative complications in the group studied.

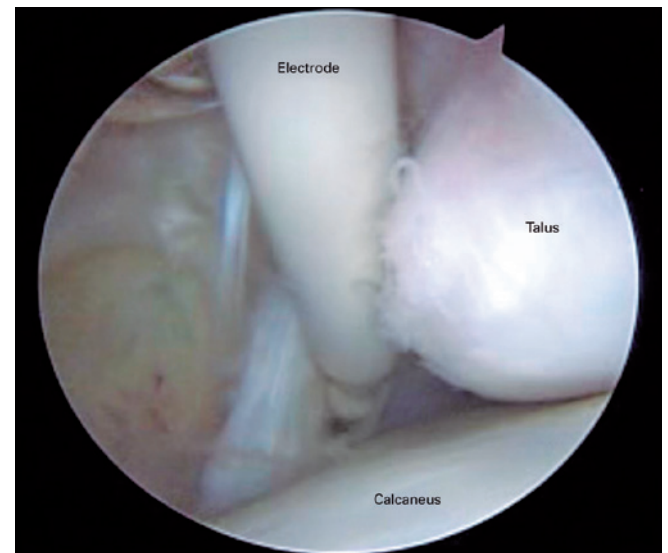


Figure 4. Cleaning of intra-articular debris using the ablation electrode.
Source: Author's personal archive.

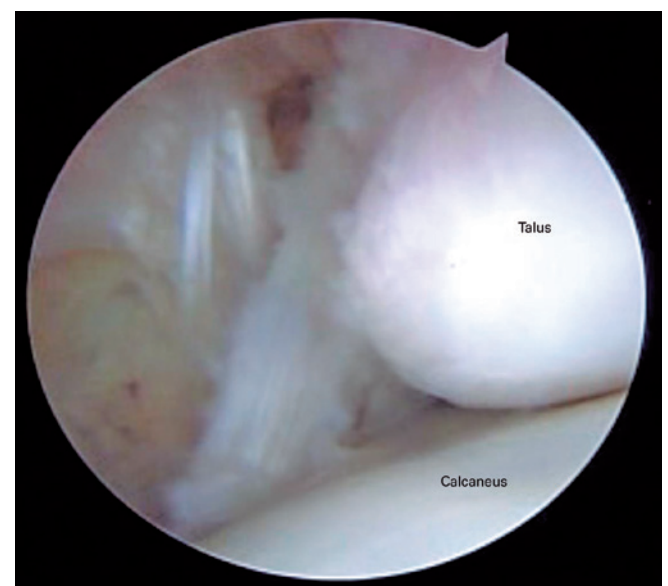

Figure 5. Intra-articular view of the subtalar joint after debridement.
Source: Author's personal archive.

DISCUSSION

In our study, we obtained good and excellent results (mean of 90.8 points) according to the AOFAS scale, and a decrease from 6.5 to 1.4 points on the VAS for pain. The improvements in both scales were statistically significant, and no complications were observed. Despite the small sample size, our results are similar to those found in the literature. Frey et al.⁽⁵⁾ obtained 94% good and excellent results after arthroscopic treatment of various subtalar pathologies in 49 feet. In addition, after surgery, all 14 patients initially diagnosed with STS had their diagnoses altered. In 10 feet, posterior interosseous ligament injuries were found; 2 had arthrofibrosis; and the remaining 2 had degenerative changes of the subtalar joint. This shows the importance of subtalar arthroscopy as a tool for the investigation and treatment of subtalar pathologies when conservative treatment fails and

arthrodesis is not indicated⁽⁵⁾. These results are also corroborated by Williams and Ferkel⁽⁷⁾, who performed arthroscopy of the ankle and subtalar joint in 50 patients with chronic ligament injuries resulting from inversion sprain who had pain in both the ankle and subtalar joint. In this group of patients, a rate of 86% good and excellent results was reported. However, in 21 feet, the subtalar arthroscopy was normal, and the symptoms were related to the anterolateral impact on the ankle, i.e., sinus tarsi pain of patients with inversion sprains may be related to the ankle⁽⁷⁾.

Subtalar arthroscopy appears to be a procedure with low morbidity and few complications, and in our sample of 10 patients, there were no complications; this result was reflected in studies with larger samples. Frey et al.⁽⁵⁾, with 49 cases, and Williams and Ferkel⁽⁷⁾, with 50 cases, also reported no complications. The most frequently observed complications were neuritis of the superficial fibular nerve branches and superficial infection, and no major complications were reported^(5,9,12).

In addition to the retrospective nature of our study, one evident limitation is the small size and heterogeneity of the sample, characterized by a variability of diagnoses, which made it difficult to evaluate the results of the treatment of each pathology alone. However, several authors reported similar results even with heterogeneous samples. In 2009, Ahn et al.⁽⁹⁾ obtained 97% good and excellent results in a much larger and nonhomogeneous sample with 115 feet subjected to subtalar arthroscopy.

The open surgical technique for the treatment of STS involves the excision of adipose tissue, disinsertion of the short extensor digitorum, and transection of the ligaments of the tarsal canal and sinus. Although the exact morbidity caused by the wide resection of these tissues is unknown, the results are satisfactory, as shown by Kuwada⁽⁴⁾ in a study in which 100% of patients reported complete improvement in pain, with no postoperative complications.

Studies comparing the quality of arthroscopic and open techniques are necessary in the future. Despite the lack of high-level evidence, subtalar arthroscopy follows the principles of minimally invasive surgeries, with less trauma to the soft tissue envelope and better intra-articular visualization, enabling appropriate diagnosis and treatment. The disadvantages of this technique continue to be the high cost compared to open surgery and the steep learning curve.

CONCLUSION

Arthroscopic treatment of the reported subtalar pathologies led to encouraging results, with significant improvement in pain and functional status.

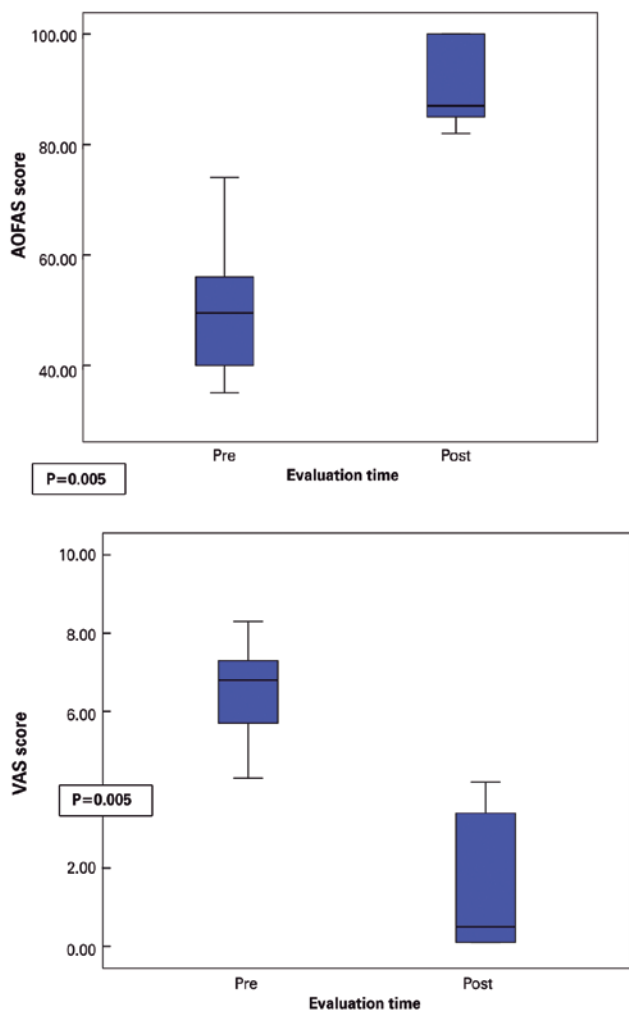


Figure 6. (A) AOFAS scores; (B) VAS scores. **Source:** Prepared by the authors based on the results of the study.

Authors' contributions: Each author contributed individually and significantly to the development of this article: FACS *(<https://orcid.org/0000-0001-6410-3867>) participated in the bibliographic review process, wrote the article, interpreted the results of the study, participated in the review process and approved the final version; IDA *(<https://orcid.org/0000-0002-4074-0412>) conceived and planned the activities that led to the study, participated in the review process and approved the final version; AAN *(<https://orcid.org/0000-0001-9237-869X>) wrote the article, participated in the bibliographic review process and approved the final version; FLK *(<https://orcid.org/0000-0002-6450-9768>) participated in the bibliographic review process, interpreted the results of the study and approved the final version; RRM *(<https://orcid.org/0000-0002-2563-2085>) interpreted the results of the study, participated in the review process and approved the final version; DLT *(<https://orcid.org/0000-0001-9024-2553>) participated in the bibliographic review process, wrote the article and approved the final version. *ORCID (Open Researcher and Contributor ID).

REFERENCES

1. O'Connor D. Sinus tarsi syndrome: a clinical entity. *J Bone Joint Surg Am.* 1958; 40:720-9.
2. Brown JE. The sinus tarsi syndrome. *Clin Orthop Relat Res.*1960;(18): 231-3.
3. Taillard W, Meyer JM, Garcia J, Blanc Y. The sinus tarsi syndrome. *Int Orthop.* 1981;5(2):117-30.
4. Kuwada GT. Long-term retrospective analysis of the treatment of sinus tarsi syndrome. *J Foot Ankle Surg.* 1994; 33(1):28-9.
5. Frey C, Feder KS, DiGiovanni C. Arthroscopic evaluation of the subtalar joint: does sinus tarsi syndrome exist? *Foot Ankle Int.* 1999; 20(3):185-1.
6. Parisien JS, Vangsness T. Arthroscopy of the subtalar joint: an experimental approach. *Arthroscopy.* 1985;1(1):53-7.
7. Williams MM, Ferkel RD. Subtalar arthroscopy: indications, techniques, and results. *Arthroscopy.* 1998;14(4):373-81.
8. Oloff LM, Schulhofer SD, Bocko AP. Subtalar joint arthroscopy for sinus tarsi syndrome: a review of 29 cases. *J Foot Ankle Surg.* 2001; 40(3):152.
9. Ahn JH, Lee SK, Kim KJ, Kim Yi, Choy WS. Subtalar arthroscopic procedures for the treatment of subtalar pathologic conditions: 115 consecutive cases. *Orthopaedics.* 2009;32(12):891-6.
10. Lui TH, Tong SC. Subtalar arthroscopy: when, why and how. *World J Orthop.* 2015; 6(1):56-61.
11. Goldberger MI, Conti SF. Clinical outcome after subtalar arthroscopy. *Foot Ankle Int.* 1998;19(7):462-5.
12. Lee KB, Bai LB, Song EK, Jung ST, Kong IK. Subtalar arthroscopy for sinus tarsi syndrome: arthroscopic findings and clinical outcomes of 33 consecutive cases. *Arthroscopy.* 2008;24(10):1130-4.